

# Spontaneous Rupture of a Coronary Artery Aneurysm

## A Case Report and Review of the Literature

Huseyin GUNDUZ,<sup>1</sup> MD, Ramazan AKDEMIR,<sup>2</sup> MD, Emrah BINAK,<sup>3</sup> MD,  
Ali TAMER,<sup>4</sup> MD, *and* Cihangir UYAN,<sup>1</sup> MD

### SUMMARY

Coronary artery aneurysm (CAA) is a rare disorder, characterized by abnormal dilatation of a localized portion or diffuse segments of the coronary artery. CAA may cause angina, myocardial infarction, sudden death due to thrombosis, embolisation, or rupture. In this report, a 63 year old Turkish male patient is presented who had an acute non-Q wave myocardial infarction due to spontaneous rupture of the left circumflex artery aneurysm. An extremely rare clinical presentation of rupture of a left circumflex CAA is discussed. (Jpn Heart J 2004; 45: 331-336)

**Key words:** Coronary artery aneurysm, Spontaneous rupture, Myocardial infarction

IN CAA, a relatively rare disease, most of the patients are asymptomatic. Treatment of these patients depends on the severity of symptoms and anatomical conditions.<sup>1)</sup> Only a few studies on rupture of CAA have been reported.<sup>2-5)</sup> This case report describes a patient with a circumflex artery aneurysm complicated by rupture. This extremely rare presentation and therapeutic options of CAA are discussed.

### CASE REPORT

A 63 year-old previously healthy Turkish male was admitted to an emergency department with the symptoms of typical chest pain, vomiting, and cold sweating that had lasted for two hours. His medical history was not significant except for a family history of sudden death in the 4<sup>th</sup> and 5<sup>th</sup> decades of life. He had no history of trauma, drug abuse, or any known immune system disorders. Physical examination revealed arterial blood pressure of 130/70 mmHg and his heart rate was 86 beats per minute on admission. There were no murmurs, friction

---

From the <sup>1</sup> Department of Cardiology, Izzet Baysal Medical Faculty, Abant Izzet Baysal University, Bolu, <sup>2</sup> Department of Cardiology, Duzce Medical Faculty, Abant Izzet Baysal University, Duzce, <sup>3</sup> Department of Cardiology, Maltepe University Medical Faculty, Istanbul, <sup>4</sup> Department of Internal Medicine, Izzet Baysal Medical Faculty, Abant Izzet Baysal University, Bolu, Turkey.

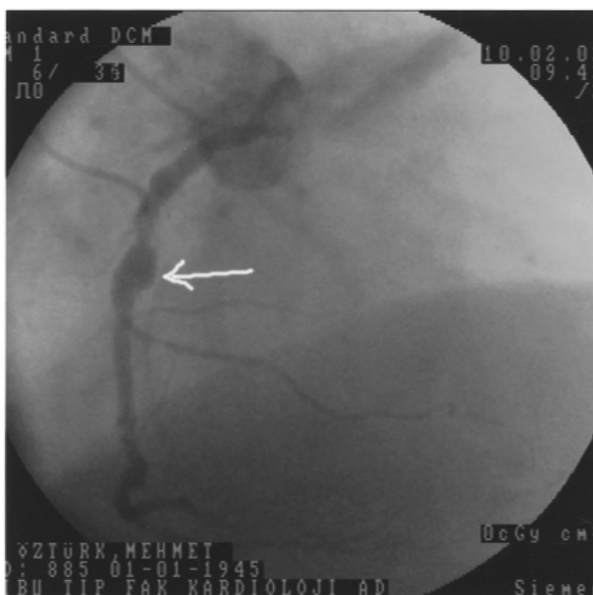
Address for correspondence: Huseyin Gunduz, MD, Department of Cardiology, Izzet Baysal Medical Faculty, Abant Izzet Baysal University, Bahcelievler Mahallesi, Eski Istanbul Cad. Karsu Apt. No: 11/1. 14070 Bolu, Turkey.

Received for publication July 15, 2003.

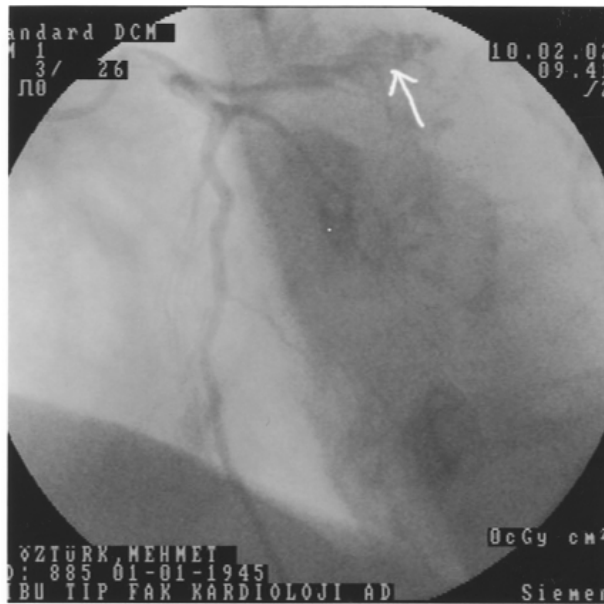
Revised and accepted September 25, 2003.

rub or gallop on cardiac examination. His ECG showed normal sinus rhythm and ST depressions in the anterolateral leads, suggesting ischemia. Chest X-rays and initial laboratory data were normal. Acute non-Q wave myocardial infarction was diagnosed after serial enzymatic evaluation and on-going chest pain. After initial stabilization of the patient with aspirin, heparin, nitrates, beta-blockers, and diazepam, he underwent cardiac catheterization and coronary angiography.

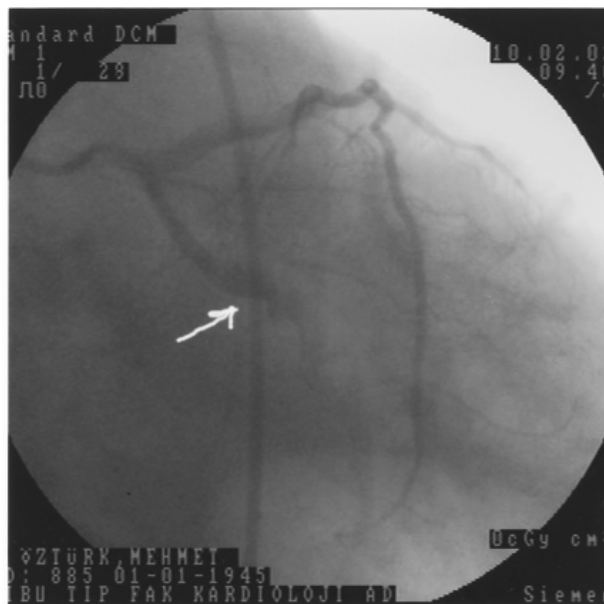
Left ventriculography demonstrated mild hypokinesia of the anterolateral and apical walls. Coronary angiography revealed a coronary aneurysm and stenosis at the midportion of the right coronary artery (Figure 1). There was retention of contrast agent in the mid portion of the left circumflex artery. In addition, the left circumflex artery was totally occluded at the mid-portion, possibly caused by spontaneous rupture of a coronary artery aneurysm (Figures 2 and 3). There was no distal flow. The patient was transferred back to the coronary care unit and aspirin and heparin were discontinued. Echocardiography did not reveal any pericardial effusion. The patient was discharged after ten days without any problems and he was asymptomatic for six months on beta-blocker, angiotensin converting enzyme inhibitor, aspirin, and lipid lowering therapy.



**Figure 1.** Coronary aneurysms at the midportion of the right coronary artery (RAO straight view).



**Figure 2.** Spontaneous rupture of left circumflex coronary artery aneurysm (LAO cranial view).



**Figure 3.** Total occlusion at midportion possibly caused by spontaneous rupture of left circumflex coronary artery aneurysm (RAO caudal view).

## DISCUSSION

Coronary artery aneurysm is defined as a coronary dilatation which exceeds the diameter of normal adjacent segments or the diameter of the patient's largest coronary vessel by 1.5 times. This is an uncommon disease which has been diagnosed with increasing frequency since the advent of coronary angiography.<sup>6)</sup> The incidence varies from 0.3% to 4.9% with male dominance and the right coronary artery is most frequently involved, followed by the circumflex and left anterior descending coronary arteries.<sup>7)</sup> Aneurysm may be single or multiple, saccular or fusiform.<sup>8)</sup>

Coronary angiography is the gold standard in the diagnosis of aneurysms providing information regarding the size, shape, location, and number of aneurysms. Also, large coronary artery aneurysms can be detected by noninvasive imaging modalities such as transesophageal echocardiography, contrast-enhanced computed tomography, and magnetic resonance imaging.<sup>9)</sup>

The most common etiology is atherosclerosis followed by Kawasaki's disease (mucocutaneous lymph node syndrome) and congenital aneurysms. Other possible causes of coronary aneurysms include trauma, angioplasty, atherectomy, laser procedures, arteritis (including syphilis), mycotic emboli, systemic lupus erythematosus, and dissection (spontaneous or secondary).<sup>6,10)</sup>

Patients can present with a wide range of symptoms from being asymptomatic to sudden death. Complications include ischemia, myocardial infarction, fistula formation, spontaneous rupture, calcification, and distal embolization as a result of thrombus formation within the aneurysm.<sup>11)</sup>

The pathophysiologic mechanisms that lead to development of these dilations have not yet been clarified. Sorrell, *et al* suggested there was an association between the chronic stimulation of endogenous nitric oxide, with consequent chronic stimulation of vascular relaxation, and the occurrence of ectatic areas in coronary arteries.<sup>12)</sup> Whichever is the responsible mechanism, it is certain that the dilated sections present in coronary arteries are not benign entities. Reports in the literature show that these areas, even without association of stenosis, are subject to spasms, thrombosis, and spontaneous dissection, and as such, are potential causes of acute myocardial infarction. In coronary angiography, flaws that occur in filling because of thrombus or inadequate flow of the contrast medium in the aneurysmatic region caused by dilution of the contrast with blood, may lead to poor visualization of the arterial lumen and causes difficulty in the angiographic interpretation of the gravity of associated coronary stenosis.<sup>13)</sup>

Rupture of a coronary artery aneurysm is extremely rare, excluding those caused by Kawasaki disease in children.<sup>14)</sup> Diagnosis is made postmortem in the majority of cases so the incidence of coronary artery aneurysm ruptures is

unknown. The most common cause is atherosclerotic coronary artery disease, which accounts for 50% to 90% of the cases.<sup>15)</sup> The pathogenesis involves destruction of the vessel media, thinning of the arterial wall, increased wall stress, and progressive dilatation of the segment of coronary artery.<sup>16)</sup>

A CAA can rupture into the pulmonary artery, right ventricle, and coronary sinus and cause an arteriovenous fistula, hematoma, or intramyocardial mass. If they rupture into the pericardial space, they can cause pericardial tamponade. Rupture of a CAA can also cause acute myocardial infarction (AMI) and sudden cardiac death.<sup>1-4,17)</sup>

The management of these patients is not well established. Treatment options include surgical ligation with coronary artery bypass surgery, stent implantation, or medical management. Medical therapy is indicated for the majority of patients and consists of antiaggregation and anticoagulation medication. Although surgery has been recommended to prevent complications, there are no available data comparing medical and surgical management. Coronary bypass grafting should be performed in coronary artery aneurysm patients only when indicated by the severity of stenosis, progressive angina despite medical therapy, or complications such as fistula formation and compression of cardiac chambers. The surgical procedures performed for patients with CAA are coronary artery bypass graft surgery, total aneurysmal resection, proximal ligation and distal ligation, aneurysmal thrombectomy, and aneurysmectomy.<sup>5,6,18-20)</sup>

Our case presented to our emergency room with typical chest pain. After the initial evaluation, he was diagnosed as a non-Q AMI and followed and treated in our coronary care unit. In the coronary arteriography, a CAA was identified at the right coronary artery and left circumflex artery. It was noted that the CAA in the left circumflex artery had ruptured and this spontaneous rupture was thought to be responsible for the AMI. In our case, there are several explanations for AMI development. A ruptured atheromatous plaque in CAA could result in thrombus formation leading to AMI; and this could trigger local dissection on the arterial wall eventually resulting in rupture. Another possibility is that a nonatherosclerotic aneurysm could have been ruptured and caused thrombus formation leading to AMI.

As a result, CAA and its rupture should be kept in mind as a rare etiology of AMI and treatment should be planned in light of complications and the presence and number of atherosclerotic lesions in other coronary arteries.

## REFERENCES

1. Merchan A, Lopez-Minguez JR, Alonso F, *et al.* Giant left main coronary aneurysm without associated coronary lesions. *Rev Esp Cardiol* 2002; 55: 308-11.
2. Koshika M, Goto S, Yamamoto K, Inoue H, Oguma F, Kasuya S. Surgical treatment of a ruptured saccular aneurysm associated with bilateral coronary arteries-pulmonary artery fistulas: a case report. *Kyobu Geka* 1999; 52: 924-7.
3. Berrizbeitia LD, Samuel LE. Ruptured right coronary artery aneurysm presenting as a myocardial mass. *Ann Thorac Surg* 2002; 73: 971-3.
4. Nitschke T, Sprengel U, Heuer H, Botsios S, Walterbusch G. Pericardial tamponade in rupture of a right coronary artery aneurysm. *Z Kardiol* 2002; 91: 187-90.
5. Yamaki F, Nakajima M, Hirayama T, Kume S. A case report of surgical treatment of ruptured coronary artery aneurysm. *Nippon Kyobu Geka Gakkai Zasshi* 1993; 41: 2229-33.
6. Syed M, Lesch M. Coronary artery aneurysm: a review. *Prog Cardiovasc Dis* 1997; 40: 77-84.
7. Hartnell GG, Parnell BM, Pridie RB. Coronary artery ectasia: its prevalence and clinical significance in 4993 patients. *Br Heart J* 1985; 54: 392-5.
8. Topaz O, DiSciascio G, Cowley MJ, *et al.* Angiographic features of left main coronary artery aneurysms. *Am J Cardiol*. 1991; 67: 1139-42.
9. Selke KG, Vemulapalli P, Brodarick SA, *et al.* Giant coronary artery aneurysm: detection with echocardiography, computed tomography, and magnetic resonance imaging. *Am Heart J* 1991; 121: 1544-7.
10. Baretella MB, Bott-Silverman C. Coronary artery aneurysms: an unusual case report and review of the literature. *Cathet Cardiovasc Diagn* 1993; 29: 57-61.
11. Kumar K, Lepor NE, Naqvi TZ. Unusual presentation of an acute inferior myocardial infarction. *Rev Cardiovasc Med* 2002; 3: 152-6.
12. Sorrell VL, Davis MJ, Bove AA. Current knowledge and significance of coronary artery ectasia: a chronologic review of the literature, recommendations for treatment, possible etiologies and future considerations. *Clin Cardiol* 1998; 21: 57-60.
13. Guerios EE, Bueno RR, Andrade PM, *et al.* Aneurysm of the left main coronary artery. *Arq Bras Cardiol* 2000; 75: 531-6.
14. Virmani R, Robinowitz M, Atkinson JB, Forman MB, Silver MD, McAllister HA. Acquired coronary arterial aneurysms: an autopsy study of 52 patients. *Hum Pathol* 1986; 17: 575-83.
15. Selzman CH, Miller SA, Harken AH. Therapeutic implications of inflammation in atherosclerotic cardiovascular disease. *Ann Thorac Surg* 2001; 71: 2066-74.
16. Hirsch GM, Casey PJ, Raza-Ahmad A, Miller RM, Hirsch KJ. Thrombosed giant coronary artery aneurysm presenting as an intracardiac mass. *Ann Thorac Surg* 2000; 69: 611-3.
17. Erdol C, Celik S, Baykan M, Gokce M, Karahan B, Bayram A. A coronary aneurysm complicated by acute myocardial infarction: A case report. *J Cardiovasc Surg* 2001; 42: 65-7.
18. Lijoi A, Parodi E, Dottori V, Scarano F, *et al.* Atherosclerotic aneurysm of the left main coronary artery. Case report and review of the literature. *Minerva Cardioangiol* 2001; 49: 343-7.
19. Shimizu T, Hirayama T, Koizumi N, Ishimaru S, Nakai H, Tsuchida H. Surgical management of arteriosclerotic coronary artery aneurysm. *J Cardiovasc Surg (Torino)* 1999; 40: 535-8.
20. Antonellis IP, Patsilnakos SP, Pamboukas CA, *et al.* Sealing of coronary artery aneurysm by using a new stent graft. *Catheter Cardiovasc Interv* 1999; 48: 96-9.