

RESEARCH ARTICLE

- Kemal Peker¹**
Ismayıl Yılmaz²
Ismail Demiryılmaz³
Arda Isık⁴
Ilyas Sayar⁵
Cebraıl Gursul⁶
Murat Cankaya⁷
Taha Abdulkadir Coban⁸

¹Düzce University, Department of General Surgery

²Ministry of Health University General Surgery Department

³Akdeniz University, Department of General Surgery

⁴Erzincan University, Department of General Surgery

⁵Erzincan University, Department of Pathology

⁶Erzincan University, Department of Physiology

⁷Erzincan University, Department of Biology

⁸Erzincan University, Department of Biochemistry

Corresponding Author:

Kemal Peker
 Düzce University, Department of General Surgery
 mail: k.peker@yahoo.com.tr
 Phone: +90 5359368528

Received: 19.03.2020

Acceptance: 12.07.2020

DOI: 10.18521/ktd.706218

Konuralp Medical Journal
 e-ISSN1309-3878
 konuralptipdergi@duzce.edu.tr
 konuralptipdergisi@gmail.com
 www.konuralptipdergi.duzce.edu.tr

The Effect of Ozone Treatment on Thermal Burn Wound Healing; an Experimental Study

ABSTRACT

Objective: Ozone has been advised as a metabolic excitative in cell, immunomodulatory agent and antioxidant enzyme actuator. The present study was performed to designate the profit of ozone therapy on the burn wound healing in the rats.

Methods: 40 adult Wistar type rats divided into 4 groups: a control group (burn not created and topical and systemic agents not used), a burn group (burn created but only saline given), a burn+silver sulfadiazine group (silver sulfadiazine was applied for 21 days), a burn+ozone/oxygen mixture group (ozone/oxygen mixture was applied for 21 days). After anesthetizing, second-degree burn (2 cm² areas) was done on the dorsal of the animals by aluminum plate in boiling hot water (100 °C for 15 seconds) and other groups except control group were treated topically, based on the time scheduled. Tissue samples were harvested on day 7st and 21st after burn injury. Biochemical and histological analyzes were performed in tissue and blood samples. The results were assessed with appropriate statistical tests and given as Means±SD.

Results: The histopathologic damage level was significantly different in all groups. Fibrosis and inflammation levels decreased in ozone treatment and silver sulphadiazine groups compared to burn+normal saline group on the 21 days according to 7 days. In the ozone treatment group, Glucose 6-phosphate dehydrogenase activities were significantly higher than the silver sulfadiazine treated group. But glutathione reductase enzyme activities were lower in the ozone treated group and hydroxyproline concentration decreased in ozone group compared to burn+normal saline group on 7 and 21 days.

Conclusions: Ozone has a detractive effect in the development of inflammation, fibrosis, and granulation via decreasing tissue damage and increasing the antioxidant enzyme activity on burn wound healing.

Keywords: Wound Healing, Hydroxyproline, Burn

Ozon Tedavisinin Termal Yanık Yara İyileşmesine Etkisi; Deneysel Bir Çalışma

ÖZET

Amaç: Ozon, hücre içinde, immüno-modülatör unsur ve antioksidan enzim işleticisinde metabolik bir uyarıcı olarak önerilmiştir. Bu çalışma, sıçanlarda yanık yarası iyileşmesinde ozon tedavisinin yararını belirlemek için yapılmıştır.

Gereç ve Yöntem: Bu çalışma için 40 adet Wistar tipi sıçan 4 gruba ayrıldı: Bir kontrol grubu (yanık oluşturulmadı, bölgesel ve sistemik unsurlar kullanılmadı), bir yanık grubu (yanık oluşturuldu, ancak sadece salin verildi), bir yanık + gümüş sülfadiazin grubu (21 gün boyunca gümüş sülfadiazin uygulandı), bir yanık + ozon / oksijen karışımı grubu (21 gün boyunca ozon / oksijen karışımı uygulandı) oluşturuldu. Anestezi uygulandıktan sonra, kaynar sıcak suda (15 saniye boyunca 100 °C) alüminyum plaka ile hayvanların sırtında ikinci derece yanık (2 cm² alan) oluşturuldu ve kontrol grubu dışındaki diğer gruplar planlanan sürede bölgesel olarak tedavi edildi. Doku örnekleri yanık hasarından sonraki 7. ve 21. günlerde elde edildi. Doku ve kan örneklerinde biyokimyasal ve histolojik analizler yapıldı. Sonuçlar uygun istatistiksel testlerle değerlendirildi ve ± SD ortalamalar olarak verildi.

Bulgular: Histopatolojik hasar düzeyi tüm gruplarda anlamlı olarak farklıydı. Ozon tedavisi ve gümüş sülfadiazin gruplarında fibroz ve inflamasyon seviyeleri, 7 güne göre 21 günde yanık + normal tuzlu su grubuna kıyasla azaldı. Ozon tedavi grubunda, Glikoz 6-fosfat dehidrogenaz aktiviteleri gümüş sülfadiazin ile tedavi edilen gruptan önemli ölçüde yüksekti. Ancak glutatyon redüktaz enzim aktiviteleri, ozon ile tedavi edilen grupta daha düşüktü ve hidroksiprolin konsantrasyonu, 7 ve 21 günde yanık + normal tuzlu su grubuna kıyasla ozon grubunda azaldı.

Sonuç: Ozonun, doku hasarını azaltarak ve yanık yara iyileşmesinde antioksidan enzim aktivitesini artırarak iltihaplanma, fibrozis ve granülasyon gelişiminde bozucu bir etkisi bulunmaktadır.

Anahtar Kelimeler: Yara İyileşmesi, Hidroksiprolin, Yanık

INTRODUCTION

Burns are widely conceived as the most disruptive kind of traumatic injuries. Tissue damage starts as a consequence of interrelate of the skin with high heat (40°C) and this damage is intensified as parallel with increase of heat. Burn is very frequently encountered in the society, especially epileptic patients, drug addicts, children, alcoholics and the elderly are at risk (1). In fact, the unsuitable healing of the burn is evinced via high amount of free radical intervened damage, decreasing angiogenesis, collagen regeneration, and delayed granulation tissue evolvement. For this reason, the quiddity of the wound re-modelling depends essentially on the proficiency of wound care (2). Therefore, the quality of the wound regeneration depends mainly on the efficiency of wound care (2). Nevertheless, biomaterials of tissue engineering are extremely expensive and burn charge entails heavy expenses outside the reach of most of the patients in developing countries (3). Burn injuries lead to tissue damage, edema and crusting. Inflammation, granulation tissue formation, contraction and epithelialization play a role in normal wound healing (4).

Ozone is a unstable, sharp fragrant and colorless natural gas that is consisted of three oxygen atoms. Also, it is very powerful oxidizing and talented disinfect. Ozone not only kill viruse and bacteria but also oxidize all microorganisms and its toxins (5). Even though, initial years after its exploration, it was used as disinfection, today investigations have focused on dubitante for medical usage of ozone. Ozone should never be pure and require to mix a particular amount of oxygen (5). Ozone treatment may be explained as "a significant quantity of ozone/oxygen mixture is administered into circulation or body cavities". Ozone/oxygen gas mixture can be used by intramuscular, intravenous, intrapleural, intraarticular, intradiscal and intrarectal as well as topically (6). It is reported that ozone has the various biological mechanisms. Some of those mechanisms are related with activity of some enzymes as catalase, glutathione, and superoxide dismutase which are influential in the scavenging of free radicals and stimulates the immune system in small dosages. Ozone as other gases (O₂, CO₂) is water soluble. Ozonated water that used in wound care is one of strong germicides. Ozone applications have shown favourable influences in several cases as wound healing, hepatitis, ischemic, age-related macular degeneration and oral infections (5).

As a result, when we search in various databases as PUBMED, SCIENCE DIRECT, MEDLINE and GOOGLE SCHOLAR, we have not found any study on comparing the effects of topically of silver sulfadiazine and ozone/oxygen mixture in burn wounds. Therefore, the present study was designed to compare the effects of local

applications silver sulfadiazine and Ozone on second degree thermal burns in rats.

MATERIAL AND METHODS

Ethical Approval and Animals: The experimental procedures with the animals which used in this study were assented by the Ethics Committee of the Atatürk University, Faculty of Veterinary, Erzurum, Turkey (the reference code:2015/67). The present study was planned under the criteria of the Health Guide for the Care and Use of Laboratory Animals by the National Institutes of Health (NIH Publication No: 86-23, Revised 1985 Bethesda).

In the present study, forty Wistar male rats weighing 380±20 g were obtained from research center the experiment animals of Atatürk University. The animals that used in the experiment were maintained in plastic cages (360 mmx200 mmx190 mm) under the appropriate conditions in laboratory (12-hour light/dark cycle, a temperature 25±1 °C, humidity 55±5 %) and expensed a standard pellet and water ad libidum. The rats used in the experiment were starved for 12 hours before experiment, but we were allowed to drink just water.

Groups and Induction of Burn in Rats:

After 24 hours' acclimatization, second-degree burns were formed in 40 adult Wistar rats. Rats were randomly divided into four group. Each group involved of ten rats: Group 1 was the control group and burn was not created (no topical agent was applied) and tissue biopsy samples were taken on 7 and 21 days. After the rats were sacrificed at the end of 21 days, tissue and blood samples were obtained. Group 2 was the burn group (other topical agent wasn't applied except normal saline). After, burn wound was closed with sterile gauze and the rats were sacrificed at the end of 21 days. For Group 3, wound dressing was done with 1% silver sulfadiazine once on a day. Group 4 was treated with ozone/oxygen mixture once on a day and topically administrated on burns and the rats were sacrificed. Later, tissue samples were taken as the Group I. Also, ozone/oxygen mixture were dissolved in physiological saline. All the treatments were administrated topically and binded by using sterile gauze until the first group completely healed. The healing period was followed up clinically. Four parameters were histopatologically assessed in the determination of wound healing: inflammation, fibrosis, granulation, and macroscopic healing. In all groups, wound dressings were done under anesthesia at the same time in the morning and once on a day.

Drugs and the Experimental Procedure:

Group 3 was treated with 1% silver sulfadiazine. It was commercially found as 1% Silvadiazin cream (Toprak Drug Co.). Group 4 was treated with ozone/oxygen mixture. Ozone/oxygen mixture was prepared by dissolving in normal saline. Pursuant to

our treatment protocol, the drugs were performed as a thin layer on the wounds. Also, all wounds were conserved with sterile gauze with adhesive elastic bandage (Setanet® No: 3) and changed on a daily. Anesthesia was reached via a single dose of intraperitoneal 60 mg/kg of ketamine hydrochloride (Ketalar® Eczacıbaşı Warner-Lambert Drug Industry, Levent, İstanbul) and 10 mg/kg of xylazine hydrochloride (Rompon® Bayer, Şişli, İstanbul) mixture. The dorsal region of the rats was shaved and cleaned with 10% of povidone-iodine solution (Kim-Pa, Poviiodeks, 10% povidone-iodine). Especially, contemplated aluminum plate

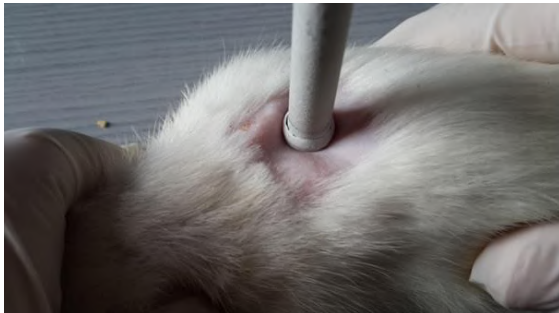


Figure 1. Induction of burn in rats

with 10 cm² of surface area (2.5x4 cm diameter) was used for the generation of burns. The aluminum plate has been sterilized in boiling water (100 °C) for 5 minutes, after then, it was applied on the skin of anesthetized rats for 30 seconds with pressure (Figure 1). Using this procedure, second-degree burn were formed (Figure 2). After the formation of burns, all the rats were placed and kept in individual cages. After operation, analgesia for rats was provided subcutaneously of fentanyl citrate at the dose 0.02 micg/kg of 2x1 (Fentanyl Citrate ampul Abbott, Beykoz, İstanbul).

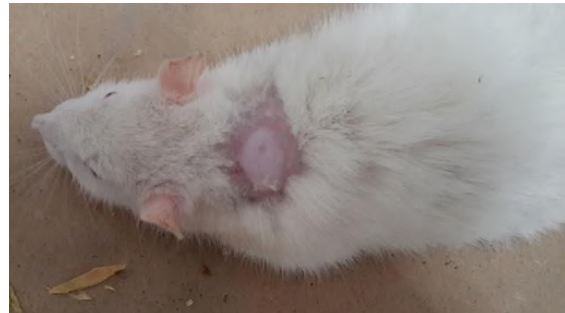


Figure 2. Formation of burn in rats.

Ringer's lactate for 2 mL according to the Parkland formula was given intraperitoneally for resuscitation post burn. All the rats under anesthesia was sacrificed by cervical dislocation. The blood and tissue samples were evaluated in pathology laboratories, additionally level of recovery in burn wounds was assessed, macroscopically (Figure 3).

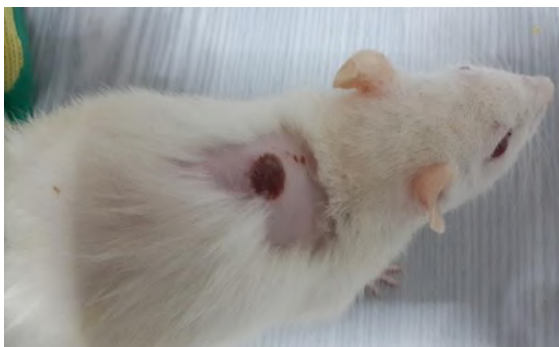


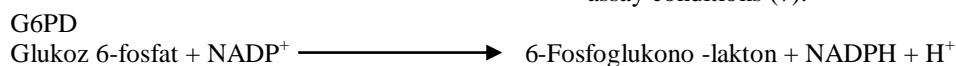
Figure 3. Macroscopic view of the burn wound one week late

Also, the effects of ozone was examined on the oxidative system, biochemically. The concentration of hydroxyproline was assessed in the blood samples and given as nmol/ml. Glucose 6-phosphate dehydrogenase, Glutathione reductase, and 6-phosphogluconate dehydrogenase were measured in tissue. The results were presented as nmol/gr.

Biochemical Analysis

Measurement of G6PD Enzyme Activity:


Glucose 6-phosphate dehydrogenase (G6PD) activity was defined by monitoring Nicotinamide Adenine Dinucleotide Phosphate Hydrogen (NADPH) production at 340 nm and 25 °C. The assay mixture contains 10 mM magnesium chloride, 0.2 mM NADP⁺, and 0.6 mM G6PD in 100 mM Tris-hydrochlorid buffer solution at pH 8.0. Analyses were performed in triplicate and the activities were followed up for 60 s. One unit of activity (U) is defined as the amount of enzyme required to reduce 1 μmol/min of NADP⁺ under the assay conditions (7).



Measurement of 6PGD Enzyme Activity:
6-phosphogluconate dehydrogenase (6PGD) activity was measured by monitoring NADPH production at 340 nm and 25 °C. The assay mixture activities were followed up for 60 s. One unit of activity (U) is defined as the amount of

contained 10 mM magnesium chloride, 0.2 mM NADP⁺, and 0.6 mM 6PGD in 100 mM Tris-hydrochlorid buffer solution at pH 8.0.

Assays were carried out in triplicate and the enzyme required to reduce 1 μmol/min of NADP⁺ under the assay conditions (7).



Measurement of Glutathione Reductase

Enzyme Activity: Glutathione reductase enzyme activity was measured by Beutler's method. One enzyme unit is defined as the oxidation of 1 mmol NADPH per min under the assay condition (25 °C, pH 8.0) (8).

Measurement of Hydroxyproline:

Hydroxyproline concentration was determined by the procedure of Reddy and Enwemeka² with a slight modification. Hydroxyproline concentration is determined by the reaction of oxidized hydroxyproline with 4-Dimethylaminobenzaldehyde. It can be measured at 560 nm (8).

Histopathological Examination: For histological analysis, the formalin-fixed skin samples were prepared for paraffin sections. Then, 4-µm sections were made and placed on slides. These slides were stained with hematoxylin and eosin (H&E). Histopathological examination of the rat tissue damage was done for each parameter: dermal inflammation, granulation tissue and fibrosis based on a scoring system where none=0, mild=1 +, moderate=2 +, and severe=3 +. Histopathological evaluations were done using a light microscope (Olympus BX53, Tokyo, Japan).

Statistical Analysis: Our results were denoted as Mean±Standard Deviation (Mean±SD). In case of multiple comparisons, repeated measurements of analysis of variance were performed to compare the mean differences between and within groups followed by Tukey tests. The Student's test was used to compare the average weight of rats before and after the experiment. The level of statistical significance was received as p<0.05.

RESULTS

In beginning of the study, all the burn wounds were similar. At the end of three weeks, no unhealed wounds were present. These results are suggested that ozone is influential in healing experimentally formed second-degree burns in rats. Prospected, randomized, controlled clinical studies are exigenced to estimate the safety, profit, and effectualness of this treatment procedure for patients with second-degree burn wounds.

Table 1 shows tissue G6PD, 6PGD, and Glutathione Reductase (GR) activities of burn and experimental groups. In ozone treated group, a significant increase were observed in G6PD and 6PGD, whereas the GR level decreased significantly in the ozone group compared to treated with silver sulfadiazine group.

Table1. Effect of burn+normal saline, 1% silver sulphadiazine, and ozone on G6PD, 6PGD, and GR activities in the samples taken at the end of 3rd week(21st days) on burn wound healing model in rats. Values are presented as the Mean±SD (n=10).

| | Control ^{a,b,c} (n=10) | Burn+Normal Saline ^{b,c} (n=10) | 1% silver sulphadiazine ^c (n=10) | Ozone/Oxygen mixture dissolved in saline (n=10) | |
|-----------------------|------------------------------------|---|--|--|----|
| G6PD (nmol/gr) | 14.01±1.57 | 13.37±1.47 | 13.47±1.41 | 23.43±2.28 | ** |
| 6PGD (nmol/gr) | 2.29±1.13 | 3.67±0.65 | 3.90±1.83 | 3.94±0.58 | * |
| GR (nmol/gr) | 13.77±1.74 | 16.24±2.59 | 14.09±2.26 | 12.70±1.28 | * |

Note: Each value represents mean +S.D. a: different from the burn+normal saline group b: different from the 1% silver sulphadiazine group c: different from the ozone group. *p<0.05, **p<0.01levels of significance.

The hydroxyproline levels are presented in Table 2. Hydroxyproline levels were significantly increased in the burn group (p<0.01). We have

observed that a reduction on concentration of hydroxyprolinehas been seen in treated with ozone and silver sulfadiazine ratson 21st day.

Table 2. The concentration of hydroxyproline in the samples taken at the end of 1st and 3rd weeks is presented on burn wound healing model in rats for all groups. Values of are presented as the Mean±SD. (n=10).

| | Control ^{a,b,c} (n=10) | Burn+Normal Saline ^{b,c} (n=10) | 1% silver sulphadiazine ^c (n=10) | Ozone/Oxygen mixture dissolved in saline(n=10) | |
|--|------------------------------------|---|--|--|----|
| The concentration of hydroxyproline (nmol/ml) (1st Week) | 0.04±0.00 | 0.27±0.05 | 0.23±0.05 | 0.24±0.02 | ** |
| The concentration of hydroxyproline (nmol/ml) (3rd Week) | 0.04±0.00 | 0.02±0.03 | 0.01±0.02 | 0.01±0.02 | |

a: Different from the normal saline group b: Different from the 1% silver sulphadiazine group c: Different from the ozone group. **p<0.01. Hydroxyproline concentration was varied depending on the week in all groups except the control (p<0.01).

Histopathological assessments have been shown greater healing in both ozone and silver sulfadiazine groups compared to the control group on 7 and 21 days. Haematoxylin and eosin stained sections of granulation tissue collected were

examined on 7th and 21st days. The level of the inflammation was decreased and fibrosis area was abated as a result of treatment with ozone (Table 3, 4, and 5).

Table 3. Score of the inflammation in the samples taken at the end of 1st and 3rd weeks (7th and 21st days) is presented on burn wound healing model in rats for all groups. Values are presented as the Mean±SD. (n=10).

| | Control ^{a,b,c} (n=10) | Burn+Normal Saline ^{b,c} (n=10) | 1% silver sulphadiazine ^c (n=10) | Ozone/Oxygen mixture dissolved in saline(n=10) | |
|---|------------------------------------|---|--|--|----|
| Inflammation (1st Week) | 0.00±0.00 | 2.00±0.82 | 1.20±0.42 | 1.20±0.42 | ** |
| Inflammation (3rd Week) | 0.00±0.00 | 1.20±0.42 | 1.10±0.74 | 0.90±0.74 | |

a:Different from the normal saline group b: Different from the 1% silver sulphadiazine group c: Different from the Ozone group. **p<0.01 Inflammation was varied depending on the week in all groups except the control (p<0.01).

Table 4. Score of the granulation in the samples taken at the end of 1st and 3rd weeks is presented on burn wound healing model in rats for all groups. Values are presented as the Mean±SD (n=10).

| | Control ^{a,b,c} (n=10) | Burn+Normal Saline ^{b,c} (n=10) | 1% silver sulphadiazine ^c (n=10) | Ozone/Oxygen mixture dissolved in saline(n=10) | |
|--|------------------------------------|---|--|--|----|
| Granulation (1st Week) | 0.00±0.00 | 2.80±0.42 | 2.10±0.57 | 1.60±0.52 | ** |
| Granulation (3rd Week) | 0.00±0.00 | 1.50±0.53 | 1.20±0.63 | 1.10±0.57 | |

a: Different from the normal saline group b: Different from the 1% silver sulphadiazine group c: Different from the ozone group. **p<0.01; Granulation was varied depending on the week in all groups except the control (p<0.01).

Table 5. Score of the fibrosis the samples taken at the end of 1st and 3rd weeks is presented on burn wound healing model in rats for all groups. Values are presented as the Mean±SD (n=10).

| | Control ^{a,b,c} (n=10) | Burn+Normal Saline ^{b,c} (n=10) | 1% silver sulphadiazine ^c (n=10) | Ozone/Oxygen mixture dissolved in saline(n=10) | |
|---------------------------------------|------------------------------------|---|--|--|----|
| Fibrosis (1st Week) | 0.00±0.00 | 2.20±0.63 | 1.90±0.32 | 1.60±0.52 | ** |
| Fibrosis (3rd Week) | 0.00±0.00 | 2.00±0.00 | 1.40±0.52 | 1.40±0.52 | |

a: Different from the normal saline group b: Different from the 1% silver sulphadiazine group c: Different from the ozone group. **p<0.01. Fibrosis was varied depending on the week in all groups except the control (p<0.01).

Granulation tissue whichwell-organized was observed in rats that treated with ozone compared to control group on 21st day. A greater reduction on level of granulation was observed in treated with ozone rats on 7thdayaccording to 21stday, whereas organization of granulation tissue

was escalated in the group of burn+normal saline. Macroscopic healing have showed differences in all groups except control group. A better macroscopic healing was observed in ozone treated according to silver sulfadiazine on 21st day (Table 6).

Table 6. Score of the macroscopic healing are presented for all groups.

| | Control ^{a,b,c} (n=10) | Burn+Normal Saline ^{b,c} (n=10) | 1% silver sulphadiazine ^c (n=10) | Ozone/Oxygen mixture dissolved in saline(n=10) | |
|---|------------------------------------|---|--|--|---|
| Macroscopic Healing Scor (1st Week) | 0.00±0.00 | 6.80±1.32 | 5.70±1.25 | 6.10±0.57 | |
| Macroscopic Healing Scor (2nd Week) | 0.00±0.00 | 2.30±1.06 | 1.90±1.29 | 1.10±0.57 | * |
| Macroscopic Healing Scor (3rd Week) | 0.00±0.00 | 0.60±0.69 | 0.20±0.42 | 0.20±0.42 | |

a:Different from the normal saline group b: Different from the 1% silver sulphadiazine group c: Different from the ozone group. *p<0.05. Macroscopic healing was varied depending on the week in all groups except the control (p<0.05).

DISCUSSION

Deterioration of the skin usually leads to infection, scarring, increased fluid loss, hypothermia, compromised immunity and altered in body image (9, 10). All these factors are very important; besides, enlarged skin damage can end up with mortality. The mortality rate from burns has rejected in the past decade; however, it is still high if more than 70% of the body surface is burned (11). Burns are classified according to the depth of the injury. In superficial second-degree burns, the epidermis and the superficial dermis are mainly affected. These kinds of burns are very painful. The main reasons of a superficial second-degree burn are hot liquids (12). Healing of skin wounds is a quite complicated process containing many mechanisms, such as inflammation, epidermal regeneration, fibroblast proliferation, neovascularization and synthesis, coagulation, matrix synthesis and deposition, angiogenesis, and epithelization (13-15). Although there have been some developments, the best treatment is still unclear. Ozone is a potent oxidizing agent and an important disinfectant. The bactericidal effect of ozone is based on a direct attack on microorganisms by oxidation of biological materials (16, 17). Datas have been shown that bacteria, spores, and viruses are inactivated by ozone after only few minutes (18, 19). Ozone may act through mechanisms other than oxidation, including the activation of erythrocyte metabolism and immune cells (20, 21). Besides, the explanation of the disinfectant activity and the activation of immune system of ozone has been reported (18). Either ozonated bidistilled water or oil have been used in treatment of war wounds, anaerobic infection, trophic ulcers and burns (22). Enhancement of circulation with ozone therapy may provide normal healing with removal of the breakdown products, unclogging the blood vessels, resulting in increased oxygenation of the tissues (6, 23-25). It seems likely that ozone therapy prevents smooth muscle death, by supporting increased O₂ and Adenosine Triphosphate (ATP) to injured cells, which decrease the fibroplasia during healing of corrosive esophageal burns. However, our findings provide a novel therapeutic agent for skin injuries in humans have shown the beneficial action of ozone. Several experimental studies have been shown that ozone therapy ameliorates the tissue injury depends on free radicals in various forms of shock, stroke, inflammation, and reperfusion injury (6, 23, 24, 26, 27). In addition, it is reported that ozone enhances the glycolysis enzymatic pathway in ATP production. This is significant in the management of stroke and burns (23). From these studies, it can be concluded that ozone therapy has beneficial effects on healing and preventive effects on the generation of fibrosis in skin burn in rats. Also, in the study of caustic esophageal burn is demonstrated that collagen deposition in the submucosa and damage to the muscular is mucosa

and tunica muscular is in the ozone treatment group was found less than in the un-treatment group and these histopathologic findings showed correlation with hydroxproline levels (28). A significant difference was determined between the topically applied ozone compared to the control group in the acute cutaneous wound healing created in pigs (28). Martinez-Sanchez et al. have evaluated the efficacy of ozone therapy in the patients with diabetic foot and remarked to be expedited wound healing and increased antioxidant enzyme activities in patients used ozone therapy compared to used antibiotic therapy (29).

Different experiment animals such as Guinea pig (30) and rat (31, 32) were used in various studies. We have used rat model in the present study similar to some investigators (31, 32). The model used in the experiment is simple and repeatable. The burned wound healing model provides *in-vivo* approach on the healing of burned wounds in domestic animals.

The pentose phosphate pathway is a key section of metabolism and composed of the oxidative portio and the non-oxidative portio. The NADPH is important co-factor for many enzymatic reactions enable cells to counterbalance the oxidative stress via the generation of glutathione (GSH) by GR. The pentose phosphate pathway is one of the major sources of reduction equivalents for the glutathione peroxidase/glutathione reductase (GPx)/GR antioxidant system. The oxidative pentose phosphate pathway is known as one of the basic regions of NADPH production in cell and catalyzed by some enzymes as G6PD, G6PD. G6PD is the first enzyme in the pentose phosphate pathway (33). It catalyses the oxidation of glucose-6-phosphate using NADP⁺, yielding pentose phosphates for nucleotides synthesis, as well as NADPH/NADH for reductive biosynthesis and protection from oxidative stress (34). G6PD is the main intracellular source of NADPH generation, involved in diverse physiological processes. Moreover, increasing evidences have pointed that NADPH play a fundamental role as a common mediator of numerous biological processes such as carbohydrate metabolism, mitochondrial functions, calcium homeostasis, oxidative stress generation, immunological functions, aging and cell death (35). The redox status of the cell is the key regulator of energy production and intermediary metabolism which play a crucial role in the repair process. As a consequence, this enzyme finds numerous applications in medical and biochemical studies (36). Recently, we discovered that 6PGD also plays a role in human cancer (37). Antioxidant effect may also help to control wound oxidative stress and thereby accelerate wound healing (38).

We have found that bioenergetic pathways including tissue 6PGD, GR and G6PD enzyme activities were decreased in burn+normal saline

group, whereas they were increased treatment of ozone in rats. Several studies have been revealed that reactive oxygen species are generated at the burn site immediately after injury and these radicals causes tissue injury (39-43). On the other hand, it is well documented that ozone stimulates the production of interferon and interleukins in the body. Therefore, ozone may have a possible beneficial effect to reduce tissue damage by enhanced antioxidant enzyme activity (6, 26). Also, ozone is known as an activator of the immune system, namely, based on reports related to diseases characterized by immuno-depression such as chronic viral diseases, cancer and AIDS (6, 23, 25). This study demonstrated that ozone treatment lead to a significantly increase of G6PD activity which might collectively maintain the redox environment of the cell. This indicates that ozone causes the cellular machinery to resort to those biochemical

and molecular responses which fasten the healing mechanism post-burn injury.

CONCLUSION

The purpose of this study is to determine the role of topical treatment with ozone on burn wound healing in rats. The present study shows that in burn wound healing has a significant improvement by ozone. Also, our findings demonstrates that ozone are safe for topical use. There was no withdrawal or serious adverse reaction reported. However, these events were common signs and symptoms in burns, and they were present in both the ozone, silver sulfadiazine and the burn groups. Further studies is necessary to understand the molecular mechanism of action of ozone on burn wound healing.

Conflict of interest statement: All the authors indicate that they have no financial and/or personal relationships with other people or organizations that could inappropriately influence (bias) their work.

REFERENCES

- Jeschke MG, Chinkes DL, Finnerty CC, Kulp G, Suman OE, Norbury WB, et al. The pathophysiologic response to severe burn injury. *Ann Surg*. 2008;248(3):387-401.
- Arturson G. Pathophysiology of the burn wound and pharmacological treatment. The Rudi Hermans Lecture. *Burns*. 1996;22(4):255-74.
- Gupta A, Keshri GK, Yadav A, Gola S, Chauhan S, Salhan AK, et al. Superpulsed (Ga-As, 904 nm) low-level laser therapy (LLLT) attenuates inflammatory response and enhances healing of burn wounds. *Journal of Biophotonics*. 2015;8(6):489-501.
- Edwards LC, Dunphy JE. Wound healing I. Injury and normal repair. *N Engl J Med*. 1958;259(5):224-33
- Kutlubay Z, Engin B, Serdaroğlu S, Tüzün Y. Dermatolojide ozon tedavisi. *Dermatoz*. 2010;1(4):209-16.
- Bocci VA. Scientific and medical aspects of ozone therapy. State of the art. *Arch Med Res*. 2006;37(4):425-35.
- Beutler E. Red cell metabolism: 12. London: Academic Press; 1971.
- Reddy GK, Enwemeka CS. A simplified method for the analysis of hydroxyproline in biological tissues. *Clin Biochem*. 1996;29(3):225-9.
- Nalbandian RM, Henry RL, Balko KW, Adams DV, Neuman NR. Pluronic F-127 gel preparation as an artificial skin in the treatment of 3rd-degree burns in pigs. *J Biomed Mater Res*. 1987;21(9):1135-48.
- Sheridan RL, Tompkins RG. Skin substitutes in burns. *Burns*. 1999;25(2):97-103.
- O'Connor NE, Mulliken JB, Banks-Schlegel S, Kehinde O, Green H. Grafting of burns with cultured epithelium prepared from autologous epidermal cells. *Lancet*. 1981;1(8211):75-8.
- Pearson AS, Wolford RW. Management of skin trauma. *Primary Care*. 2000;27(2):475-92.
- Brown GL, Curtsinger LJ, White M, Mitchell RO, Pietsch J, Nordquist R, et al. Acceleration of tensile strength of incisions treated with EGF and TGF-Beta. *Ann Surg*. 1988;208(6):788-94.
- Fu XB, Shen ZY, Chen YL, Xie JH, Guo ZR, Zhang ML, et al. Randomised placebo-controlled trial of use of topical recombinant bovine basic fibroblast growth factor for second-degree burns. *Lancet*. 1998;352(9141):1661-4.
- Ueno H, Yamada H, Tanaka I, Kaba N, Matsuura M, Okumura M, et al. Accelerating effects of chitosan for healing at early phase of experimental open wound in dogs. *Biomaterials*. 1999;20(15):1407-14.
- Mehlman MA, Borek C. Toxicity and biochemical-mechanisms of ozone. *Environ Res*. 1987;42(1):36-53.
- Silva RA, Garotti JER, Silva RSB, Navarini A, Pacheco AM. Analysis of the bactericidal effect of ozone pneumoperitoneum. *Acta Cir Bras*. 2009;24(2):124-7.
- Bocci V. Ozone as a bioregulator. Pharmacology and toxicology of ozonotherapy today. *J Biol Reg Homeos Ag*. 1996;10(2-3):31-53.
- Bocci V, Paulesu L. Studies on the biological effects of ozone 1. Induction of interferon gamma on human leucocytes. *Haematologica*. 1990;75(6):510-5.
- Buckley RD, Hackney JD, Clark K, Posin C. Ozone and human blood. *Archives of environmental health*. 1975;30(1):40-3.
- Zimran A, Wasser G, Forman L, Gelbart T, Beutler E. Effect of ozone on red blood cell enzymes and intermediates. *Acta Haematol*. 2000;102(3):148-51.
- Bocci V. Biological and clinical effects of ozone. Has ozone therapy a future in medicine? *Brit J Biomed Sci*. 1999;56(4):270-9.

23. Bocci V. Ozone as Janus: this controversial gas can be either toxic or medically useful. *Mediat Inflamm.* 2004;13(1):3-11.
24. Clavo B, Catala L, Perez JL, Rodriguez V, Robaina F. Ozone therapy on cerebral blood flow: A preliminary report. *Evid-Based Compl Alt.* 2004;1(3):315-9.
25. Zamora ZB, Borrego A, Lopez OY, Delgado R, Gonzalez R, Menendez S, et al. Effects of ozone oxidative preconditioning on TNF-alpha release and antioxidant-prooxidant intracellular balance in mice during endotoxic shock. *Mediat Inflamm.* 2005(1):16-22.
26. Calunga JL, Zamora AB, Borrego A, del Rio S, Barber E, Menendez S, et al. Ozone therapy on rats submitted to subtotal nephrectomy: Role of antioxidant system. *Mediat Inflamm.* 2005(4):221-7.
27. Peralta C, Xaus C, Bartrons R, Leon OS, Gelpi E, Rosello-Catafau J. Effect of ozone treatment on reactive oxygen species and adenosine production during hepatic ischemia-reperfusion. *Free Radical Res.* 2000;33(5):595-605.
28. Guven A, Gundogdu G, Sadir S, Topal T, Erdogan E, Korkmaz A, et al. The efficacy of ozone therapy in experimental caustic esophageal burn. *J Pediatr Surg.* 2008;43(9):1679-84.
29. Martinez-Sanchez G, Al-Dalain SM, Menendez S, Re L, Giuliani A, Candelario-Jalil E, et al. Therapeutic efficacy of ozone in patients with diabetic foot. *Eur J Pharmacol.* 2005;523(1-3):151-61.
30. Eldad A, Weinberg A, Breiterman S, Chaouat M, Palanker D, Ben-Bassat H. Early nonsurgical removal of chemically injured tissue enhances wound healing in partial thickness burns. *Burns.* 1998;24(2):166-72.
31. Hebda PA, Lo CY. The effects of active ingredients of standard debriding agents - Papain and collagenase - on digestion of native and denatured collagenous substrates, fibrin and elastin. *Wounds.* 2001;13(5):190-4.
32. Hosnuter M, Gurel A, Babuccu O, Armutcu F, Kargi E, Isikdemir A. The effect of CAPE on lipid peroxidation and nitric oxide levels in the plasma of rats following thermal injury. *Burns.* 2004;30(2):121-5.
33. Chan B, Sukhatme VP. One-step purification of soluble recombinant human 6-phosphogluconate dehydrogenase from *Escherichia coli*. *Protein Expres Purif.* 2013;92(1):62-6.
34. Au SWN, Gover S, Lam VMS, Adams MJ. Human glucose-6-phosphate dehydrogenase: the crystal structure reveals a structural NADP(+) molecule and provides insights into enzyme deficiency. *Struct Fold Des.* 2000;8(3):293-303.
35. Chan EC, Jiang F, Peshavariya HM, Disting GJ. Regulation of cell proliferation by NADPH oxidase-mediated signaling: potential roles in tissue repair, regenerative medicine and tissue engineering. *Pharmacology & Therapeutics.* 2009;122(2):97-108.
36. Xu YZ, Osborne BW, Stanton RC. Diabetes causes inhibition of glucose-6-phosphate dehydrogenase via activation of PKA, which contributes to oxidative stress in rat kidney cortex. *Am J Physiol-Renal.* 2005;289(5):F1040-F7.
37. Sukhatme VP, Chan B. Glycolytic cancer cells lacking 6-phosphogluconate dehydrogenase metabolize glucose to induce senescence. *Febs Lett.* 2012;586(16):2389-95.
38. Fitzmaurice SD, Sivamani RK, Isseroff RR. Antioxidant therapies for wound healing: A clinical guide to currently commercially available products. *Skin Pharmacol Phys.* 2011;24(3):113-26.
39. Demling RH, Lalonde C. Systemic lipid-peroxidation and inflammation induced by thermal-injury persists into the post-resuscitation period. *J Trauma.* 1990;30(1):69-74.
40. Gunel E, Caglayan F, Caglayan O, Akillioglu I. Reactive oxygen radical levels in caustic esophageal burns. *J Pediatr Surg.* 1999;34(3):405-7.
41. Gunel E, Caglayan F, Caglayan O, Canbilen A, Tosun M. Effect of antioxidant therapy on collagen synthesis in corrosive esophageal burns. *Pediatr Surg Int.* 2002;18(1):24-7.
42. Horton JW. Free radicals and lipid peroxidation mediated injury in burn trauma: the role of antioxidant therapy. *Toxicology.* 2003;189(1-2):75-88.
43. Ocakci A, Coskun O, Tumkaya L, Kanter M, Gurel A, Hosnuter M, et al. Beneficial effects of Ebselen on corrosive esophageal burns of rats. *Int J Pediatr Otorhi.* 2006;70(1):45-52.