



Effect of topical rifamycin application on epidural fibrosis in rats

Cem Dinç¹, Cengiz Tuncer¹, Mehmet Erhan Türkoğlu², Mehmet Tokmak³, Pınar Ocak¹, Uygur Er¹

¹Department of Neurosurgery, Düzce University School of Medicine, Düzce, Turkey

²Department of Neurosurgery, Ministry of Health, Dışkapı Yıldırım Beyazıt Training and Research Hospital, Ankara, Turkey

³Department of Neurosurgery, Medipol University, School of Medicine, İstanbul, Turkey

Received: December 01, 2017 Accepted: February 01, 2018 Published online: January 31, 2019

ABSTRACT

Objectives: This study aims to investigate the effects of topical rifamycin SV application on epidural fibrosis formation in a rat model.

Materials and methods: Between March 2015 and April 2015, a total of 20 Wistar rats were equally and randomly divided into laminectomy only group (control group) and laminectomy and rifamycin SV group (treatment group). Laminectomy was performed between L3-L5 in all rats. Surgical field was irrigated with 1 mL rifamycin SV (1 mL). After four weeks, vertebral columns of the rats were removed *en bloc* between the L1 and L5 levels, and epidural fibrosis and arachnoid involvement were histopathologically evaluated and graded.

Results: Grade 3 epidural fibrosis formation ratio was lower in the treatment group (40%) compared to the control group (80%). However, there was no statistically significant difference between the treatment and control groups in terms of epidural fibrosis ($p=0.164$) and arachnoid involvement ($p=0.303$).

Conclusion: Intraoperative rifamycin irrigation tends to reduce epidural fibrosis formation risk, although not statistically significant.

Keywords: Epidural fibrosis, laminectomy, rifamycin.

Epidural fibrosis is a natural response of the body to the impact of surgery, leading to marked reduction in the cellularity of the tissue and excessive deposition of the extracellular matrix components such as collagen, fibronectin, and dermatan sulfate.^[1] The complex and multistep processes of the formation of epidural fibrosis adjacent to the dura mater is an inevitable, despite its necessity, and well-known effect of posterior spinal surgeries. Unfortunately, the compression or stretching of the associated nerve root or the neighboring dura mater by the responder tissue may lead to persistent back and leg pain, so-called post-laminectomy syndrome or failed back syndrome.^[2] The ratio of patients suffering from persistent pain may be as high as 24% following lumbar discectomy.^[3-6] Furthermore, revision surgeries for epidural fibrosis tend to be risky and more complicated due to dural tears, injuries to the nerve root, and epidural bleeding from the granulation tissues, leading to low success rates.^[4,7]

Rifamycin SV is a well-known semisynthetic antituberculosis agent which has been used widely in various surgical procedures owing to its bactericidal effects against wide spectrum of Gram-negative and Gram-positive microorganisms with a tendency to *Staphylococcus aureus*.^[8] Peritoneal lavage with rifamycin SV is suggested to be effective in the treatment of intraabdominal infections and reducing adhesion formation, as well.^[9] Furthermore, the topical administration of rifamycin SV during spinal neurosurgical procedures via intraoperative irrigation of the surgical field is increasing. Surgical site irrigation for the prevention of both superficial and deep wound infections is mostly preferred in cases with prolonged operative times requiring foreign material implantations. Although there are many data in the literature which discuss the role of rifamycin SV in the treatment of wound infections,^[10,11] data about the effects of topical rifamycin SV on epidural fibrosis following spinal procedures is limited.

Corresponding author: Cem Dinç, MD. Düzce Üniversitesi Tıp Fakültesi Beyin Cerrahisi Anabilim Dalı, 81620 Düzce, Turkey.

e-mail: drcemdinc@yahoo.com

Cite this article as:

Dinç C, Tuncer C, Türkoğlu ME, Tokmak M, Ocak P, Er U. Effect of topical rifamycin application on epidural fibrosis in rats. Turk J Phys Med Rehab 2019;65(1):24-29.

Presented at the XVI. World Congress of Neurosurgery, August 20-25, 2017, İstanbul, Turkey.

In the present study, we aimed to investigate the effects of topical rifamycin SV irrigation on epidural fibrosis after laminectomy in a rat model. We hypothesized that rifamycin SV would be effective in the alleviation of epidural fibrosis after laminectomy. If this hypothesis is true, it might lead to new studies searching the dose-dependent effect of rifamycin SV as well as studies comparing rifamycin SV and other materials which were previously proven to be effective in the prevention of epidural fibrosis, in higher-order animal models.

MATERIALS AND METHODS

Animals

All the experimental procedures were performed with the permission of the Committee of Ethics for Animal Studies of Abant İzzet Baysal University to minimize the discomfort of the animals during the surgery and recovery periods. In this experimental study which was conducted between March 2015 and April 2015, a total of 20 adult, female Wistar rats, weighing 250 to 350 g were used.

Experimental groups

The rats were randomly divided into two groups providing 10 rats in each group. The control group (n=10) did not receive any treatment but laminectomy. In the treatment group (n=10), surgical field was irrigated with 1 mL rifamycin SV (Rif[®] 250 mg/3-mL ampoule).

Anesthesia and surgical procedure

The animals were anesthetized with intraperitoneal (i.p.) Xylazine (10 mg/kg; Bayer, Istanbul, Turkey) and ketamine hydrochloride (60 mg/kg; Parke-Davis, Istanbul, Turkey) prior to the surgical procedures. The lower back of each rat was shaved, and the surgical area was sterilized with povidone. A vertical midline skin incision was made over the L3-L5 levels with the aid of operative microscope under a magnification of 16× (Zeiss OPMI 1; Carl Zeiss Meditec, Oberkochen, Germany). The lumbosacral fascia was incised, and the L3-5 laminae were exposed after subperiosteal dissection of the paraspinal muscles. The L3, L4 and L5 laminae were totally removed. Dura was clearly and completely exposed after the removal of ligamentum flavum and epidural fat tissue of the relevant surgical area. Hemostasis was achieved by cotton pads. The treatment was administered to the treatment group and the wounds were closed in anatomical layers.

The animals were sacrificed on postoperative Day 30 with a lethal dose (60 mg/kg; IE Ulagay, Istanbul, Turkey) of pentobarbital. The vertebral columns of the rats were removed *en bloc*, including the whole laminectomy area between the L1 and L5 levels. The specimens were, then, placed in 10% buffered formalin.

Evaluation of epidural fibrosis

The specimens were dehydrated and embedded in paraffin after complete decalcification with ethylenediaminetetraacetic acid (EDTA, R&D Systems Inc., Minneapolis, MN, USA) for histological examination. Sections of 10 µm were obtained on the axial plane and stained with the Masson's trichrome which stains nuclei black, collagen blue and muscle fibers, cytoplasm and keratin red. The sections were examined with the aid of Nikon Eclipse 80i microscope (Nikon Corporation, Tokyo, Japan) and photographed by using a Nikon DS-Fi1 camera (Nikon Corporation, Tokyo, Japan). All the laminectomy sections were evaluated for fibrosis density and arachnoid involvement by a single pathologist who was blind to the study groups. Quantitative morphometric analysis of the sections was performed by the Nikon Nis elements D 3.1 Digital Analyzing System (Nikon Corporation, Tokyo, Japan). A magnification of 100× was used for the measurements. The thickness of the fibrosis was measured at three different points. As previously described in the literature, the first sample was obtained from the midpoint of the laminectomy defect, while the second and third samples were obtained 2 mm from the right and left sides of the first sample, respectively.^[9] Epidural fibrosis was graded according to the following scheme suggested by He et al.^[12] Grade 0, there is no scar tissue on dura mater; Grade 1, there is only a thin fibrous band between the scar tissue and the dura mater; Grade 2, there is scar tissue in less than two-thirds of the laminectomy defect; and Grade 3, there is scar tissue involving more than two-thirds of the laminectomy defect or extending to the nerve roots. The mean values were used for statistical analysis. The presence of arachnoid involvement was recorded.

Statistical analysis

Statistical analysis was performed using the IBM SPSS version 22.0 software (IBM Corp., Armonk, NY, USA). Descriptive data were expressed as the median (25-75%) for the comparison of fibrosis grades between the groups. The Fisher's exact test was used to analyze the contingency tables ($p < 0.05$). A p value of < 0.05 was considered statistically significant.

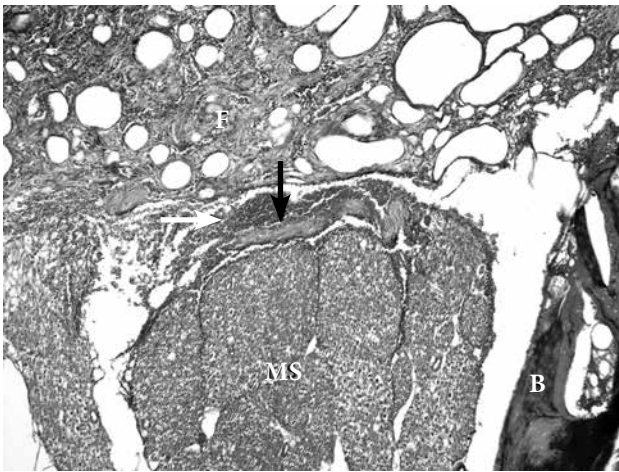


Figure 1. Photomicrograph showing Grade 3 epidural fibrosis in the treatment group. Masson's trichrome, original magnification 100x.
B: Bone; F: Fibrosis; Black arrow: Dura mater; MS: Medulla spinalis; White arrow: Muscle.

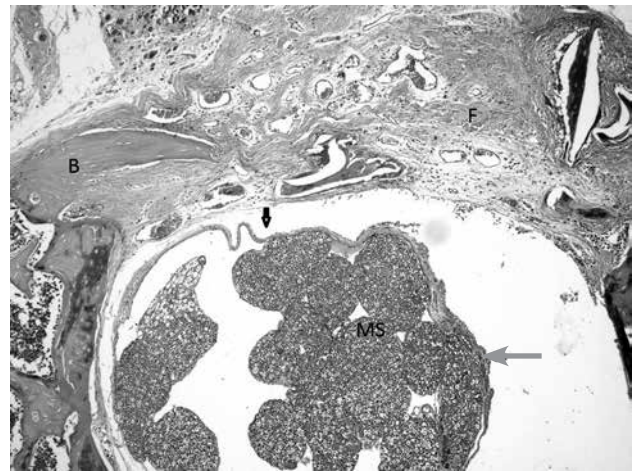


Figure 2. Photomicrograph showing Grade 3 epidural fibrosis in the control group. Masson's trichrome, original magnification 100x.
Epidural fibrosis (F) completely covered the laminectomy defect and adhered to the underlying dura mater (black arrow). B: Bone. MS: Medulla spinalis. Grey arrow: Muscle.

RESULTS

No adverse effects of rifamycin SV (erythema) and procedural complications (wound infection, hematoma, cerebrospinal fluid leakage) were observed. There was no mortality, and all the rats were ambulatory at the time of sacrifice. There was no statistically significant difference between the treatment and control groups in terms of epidural fibrosis ($p=0.164$) and arachnoid involvement ($p=0.303$).

In the treatment group, Grade 2 epidural fibrosis was seen in 50%, whereas Grade 3 epidural fibrosis (Figure 1) was seen in 40% of the axial sections stained with the Masson's trichrome. In the control group, Grade 2 epidural fibrosis was seen in 20% and Grade 3 epidural fibrosis (Figure 2) was seen in 80%; however, no Grade 1 epidural fibrosis was seen. On the other hand, in the treatment group, Grade 1 epidural fibrosis was seen in 10% of the sections. The fibrosis grading of

Table 1. Histopathological results of epidural fibrosis grades of study groups

Groups	Fibrosis Grade	n	%
Treatment	1	1	10.0
	2	5	50.0
	3	4	40.0
Total		10	100.0
Control	1	0	0.0
	2	2	20.0
	3	8	80.0
Total		10	100.0

$p=0.165$.

Table 2. Comparison of the arachnoid involvement of study groups*

Groups	Arachnoid involvement (-)		Arachnoid involvement (+)	
	n	%	n	%
Treatment	9	90.0	1	10.0
Control	6	60.0	4	40.0
Total	15	75.0	5	25.0

* Fisher's exact test was used; $p=0.303$.

the groups is shown in Table 1. Although the number of Grade 3 epidural fibrosis was significantly lower in the treatment group, there was no statistically significant difference between the treatment and control groups ($p=0.164$).

Arachnoid involvement was observed 10% and 40% of the sections in the treatment and control groups, respectively. However, there was no statistically significant difference between the treatment and control groups ($p=0.303$). The values regarding the arachnoid involvement are shown in Table 2.

DISCUSSION

Epidural fibrosis is the result of the proliferation of fibroblasts transforming into myoblasts and accumulation of disorganized extracellular matrix proteins,^[13] being a natural response of the body to surgery. The scar formation causes traction on dura mater and compression or tethering of the nerve roots leading to one of the most devastating causes of failed-back surgery with persistent lower back and leg pain.^[14-16] Unfortunately, 8 to 48% of patients with previous lumbar disc surgery suffers from failed-back surgery syndrome.^[17-19]

Key and Ford^[20] firstly reported epidural fibrosis following lumbar disc surgery. Since then, the administration of various kinds of drugs and materials such as autologous fat grafts, Adcon-L, polytetrafluoroethylene membrane, Gelfoam, and fibrinolytic agents have been administered desperately to the surgical field to act as a barrier or reduce the epidural fibrosis formation around the dura matter and nerve roots.^[4,21-25] However, the effective and accepted treatment of epidural fibrosis has not established, yet. Reoperation is complicated and dangerous due to the high likelihood of intraoperative nerve root injury and dural tear, as well.^[26] Therefore, preventing or minimizing the epidural scar formation is essential. Congenital root anomalies, excessive traction on the nerve roots and extreme blood loss during surgery, intraoperative use of sponges, and foreign tissue reactions are all shown to aggravate epidural fibrosis formation.^[27,28] Minimizing surgical dissection and performing meticulous hemostasis have been suggested to decrease scar tissue formation.^[29] Besides preventing epidural fibrosis, protecting the surgical area against wound infection should be one of the main goals of surgery.

Meticulous hemostasis was the main effort to prevent epidural fibrosis before certain agents and

materials were introduced to the surgical practice. With the introduction of these materials, surgeons have left scrupulous hemostasis. Hemostasis and washing surgical site are two most important factors for preventing epidural fibrosis. The content of washing water is crucial. A bactericidal liquid may be far more suitable than a simply sterile water.

Rifamycin SV irrigation of the surgical site, which has been well-studied and preferred by most of the neurosurgeons, is widely used to avoid superficial and deep wound infections.^[30] Additionally, rifamycin SV is found to have an inhibitory effect on cytokine and chemokine synthesis on monocytes and macrophages, leading to its usage in inflammatory bowel disease, rheumatoid arthritis, and gut inflammation.^[11,31-34] The detractive effect of rifamycin SV on the number of adhesions in the treatment of intraabdominal infections has been shown, as well.^[9] However, rifamycin SV has been studied only once in terms of its effects on epidural fibrosis reporting decreased formation of epidural fibrosis without a statistically significant difference, compared to the control group in a rat model.^[35]

In the present study, we investigated the effects of topical administration of rifamycin SV via the irrigation of the surgical area on epidural fibrosis formation in a rat model. Our data demonstrated that irrigating the laminectomized vertebrae with rifamycin SV decreased the grade of epidural fibrosis and arachnoid involvement. Grade 3 epidural fibrosis was found in four of the rats (40%) in the treatment group, while eight of the rats (80%) in the control group had Grade 3 epidural fibrosis. The median value of fibrosis grade was dramatically decreased in the treatment group. The median value of fibrosis grade did not decrease to Grade 1 in the control group. Although we observed clinically significance between the groups, there were no statistically significant differences between the groups which can be attributable to the small sample size, being the major limitation of the study.

In conclusion, our study results suggest that rifamycin SV can be used to avoid the formation of epidural fibrosis given the anti-inflammatory effects of the agent, although not statistically significant. However, further investigations in larger study samples are warranted.

Declaration of conflicting interests

The authors declared no conflicts of interest with respect to the authorship and/or publication of this article.

Funding

The authors received no financial support for the research and/or authorship of this article.

REFERENCES

- Koshiishi I, Hasegawa T, Imanari T. Quantitative and qualitative alterations of chondroitin/dermatan sulfates accompanied with development of tubulointerstitial nephritis. *Arch Biochem Biophys* 2002;401:38-43.
- Merskey H, Bogduk N. Spinal and Radicular Pain Syndromes of the Lumbar, Sacral, and Coccygeal Regions. In: Merskey H, Bogduk N, editors. *Classification of chronic pain*. 2nd ed. Seattle: IASP Press; 2004. p. 30-6.
- Cemil B, Tun K, Kaptanoglu E, Kaymaz F, Cevirgen B, Comert A, et al. Use of pimecrolimus to prevent epidural fibrosis in a postlaminectomy rat model. *J Neurosurg Spine* 2009;11:758-63.
- Choi HJ, Kim KB, Kwon YM. Effect of amniotic membrane to reduce postlaminectomy epidural adhesion on a rat model. *J Korean Neurosurg Soc* 2011;49:323-8.
- Ismailoglu O, Albayrak B, Gulsen I, Tanriover G, Demir N. Topical application of tacrolimus prevents epidural fibrosis in a rat postlaminectomy model: histopathological and ultrastructural analysis. *Turk Neurosurg* 2011;21:630-3.
- Kasimcan MO, Bakar B, Aktaş S, Alhan A, Yilmaz M. Effectiveness of the biophysical barriers on the peridural fibrosis of a postlaminectomy rat model: an experimental research. *Injury* 2011;42:778-81.
- Cruccu G, Aziz TZ, Garcia-Larrea L, Hansson P, Jensen TS, Lefaucheur JP, et al. EFNS guidelines on neurostimulation therapy for neuropathic pain. *Eur J Neurol* 2007;14:952-70.
- Carter EL. Antibiotics in cutaneous medicine: an update. *Semin Cutan Med Surg* 2003;22:196-211.
- Jallouli M, Hakim A, Znazen A, Sahnoun Z, Kallel H, Zghal K, et al. Rifamycin lavage in the treatment of experimental intra-abdominal infection. *J Surg Res* 2009;155:191-4.
- Benfer J, Struck H. The effect of rifamycin SV on the wound-healing process. *Arzneimittelforschung* 1976;26:1361-4.
- Gurel MS, Naycı S, Turgut AV, Bozkurt ER. Comparison of the effects of topical fusidic acid and rifamycin on wound healing in rats. *Int Wound J* 2015;12:106-10.
- He Y, Revel M, Loty B. A quantitative model of post-laminectomy scar formation. Effects of a nonsteroidal anti-inflammatory drug. *Spine (Phila Pa 1976)* 1995;20:557-63.
- Turkoglu E, Dinc C, Tuncer C, Oktay M, Serbes G, Sekerci Z. Use of decorin to prevent epidural fibrosis in a post-laminectomy rat model. *Eur J Pharmacol* 2014;724:86-91.
- Andrychowski J, Frontczak-Baniewicz M, Sulejczak D, Kowalczyk T, Chmielewski T, Czernicki Z, et al. Nanofiber nets in prevention of cicatrization in spinal procedures. Experimental study. *Folia Neuropathol* 2013;51:147-57.
- Benoist M, Ficat C, Baraf P, Cauchoix J. Postoperative lumbar epiduro-arachnoiditis. Diagnostic and therapeutic aspects. *Spine (Phila Pa 1976)* 1980;5:432-6.
- Temel SG, Ozturk C, Temiz A, Ersozlu S, Aydinli U. A new material for prevention of epidural fibrosis after laminectomy: oxidized regenerated cellulose (interceed), an absorbable barrier. *J Spinal Disord Tech* 2006;19:270-5.
- Burton CV, Kirkaldy-Willis WH, Yong-Hing K, Heithoff KB. Causes of failure of surgery on the lumbar spine. *Clin Orthop Relat Res* 1981;157:191-9.
- Finnegan WJ, Fenlin JM, Marvel JP, Nardini RJ, Rothman RH. Results of surgical intervention in the symptomatic multiply-operated back patient. Analysis of sixty-seven cases followed for three to seven years. *J Bone Joint Surg [Am]* 1979;61:1077-82.
- Law JD, Lehman RA, Kirsch WM. Reoperation after lumbar intervertebral disc surgery. *J Neurosurg* 1978;48:259-63.
- Key JA, Ford LT. Experimental intervertebral-disc lesions. *J Bone Joint Surg [Am]* 1948;30A:621-30.
- Barberá J, Gonzalez J, Esquerdo J, Broseta J, Barcia-Salorio JL. Prophylaxis of the laminectomy membrane. An experimental study in dogs. *J Neurosurg* 1978;49:419-24.
- Gill GG, Scheck M, Kelley ET, Rodrigo JJ. Pedicle fat grafts for the prevention of scar in low-back surgery. A preliminary report on the first 92 cases. *Spine (Phila Pa 1976)* 1985;10:662-7.
- Lee HM, Yang KH, Han DY, Kim NH. An experimental study on prevention of postlaminectomy scar formation. *Yonsei Med J* 1990;31:359-66.
- Sandoval MA, Hernandez-Vaquero D. Preventing peridural fibrosis with nonsteroidal anti-inflammatory drugs. *Eur Spine J* 2008;17:451-5.
- Xu J, Chen Y, Yue Y, Sun J, Cui L. Reconstruction of epidural fat with engineered adipose tissue from adipose derived stem cells and PLGA in the rabbit dorsal laminectomy model. *Biomaterials* 2012;33:6965-73.
- Yang J, Ni B, Liu J, Zhu L, Zhou W. Application of liposome-encapsulated hydroxycamptothecin in the prevention of epidural scar formation in New Zealand white rabbits. *Spine J* 2011;11:218-23.
- Chang BS, Brown PR, Sieber A, Valdevit A, Tateno K, Kostuik JP. Evaluation of the biological response of wear debris. *Spine J* 2004;4:239-44.
- Coskun E, Süzer T, Topuz O, Zencir M, Pakdemirli E, Tahta K. Relationships between epidural fibrosis, pain, disability, and psychological factors after lumbar disc surgery. *Eur Spine J* 2000;9:218-23.
- LaRocca H, Macnab I. The laminectomy membrane. Studies in its evolution, characteristics, effects and prophylaxis in dogs. *J Bone Joint Surg [Br]* 1974;56:545-50.
- Aygün F, Kuzgun A, Ulucan S, Keser A, Akpek M, Kaya M. The protective effect of topical rifamycin treatment against sternal wound infection in diabetic patients undergoing on-pump coronary artery bypass graft surgery. *Cardiovasc J Afr* 2014;25:96-9.
- Caruso I. Twenty years of experience with intra-articular rifamycin for chronic arthritides. *J Int Med Res* 1997;25:307-17.
- Gionchetti P, Rizzello F, Venturi A, Ugolini F, Rossi M, Brigidi P, et al. Review--antibiotic treatment in inflammatory bowel disease: rifaximin, a new possible approach. *Eur Rev Med Pharmacol Sci* 1999;3:27-30.

33. Rosette C, Buendia-Laysa F Jr, Patkar S, Moro L, Celasco G, Bozzella R, et al. Anti-inflammatory and immunomodulatory activities of rifamycin SV. *Int J Antimicrob Agents* 2013;42:182-6.
34. Sartor RB. Review article: the potential mechanisms of action of rifaximin in the management of inflammatory bowel diseases. *Aliment Pharmacol Ther* 2016;43:27-36.
35. Kizilay Z, Cetin NK, İsmailoglu Ö, Yılmaz A, Omurlu İK, Coskun ME, et al. The Effects of Rifampin, Povidone-Iodine and Hydrogen Peroxide on the Formation of Epidural Fibrosis in the Experimental Epidural Fibrosis Model. *Inflammation* 2016;39:1495-502.

Copyright of Turkish Journal of Physical Medicine & Rehabilitation (2587-0823) is the property of Turkish Society of Physical Medicine & Rehabilitation and its content may not be copied or emailed to multiple sites or posted to a listserv without the copyright holder's express written permission. However, users may print, download, or email articles for individual use.