

Current Therapies for Pulmonary Hydatid Cyst and its Complications

Akciğer Hidatik Kistin Güncel Tedavisi ve Komplikasyonları

Ali Kılıçgün, Suat Gezer*

Abant İzzet Baysal Üniversitesi Tıp Fakültesi, Göğüs Cerrahisi Anabilim Dalı, Bolu, Türkiye

*Düzce Üniversitesi Tıp Fakültesi, Göğüs Cerrahisi Anabilim Dalı, Düzce, Türkiye

Abstract

Aim: In this study, we aimed to investigate the first presenting complaints and operative results of patients who were operated for lung hydatid cyst and to determine the rate of co-existing liver hydatid cysts.

Methods: Seventy patients who had been operated for lung hydatid cyst between 2004 and 2008 were included in the study. Clinical, radiological and surgical data of these patients were evaluated retrospectively.

Results: The cyst(s) were perforated in 30 patients and were intact in 40 patients. They were right-sided in 35 patients, left-sided in 29, and bilateral lung cysts in three patients. Of the patients, 49 (70%) had undergone cystotomy and capitonage, seven patients-cystotomy, and two patients had undergone wedge resection. Of the perforated cysts, 23% presented with clinical and radiological findings of pneumothorax. Complications were observed in nine patients and the most common complication was atelectasis.

Conclusion: Parenchyma-sparing surgery is a safe and effective treatment modality for lung hydatid cysts. Accompanying liver dome cysts can be intervened at the same session. The rate of cases with perforated cysts presenting to emergency clinics with findings of pneumothorax should not be overlooked. (*The Medical Bulletin of Haseki 2011; 49: 105-9*)

Key Words: Pulmonary hydatid cyst, pneumothorax, lung surgery

Özet

Amaç: Bu çalışmada, akciğer hidatik kisti tanısıyla cerrahi tedavi uygulanan hastaların ilk başvuru şikayetlerinin ve ameliyat sonuçlarının irdelenmesi ve ayrıca karaciğer hidatik kist oranının belirlenmesi amaçlanmıştır.

Yöntemler: Çalışmaya, 2004-2008 yılları arasında akciğer hidatik kisti tanısı ile opere edilen toplam 70 hasta dahil edildi. Bu hastaların klinik, radyolojik ve cerrahi tedavi ile ilgili özellikleri retrospektif olarak değerlendirildi.

Bulgular: Hastaların 30'unda kist/kistler perforate, 40 hastada intakt idi. 70 hastanın 35'i sağ 29'u sol da yerleşimli üç hastada ise bilateral akciğer kisti bulunmaktaydı. Hastaların 49'una kistektomi ve kapitonaj (%70) operasyonu uygulanırken, yedi hastaya kistektomi iki hastaya ise wedge rezeksiyon uygulandı. Perfore kistlerin %23'ü (7 hasta) hastaneye klinik ve radyolojik olarak pnömotoraks/hidropnömotoraks bulgularıyla başvurdu. Hastaların dokuzunda komplikasyon gelişirken en sık görülen komplikasyon atelettazi idi.

Sonuç: Akciğer kist hidatiğinin güncel tedavisinde parankim koruyucu cerrahi yaklaşım etkili ve güvenilir bir tedavi seçeneğidir. Eşlik eden karaciğer kubbe kistlerine aynı seansta müdahale edilebilmektedir. Perfore kistlerin pnömotoraks bulgularıyla acil kliniklere başvurabilecekleri akılda tutulmalıdır. (*Haseki Tıp Bülteni 2011; 49: 105-9*)

Anahtar Kelimeler: Akciğer kist hidatik, pnömotoraks, akciğer cerrahisi

Introduction

Hydatidosis is a common disease resulting from infection by the parasite "Echinococcus granulosus". It is frequent on the Mediterranean coast, in South America, Australia, New Zealand, Asia and Africa, where commercial livestock farming is widespread (1,2). The most common site of involvement is the liver, followed by the lungs. The rate of co-existence of lung and liver cysts

is 4-25% (3,4). The treatment for pulmonary hydatid cyst is surgical and accompanying liver cysts can be managed through a transdiaphragmatic (phrenotomy) approach in the same session (1,5). Perforated cysts can present to the emergency room with clinical findings of pneumothorax/hydro-pneumothorax (6). The aim of our study was to present the results of current parenchyma-sparing surgical treatment of pulmonary hydatid cysts with its complications.

Sunulduğu Kongre: Türk Toraks Derneği 11. Yıllık Kongresi, Antalya, 23-27 Nisan 2008

Address for Correspondence/Yazışma Adresi: Ali Kılıçgün

Abant İzzet Baysal Üniversitesi Tıp Fakültesi, Göğüs Cerrahisi Anabilim Dalı, Bolu, Türkiye

Tel.: +09 374 253 46 56 E-mail: alikilicgun@mynet.com

Geliş Tarihi/Received: 15 Mart 2011 Kabul Tarihi/Accepted: 06 Haziran 2011

Haseki Tıp Bülteni,
Galenos Yayınevi tarafından basılmıştır.

The Medical Bulletin of Haseki Training and Research Hospital,
published by Galenos Publishing.

Methods

Seventy-four operations were performed on 70 patients with pulmonary and/or liver hydatid cysts from October 2004 to July 2005, and from August 2006 to October 2008 (in 35 months) in our clinic. The complaints, intra-operative findings and complications in the patients were assessed retrospectively. Of the 70 patients, 35 were male and 35 were female (M/F 1:1). The mean age was 25.4 years (range: 2-74 years). The patients were assessed with pre-operative clinical/radiological and laboratory investigations. All the patients underwent imaging with postero-anterior and lateral chest X-rays, thoracic computed tomography and abdominal ultrasonography or abdominal computed tomography and complete blood count/biochemical parameters. The diagnosis was made based on the clinical findings and indirect diagnostic methods (radiological). Indirect hemagglutination test was performed in the suspected cases (Hydatidose®, Fumouze, France). Patients with hemoptysis, suggestive of an endobronchial lesion, underwent fiberoptic bronchoscopy.

The rates of pneumothorax and the presenting complaints in cases with perforated cysts were assessed. Patients with liver cysts underwent consultation with general surgeon when indicated. All removed cysts were examined pathologically.

Surgical technique

All patients underwent double-lumen endotracheal intubation under general anesthesia. Entrance into the thorax in patients that had only lung cysts was made via a posterolateral thoracotomy incision in the fifth intercostal space with the patient in the lateral decubitus position. In patients with accompanying liver cysts, the entrance was

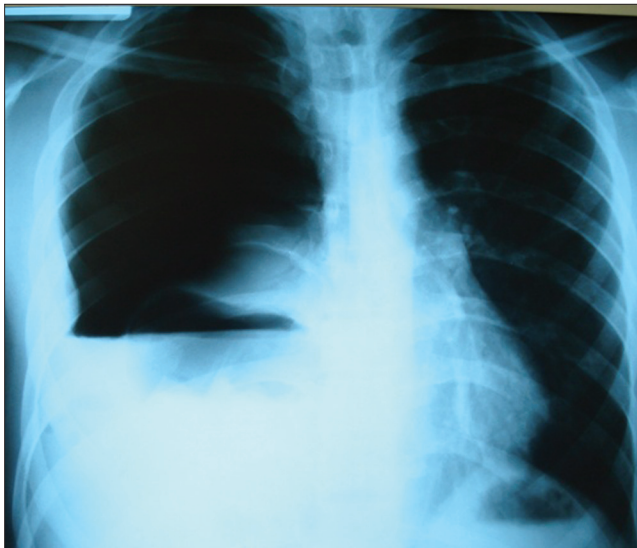

Figure 1. Hydropneumothorax developing after perforation of right hydatid cyst is observed on the postero-anterior chest X-ray.

made through the sixth intercostals space, and in patients with only liver dome cyst, this was made through the seventh intercostal space. Gauze compresses soaked in diluted povidone-iodine were placed onto all lung surfaces and the thoracotomy line, except for the cyst area. To avoid possible contamination to the intact cysts, enucleation was not attempted. First, the cyst fluid was aspirated. The germinative membrane was excised by cystotomy. The inner cavity was irrigated with saline solution and cleaned with gauze compresses soaked in povidone-iodine. The bronchial gaps were closed using 3-0 polyglactin. Capitonage was performed at the cyst area using 3-0 polyglactin. In 15 of the 16 patients with liver cysts, diaphragmatic incision was performed following right thoracotomy and in one patient, following left thoracotomy, and cystotomy was performed for the liver cyst. Following resection of the liver cyst, biliary leakage was checked, a drainage tube was inserted and the diaphragm was sutured using non-absorbable sutures. Two chest tubes, one apical and the other basal, were placed in the thorax after hemostasis and aerostasis.

The patients' gender, age, location, presence of perforation, complaints, cyst size, length of hospital stay, and complications were recorded and retrospectively reviewed. None of the patients had received preoperative medical therapy. All patients were given 10-15mg/kg albendazole for 21 days in three periods, in the absence of postoperative contraindications.

Results

Seventy patients with lung and/or liver hydatid cysts operated in 35 months were included in the study. These 70 patients underwent 74 operations. All operations were performed by two thoracic surgeons. General surgeons were invited when required. The gender distribution of the patients was: 35 males and 35 females, 27 were in the pediatric age group (<16 years) and 43 were adults (>16 years). In 30 (43%) patients out of the 70, the cysts were perforated. The most common symptom was coughing (56%) (Table 1). The seven patients (23%) out of the 30 patients with perforated cysts were those who had presented to the emergency room with clinical findings of pneumothorax or hydro-pneumothorax (Figure 1,2,3). The symptoms in these patients were chest

Table 1. Symptoms and clinical findings of patients at the time of hospital admission

Symptom	N	%
Cough	39	56
Hemoptysis	11	16
Flank pain	8	11
Chest pain of sudden onset,		
Dyspnea and cough	7	10
No symptoms	5	7
Total	70	100

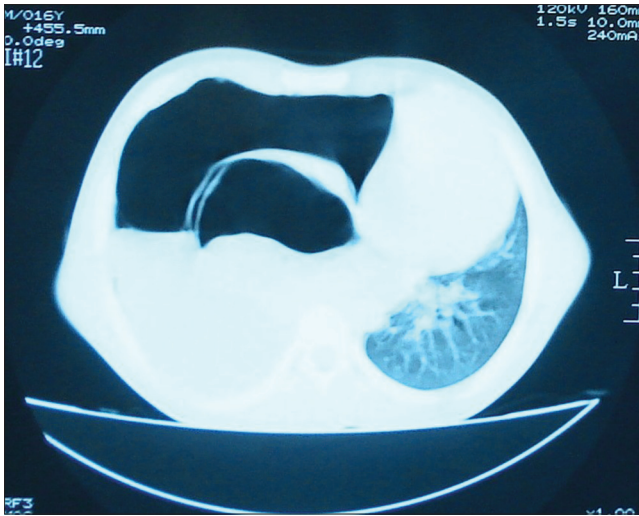

Figure 2. The view of perforated cyst causing right hydropneumothorax on thoracic tomography.

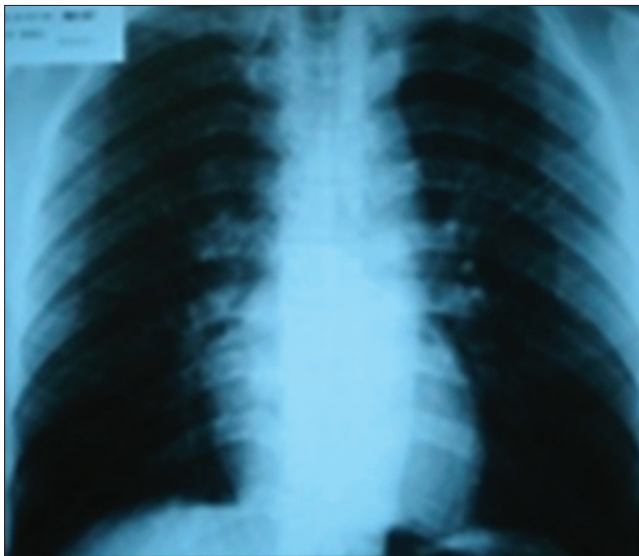


Figure 3. Postoperative chest X-ray of the patient operated for perforated hydatid cyst.

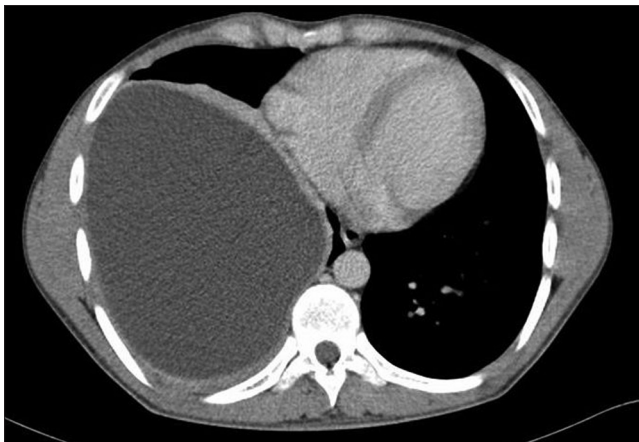


Figure 4. Giant intact hydatid cyst in the right lung.

pain of sudden onset, dyspnea and cough. Eleven patients had presented with hemoptysis, being massive in one case. Hemoptysis was more common in the pediatric age group compared to the adult group. Of the 27 pediatric patients, five had hemoptysis (19%). In the adults, six of the 43 patients had hemoptysis (14%). There were no symptoms in five patients. Two patients were receiving andazole treatment at the time of admission. One of these had presented to the hospital with the complaint of hemoptysis.

Twenty patients (17%) had accompanying liver cysts. The cysts were in the right lung in 35 patients (right lung: n=24; right lung+liver: n=11) and in the left lung, in 29 patients (left lung: n=28; left lung+liver: n=1). There were bilateral lung cysts in three patients. Presence of cysts in the liver dome with no cyst in the lungs was observed in four patients (Table 2). One of the cysts located in the right hemithorax was in the chest wall, one was with intrathoracic extrapleural location, and in one patient, the cyst was in the pleural space. The cysts located in the lungs were frequently in the right and left lower lobes (Figure 4). Twenty-two patients (31.4%) had cysts in the right lower lobe and 21 patients (30%) - in the left lower lobe (Table 2). The total number of cysts in 70 patients was 92. The mean cyst diameter was 6.9 cm (range: 2-20 cm). The mean length of postoperative hospital stay was 6.9 days (range: 3-16 days).

Mortality was not seen in any of the patients. There were complications in nine patients (13%). Five patients developed atelectasis and were intervened by fiberoptic/rigid bronchoscopy when required. The other complications were fever, expansion failure, prolonged air leak and hemoptysis (Table 4).

Table 2. The localization of cysts

Localization of cysts	n
Right lung	21
Right lung+liver	11
Left lung	28
Left lung+liver	1
Bilateral lung	3
Chest wall (extrathoracic)	1
Extrapleural (intrathoracic)	1
Pleural space	1
Only liver	4

Table 3. Operations performed

Surgical procedure	n	%
Cystotomy+capitonage	49	66
Cystotomy+capitonage+phrenotomy	12	16
Cystotomy	7	9
Thoracotomy+phrenotomy	4	6
Wedge resection	2	3
Total	74	100

Table 4. Postoperative complications

Complications	n	%
Atelectasis	5	7.2
Fever	1	1.4
Expansion failure	1	1.4
Hemoptysis	1	1.4
Prolonged air leakage	1	1.4
Total	9	12.8

The most common operation was cystotomy and capitonage (49 patients, 70%) (Table 3). Cystotomy+capitonage and additional transdiaphragmatic liver cystotomy were performed on 12 patients. Seven patients underwent cystotomy only, without capitonage. Only wedge resection was performed in two small cysts with peripheral location. Transdiaphragmatic intervention was performed through a right thoracotomy in four patients only with liver dome cyst and without lung cysts. No patients required anatomic lung resection. Three patients with bilateral lung cysts were operated in the same session using bilateral thoracotomy. All surgical procedures were performed by two surgeons. The patients were generally followed up in the intensive care unit for one day postoperatively. The drains were removed in patients with no air leak and with a drainage volume of <100ml when the lungs were seen as expanded on the chest X-ray. All removed cysts were examined pathologically.

All patients were given 10-15mg/kg albendazole for 21 days in three periods, when not contraindicated postoperatively. During the treatment, liver enzyme levels (ALT, AST, and GGT) were followed. The medication was ceased in patients with elevated liver enzymes. All patients were periodically followed up - once every three months in the first year and once every six months in the following years.

Discussion

The primary treatment for lung hydatid cyst is surgical. Medical treatment should be preferred in patients who cannot undergo surgery and in patients with recurrence or multiple cysts. Cystotomy alone or cystotomy and capitonage operations are methods of choice for achieving optimal parenchymal preservation. Anatomic resections such as pneumonectomy, lobectomy and segmentectomy are usually avoided (7). Kavukcu et al. (7) performed 1118 operations in 1032 patients with lung hydatid cyst and none of the patients required anatomic lung resection. No anatomic resection was required in our series and parenchyma-preserving techniques such as cystotomy and capitonage were preferred. Wedge resection was performed for the two cysts with peripheral localization.

Pericystectomy was first recommended by Perez-Fontana (1951); however, it has no advantage in surgery.

The closure of the space caused by the evacuated cyst in a way that would provide complete obliteration will prevent the probability of any air leakage and/or infection. This method may cause hemorrhage; it is performed by a small number of surgeons and is not generally recommended today (1). Capitonage is a procedure depending on the preference of the surgeon. Turna et al. (8) found no difference in the rates of complication, hospital or intensive care unit length of stay between patients with and without capitonage in their retrospective analysis. If capitonage is considered a time-consuming procedure, then it may not be performed. However, each surgeon prefers the method with which he is best familiar as there is no evidence of any strong recommendations for the use of these two methods (8). In our study, seven patients underwent cystotomy without capitonage and two patients had wedge resection; the other patients (61 patients) underwent capitonage. The patients that did not undergo capitonage were those with cysts located peripherally and/or those with cysts located in the lung zones across the mediastinum.

Although the standard treatment of pulmonary hydatid cyst is surgery, some other interventional treatments have been reported. One of these treatments is the evacuation of the cyst with the help of a transthoracic catheter and then injection of a scolocidal substance inside. However, this treatment modality may be preferred only in patients who cannot tolerate surgery and in patients with accompanying infective clinical picture (obstructive pneumonia, empyema, etc.) in spite of the medical treatment (9).

The probability of co-existence of lung and liver hydatid cysts is between 4% and 25% (4). In patients with co-existing lung and liver hydatid cysts, first the lung cyst is removed using thoracotomy followed by liver cyst operation through a phrenotomy, if it is possible to remove the liver cyst through a transdiaphragmatic approach (1,3,5). After cystectomy is performed for the liver cyst, it should be irrigated with hydrogen peroxide and/or povidone-iodine and a separate drain should be placed (5). Aghajanzadeh et al. (4) found accompanying liver cysts in 30 out of 152 patients with lung cysts. They reported that the treatment of lung and liver cysts in the same session through a posterolateral thoracotomy was effective, safe and with little complication (4). The number of patients with co-existing lung and liver cysts in our study was 12. There were liver cysts without lung cysts in four patients. The rate of co-existence of lung and liver cysts in our series was 17%. Liver cysts were operated through a transdiaphragmatic approach in the same session.

Bilateral lung cysts can be treated by bilateral sequential thoracotomies and by median sternotomy in the same session (1,10). It is difficult to reach cysts in the posterior segment of the lower lobe and to perform appropriate

surgical procedure by sternotomy. Therefore, treatment with sequential thoracotomy in case of bilateral cysts is the method which has been more frequently recommended (1). If the cyst in one side or both sides is intact, the side with the larger cyst should be operated first (1). There were bilateral lung cysts in two patients and the cysts were intact and large (>10cm). Thus, these two patients were operated in the same session through bilateral thoracotomies. Neither patient developed any complications.

Complications such as spontaneous pneumothorax, empyema, pleural thickening, hepatopleural fistula, pericarditis, and hepatobronchial fistula may develop after rupture of the pulmonary hydatid cyst into the pleura (6). The ruptured cysts may lead to a misdiagnosis with the complications they cause. They can be confused with other lung diseases such as pneumonia, tuberculosis, tumor, pleurisy, and pneumothorax (11). In our study, 23.3% of the cases with perforated cysts presented to the emergency department with clinical findings of pneumothorax/hydropneumothorax. These patients had symptoms of sudden-onset chest pain, dyspnea and cough. These findings were present in seven out of 30 patients with perforated hydatid cyst. It should not be overlooked that perforated pulmonary hydatid cyst cases may present to hospital with clinical findings of pneumothorax/hydro-pneumothorax, and the diagnosis of pulmonary hydatid cyst should be kept in mind.

The treatment of lung hydatid cysts is surgical with low morbidity and mortality rates. Accompanying liver dome cysts may be managed in the same session. The rate of emergency department admissions of cases with perforated cysts presenting with clinical findings of pneumothorax/hydro-pneumothorax should not be overlooked.

Kaynaklar

1. Harlaftis NN, Aletras HA, Panagiotis NS. Hydatid disease of the lung. In: Shields TW, Locicero J, Ponn RB, Rush VW, eds. *General Thoracic Surgery*. Philadelphia: Lippincott Williams and Wilkins, 2005;1298-308.
2. Dogan R, Yuksel M, Cetin G, et al. Surgical treatment of hydatid cysts of the lung: report of 1055 patients. *Thorax* 1989;44:192-9.
3. Sahin E, Enon S, Cangir AK, et al. Single-stage transthoracic approach for right lung and liver hydatid disease. *J Thorac Cardiovasc Surg* 2003;126:769-73.
4. Aghajanzadeh M, Safarpour F, Amani H, Alavi A. One-stage procedure for lung and liver hydatid cysts. *Asian Cardiovasc Thorac Ann* 2008;16:392-5.
5. Freixinet JL, Mestres CA, Cugat E, et al. Hepaticothoracic transdiaphragmatic echinococcosis. *Ann Thorac Surg* 1988;45:426-9.
6. Aribas OK, Kanat F, Gormus N, Turk E. Pleural complications of hydatid disease. *J Thorac Cardiovasc Surg* 2002;123:492-7.
7. Kavukcu S, Kilic D, Tokat AO, et al. Parenchyma-preserving surgery in the management of pulmonary hydatid cysts. *J Invest Surg* 2006;19:61-8.
8. Turna A, Yilmaz MA, Hacıbrahimoglu G, Kutlu CA, Bedirhan MA. Surgical treatment of pulmonary hydatid cysts: is capitonnage necessary? *Ann Thorac Surg* 2002;74:191-5.
9. Mawhorter S, Temeck B, Cheng R, Pass H, Nash T. Nonsurgical therapy for pulmonary hydatid cyst disease. *Chest* 1997;112:1432-6.
10. Cetin G, Dogan R, Yuksel M, et al. Surgical treatment of bilateral hydatid disease of the lung via median sternotomy. Experience in 60 consecutive patients. *Thorac Cardiovasc Surg* 1988;36:114-7.
11. Zhang Q, Huang TM, Li BZ, Li ZL, Liao KX. Misdiagnosis of pulmonary hydatid cyst rupture. *Zhonghua Jie He He Hu Xi Za Zhi* 2003;26:474-6.