

**CASE  
REPORT**

**Mehmet Emin Gonullu<sup>1</sup>**  
**Ismet Ozaydin<sup>1</sup>**  
**Hasan Can Demirkaya<sup>1</sup>**  
**Nurgül Altınsoy<sup>1</sup>**

<sup>1</sup> Düzce University Medical Faculty  
Department of General Surgery,  
Düzce, Türkiye

**Corresponding Author:**  
*Mehmet Emin Gönüllü*  
mail: [dr.m.emin.gonullu@gmail.com](mailto:dr.m.emin.gonullu@gmail.com)

Received: 31.10.2022  
Acceptance: 01.12.2022  
DOI: 10.18521/ktd.1202200

**Konuralp Medical Journal**  
e-ISSN1309-3878  
[konuralptipdergi@duzce.edu.tr](mailto:konuralptipdergi@duzce.edu.tr)  
[konuralptipdergisi@gmail.com](mailto:konuralptipdergisi@gmail.com)  
[www.konuralptipdergi.duzce.edu.tr](http://www.konuralptipdergi.duzce.edu.tr)

## Emergency Surgery due to Giant Diaphragm Hernia Causing Acute Abdominal and Dyspnea: A Case Report

### ABSTRACT

A 78-year-old female patient was admitted to the emergency department with severe abdominal pain and respiratory distress. In the Computer Tomography (CT) examination of the patient; It was observed that there was a hernia in the left leaf of the diaphragm and the stomach, spleen and intestines were protruding in the left pleural space up to the left clavicle. In the patient's anamnesis; there was breathing difficulty that has been going on for many years and has increased in recent days and the general condition disorder that has developed recently. A giant left diaphragmatic hernia was observed in our patient, who was urgently scheduled for diagnostic dslaparotomy. The spleen, stomach and intestines in the left pleural cavity were taken into the abdomen and the diaphragm defect was repaired.

**Keywords:** Atraumatic Diaphragmatic Hernia, Acute Abdominal, Dyspnea

## Akut Batın ve Dispneye Neden Olan Dev Diyafram Fıtığına Bağlı Acil Cerrahi: Olgu Sunumu

### ÖZET

78 yaşında kadın hasta şiddetli karın ağrısı ve solunum sıkıntısı ile acil servise başvurdu. Hastanın Bilgisayarlı Tomografi (BT) incelemesinde; Diyaframın sol yaprağında fıtık olduğu, sol plevral boşlukta sol klavikulaya kadar mide, dalak ve bağırsakların çıkıntı yaptığı görüldü. Hastanın anamnezinde; uzun yıllardır devam eden ve son günlerde artan nefes alma güçlüğü ve son zamanlarda gelişen genel durum bozukluğu vardı. Acilen tanısız laparotomi planlanan hastamızda dev bir sol diyafragma hernisi görüldü. Sol plevral boşluktaki dalak, mide ve bağırsaklar karın içine alınarak diyafram defekti onarıldı.

**Anahtar Kelimeler:** Atravmatik Diyafram Fıtığı, Akut Abdominal, Dispne

## INTRODUCTION

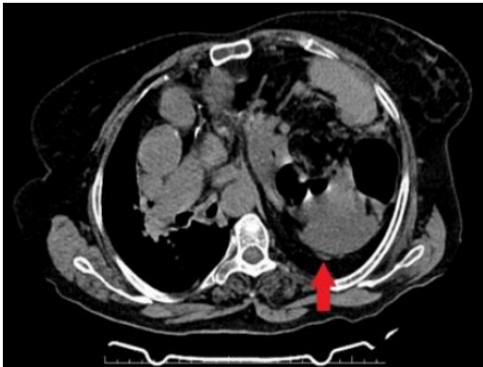
Most congenital diaphragmatic hernias develop from the left posterolateral foramen and are defined as Bochdalek hernias. Morgagni hernia is a congenital defect that occurs due to the failure of the sternal and costal elements of the diaphragmatic crurae from the Larrey space and has been reported as 5% in large series(1). Clinical presentation ranges from asymptomatic cases to serious respiratory or gastrointestinal symptoms and sometimes haemodynamic instability (2). The most common contents of the hernia sac include the omentum, followed by the colon, small bowel, stomach, spleen and portions of the liver (3). The present case is a rare case of an adult with Diaphragm Hernia presenting with abdominal pain, dyspnea and synchronous prolapse of the spleen, stomach, small intestine and colon.

## CASE REPORT

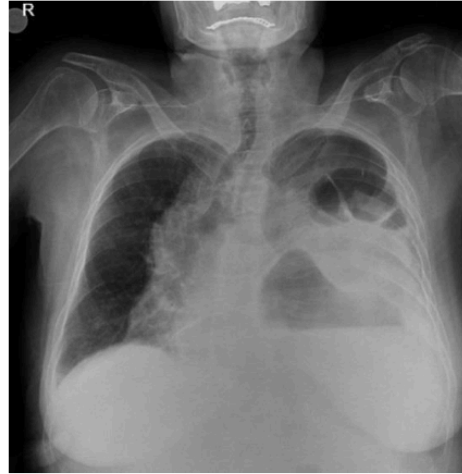A 78-year-old male patient was referred to our hospital from a secondary healthcare facility with a pre-diagnosis of strangulated diaphragmatic hernia. In the anamnesis of the patient; it was learned that they applied to the hospital because of the complaints of shortness of breath for fifteen days, increasing their complaints with each passing day and having a general deterioration. There was no history of trauma. Her medical history was unremarkable except for recurrent asthma attacks and heart failure for many years.

Her physical examination was conscious-open and cooperative-orientated. Vital findings were Tension Arterial: 110/75 mmHg, Fever: 37.0 oC, Pulse: 103/min-rhythmic, Respiratory Rate: 25/min-regular, Oxygen Saturation: 91%. In the examination of the abdomen; especially prevalent mainly in the upper quadrant taken tenderness.

When the Computer Tomography (CT) taken in a secondary health institution was examined, It was seen that the spleen and intestines were in the left hemithorax. (Figure 1) Intestinal air is seen in the left hemithorax in the preop chest x-ray taken in our hospital. (Figure 2).



**Figure 1.** Spleen and intestines seen in the left hemithorax.

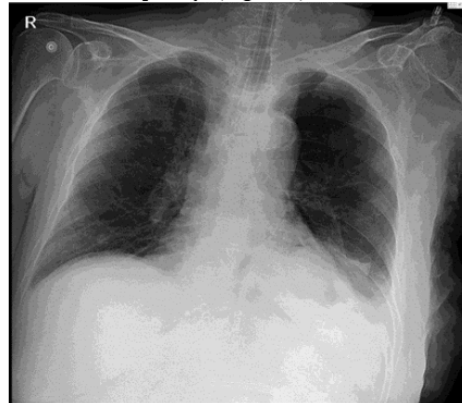


**Figure 2.** Intestinal air is seen in the left hemithorax.

In our patient's laboratory examination, a slight neutrophil increase ( $7.8 \cdot 10^3/uL$ ) and CRP increase (3.3 mg/dL) were observed in the hemogram. Apart from these, we look at the biochemical and hematological parameters were normal.

After that, the patient was operated and diagnostic laparotomy was performed under general anesthesia. In the exploration, it was seen that there was a large defect in the left diaphragm and the intestines and spleen penetrated from this defect. Intestines and spleen were seen in the left hemithorax up to the left clavicle. After the spleen was withdrawn into the abdomen, bleeding was observed in its capsule, and the decision to splenectomy was made because the bleeding did not stop. The intestines were pulled into the abdomen after the splenectomy was completed. Afterwards, a 10x15cm prolene mesh was sutured to the diaphragm one by one using 2-0 prolene and the defect was closed.

In the chest x-ray taken on the postoperative first day, it was seen that the left lung was ventilated completely. (Figure 3)



**Figure 3.** Chest x-ray taken on postop 1st day.

## DISCUSSION

Morgagni hernia in adults is more common in women. In a study of 298 patients, 63% of the patients were found to be women. Symptoms were detected with hernia in 72% of the patients. It was observed that male patients complained of symptoms related to hernia more and earlier than female patients (4).

Diaphragm Hernia usually constitute only the omentum in infants and children, but with time, the defect enlarges until the abdominal organs herniate through. Pregnancy, trauma, obesity, chronic constipation, and chronic cough are common predisposing conditions contributing to the development of Diaphragm Hernia. Symptomatic patients frequently complain of abdominal or chest pain and respiratory distress (3). In our patient, the diaphragmatic hernia expanded and turned into a giant, possibly due to increased intra-abdominal pressure due to asthma attacks. As a result, the patient appeared with severe dyspnea and abdominal pain symptoms.

Morgagni hernia can be repaired with thoracic and abdominal access. Abdominal approach is preferred more than thoracic approach. In addition to open surgery in the transabdominal approach, laparoscopic surgeries have been successfully performed for many years (4). Although we have laparoscopic experience in our clinic on behalf of diaphragmatic hernias, the operation that started laparoscopically continued as open surgery because the patient had a giant hernia

and the spleen and intestines were not reduced into the abdomen.

Although there are limited studies in the literature on mesh or meshless repair of diaphragm defect, the general opinion is that recurrence is less in mesh repair (5). While the literature review suggested repairing the defect using a mesh, some preferred suture repair. The choice of repair depends on the size of the defect, as larger defects will usually not be able to be repaired by suture (6). In our case, the defect was repaired with prolene mesh, considering the presence of a giant diaphragmatic hernia and the absence of recurrence.

## RESULT

When symptoms suggestive of gastrointestinal obstruction are encountered with respiratory distress, diaphragmatic hernia should be included in the differential diagnosis. In such cases, a chest X-ray or a CT to be seen more clearly may be ordered to support the diagnosis. As in our case, it should not be delayed in the emergency operation of a giant diaphragmatic hernia that gives symptoms. But more importantly, it should be kept in mind that the operation of asymptomatic diaphragmatic hernias detected incidentally will prevent possible complications. In addition, we think that repairing the defect with mesh has an important role in terms of recurrence.

Written informed consent form was obtained from the patient. The authors declare that there is no conflict of interest.

## REFERENCES

1. Hüseyin O, Eyüp S.U, Erdem S, Öztekin O. Erişkin Morgagni Hernisinde Transtorasik Yaklaşım. *Toraks Dergisi*. 2000;1:79-81.
2. Mario T, Antonia G, Roberta M.I, Angela D.P, Giovanni C, Angela P, Angela G. Emergency surgery due to diaphragmatic hernia: case series and review. *World Journal of Emergency Surgery*. 2017;12:23.
3. Seok Y.L, Jung N.K, Yong S.K, Keun Y.K. Strangulated Morgagni hernia in an adult: Synchronous prolapse of the liver and transverse colon. *Ulus Travma Acil Cerrahi Derg*. 2018;24(4):376-8.
4. Bekir S, İhsan Y, Yavuz S.K. İnkarsere Dev Morgagni Hernisi: Olgu Sunumu. *Bozok Tıp Derg*. 2018;8(4):158-61.
5. Bekir S, Rıdvar T. Laparoskopik Travmatik Diyafragma Hernisi Onarımı. *Med J SDU/SDÜ Tıp Fak Derg*. 2018;25(1):112-6.
6. Kasra R, Duncan L, Liam H. Emergency repair of Morgagni hernia with partialgastric volvulus: our approach. *Journal of Surgical Case Reports*. 2016;8:1–3.