

A Psoralen and Ultraviolet A-Aggravated Dermatitis: Grover's Disease

Emin Ozlu, Ayse Serap Karadag¹, Tugba Kevser Uzuncakmak¹, Seyma Ozkanli², Aysegul Erdem², Necmettin Akdeniz¹

Department of Dermatology, Duzce University School of Medicine, Duzce, Departments of ¹Dermatology and ²Pathology, Istanbul Medeniyet University, Istanbul, Turkey

Abstract

Grover's disease (GD) is an acquired dermatosis called transient acantholytic dermatosis. The exact cause is unknown, but the factors blamed for the etiology include ultraviolet (UV), sweating, temperature rise, radiation, medications, and malignancies. Topical corticosteroids, topical retinoids, and topical calcipotriol are usually sufficient for treatment, and systemic retinoids, systemic steroids, phototherapy, and methotrexate are rarely used. The current report describes the case of GD in a female patient, which was aggravated by the psoralen and UVA phototherapy.

Keywords: Grover's disease, phototherapy, treatment

INTRODUCTION

Grover's disease (GD) is a pruritic, papular, or papulovesicular dermatosis which is histopathologically characterized by acantholysis and dyskeratosis. It often shows spontaneous regression within weeks or months, although it may sometimes have a course with relapses and remissions.^[1] The etiology and pathogenesis of this condition are still unclear; however, the disease has been associated with triggering factors, including high body temperature, sweating, acute ultraviolet (UV) exposure, drug use, and internal malignancies.^[1,2] Topical treatment involves corticosteroids, calcipotriol and retinoids, and systemic treatment involves the use of vitamin A, synthetic retinoids, corticosteroids, methotrexate, and photo (chemo) therapy.^[1] GD is one of the skin conditions, which is sometimes aggravated by the UV light exposure.^[3]

CASE REPORT

A 76-year-old female patient presented at our clinic with itchy lesions located under both breasts and in the lumbar region. These lesions were present for 2 years with exacerbation occurring in the summer season. The dermatological examination revealed erythematous, red-brown, papulovesicular lesions under both

breasts and in the lumbar region [Figure 1a and b]. The patient's systemic examination and laboratory tests were unremarkable. Histopathological evaluation of the biopsy specimen taken from the lesion revealed hyperkeratosis, acanthosis, spongiosis, suprabasal acantholysis, superficial dermal edema, perivascular neutrophilic, and eosinophilic inflammatory cell infiltrate [Figure 2]. The direct immunofluorescence examination did not reveal any particular findings. With the existing findings, the patient was diagnosed with GD. Topical clobetasol propionate 0.05% and topical calcipotriol cream were initiated. In the 3rd month of this treatment, no remission was detected and topical pimecrolimus 1% was initiated, but she could not use this therapy because of irritation. We started oral methylprednisolone 0.5 mg/kg/day but no remission was detected after 2 months of therapy. Thereafter, oral acitretin 0.5 mg/kg/day therapy was initiated. However, no remission was detected with oral acitretin therapy after 3 months. Thereafter, psoralen and UVA (PUVA) phototherapy three times weekly was initiated. Oral 8-methoxalene was given 0.5 mg/kg, 2 h before PUVA treatment. The initial

Address for correspondence: Dr. Emin Ozlu,
Department of Dermatology, Duzce University Faculty of Medicine,
Duzce, Turkey.
E-mail: dermatolog@gmail.com

Submission: 20-12-2019

Revision: 30-12-2019

Acceptance: 01-01-2020

Web Publication: ***

Access this article online

Quick Response Code:



Website:
www.tjdonline.org

DOI:
10.4103/TJD.TJD_45_19

This is an open access journal, and articles are distributed under the terms of the Creative Commons Attribution-NonCommercial-ShareAlike 4.0 License, which allows others to remix, tweak, and build upon the work non-commercially, as long as appropriate credit is given and the new creations are licensed under the identical terms.

For reprints contact: reprints@medknow.com

How to cite this article: Ozlu E, Karadag AS, Uzuncakmak TK, Ozkanli S, Erdem A, Akdeniz N. A psoralen and ultraviolet A-aggravated dermatosis: Grover's disease. Turk J Dermatol 2020;XX:XX-XX.

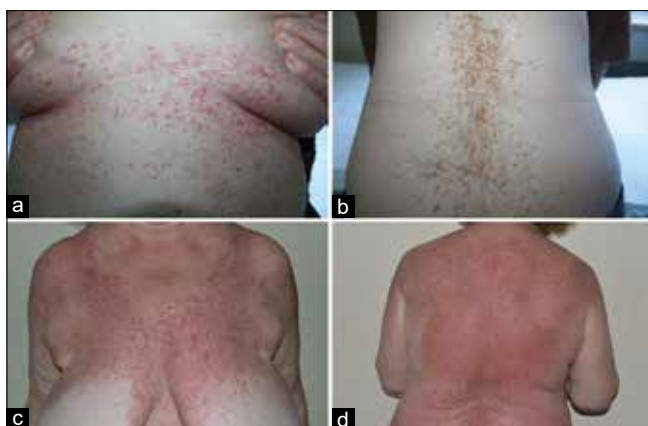

Figure 1: Erythematous, red-brown papulovesicular lesions under both breasts (a) and lumbar region (b). Generalized erythema and had aggravation of lesions on the chest (c) and back (d)

doses were applied 0.5 joule/cm². The patient developed generalized erythema and had aggravation of lesions after five sessions of PUVA phototherapy; therefore, the treatment was discontinued [Figure 1c and d].

DISCUSSION

GD is often a benign, self-limiting disease; however, it may sometimes occur as a resistant and difficult to control dermatosis.^[4] The etiology of the disease is unknown, although several factors have been proposed to be associated with the disease, including the UV exposure, exposure to extreme temperature, and sweating.^[5] The distribution of the skin lesions and seasonal variations highlight the importance of the UV exposure, although rare occurrence of this condition suggests that other structural and environmental factors may play a role in the disease pathogenesis.^[1] Malignancies are one of the major causes of the etiology in patients with atypical and severe disease course; it has been suggested that the underlying malignancy contributes to the development of the disease by modifying the immune responses.^[5] The development of GD following transplantation, chemotherapy, and radiotherapy and atypical and severe disease course may support this hypothesis.^[5] In addition, Paslin reported a case of GD triggered by varenicline which acts as a nicotine antagonist.^[6] The lesions in the present case occurred in the summer months; however, further investigations did not show any malignancy or immunosuppression, and there was no history of drug use which might induce the disease.

In clinical practice, GD is characterized by papulovascular lesions with recurrent erythema which rapidly turn into crusted and keratotic erosions. Itching is one of the main symptoms of the disease which leads to severe distress.^[4] In addition, several conditions presenting with generalized papular lesions may mimic GD. The disease has four histopathological patterns, including Darier disease-like, Hailey-Hailey disease-like, pemphigus vulgaris-like, and spongiotic type. The most commonly reported subtypes are Darier disease-like and pemphigus vulgaris-like.^[1]

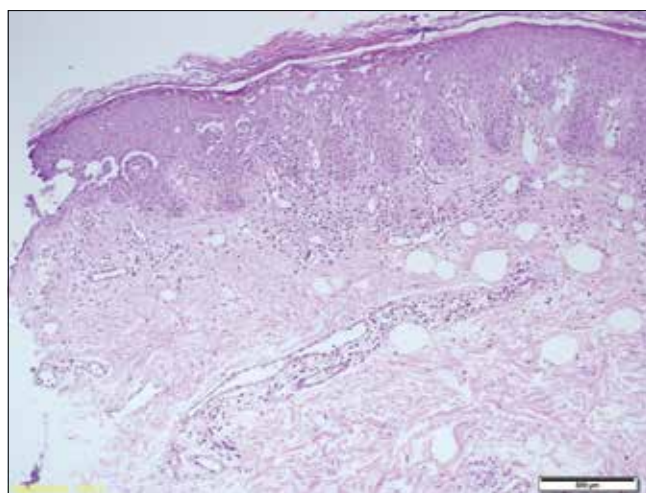


Figure 2: Hyperkeratosis, acanthosis, spongiosis, suprabasal acantholysis, superficial dermal edema, perivascular neutrophilic, and eosinophilic inflammatory cell infiltrate (H and E, ×40)

For the treatment of GD, UV phototherapy is a cost-effective modality which is successfully used in the treatment of many conditions in the practice of dermatology.^[7] The UV exposure is among the prominent triggering factors in etiopathogenesis of GD; however, the reports interestingly suggest that phototherapy can be also effective in the treatment of GD. The exact mechanism of action of phototherapy in GD is unknown.^[1] The reports have suggested that bathing and oral PUVA, particularly, can be effective in refractory cases.^[8,9] Furthermore, moderate-dose UVA-1 therapy has been demonstrated to be successful in cases in whom PUVA is unable to be administered.^[10] Liu and Letada^[4] reported a dramatic improvement in disease symptoms in a resistant case of GD using red light 5-aminolevulinic acid-photodynamic therapy. In the present case, the lesions spread to the whole trunk following five sessions of PUVA phototherapy, and therefore, therapy was discontinued.

In conclusion, GD is a dermatosis triggered by UV exposure; phototherapy is included in the treatment options. However, aggravation was observed soon after the treatment in the present case. Therefore, while treating GD with PUVA phototherapy, we suggest that clinicians should be aware of the possibility of aggravating lesions.

Declaration of patient consent

The authors certify that they have obtained all appropriate patient consent forms. In the form the patient(s) has/have given his/her/their consent for his/her/their images and other clinical information to be reported in the journal. The patients understand that their names and initials will not be published and due efforts will be made to conceal their identity, but anonymity cannot be guaranteed.

Financial support and sponsorship

Nil.

Conflicts of interest

There are no conflicts of interest.

REFERENCES

1. Aldana PC, Khachemoune A. Grover disease: Review of subtypes with a focus on management options. *Int J Dermatol* 2019. [Epub ahead of print].
2. Munoz J, Guillot B, Girard C, Dereure O, Du-Thanh A. First report of ipilimumab-induced Grover disease. *Br J Dermatol* 2014;171:1236-7.
3. O'Gorman SM, Murphy GM. Photoaggravated disorders. *Dermatol Clin* 2014;32:385-98, ix.
4. Liu S, Letada PR. Successful novel treatment of recalcitrant transient acantholytic dermatosis (Grover disease) using red light 5-aminolevulinic acid photodynamic therapy. *Dermatol Surg* 2013;39:960-1.
5. Gantz M, Butler D, Goldberg M, Ryu J, McCalmont T, Shinkai K. Atypical features and systemic associations in extensive cases of Grover disease: A systematic review. *J Am Acad Dermatol* 2017;77:952-70.
6. Paslin D. Grover disease may result from the impairment of keratinocytic cholinergic receptors. *J Am Acad Dermatol* 2012;66:332-3.
7. Vangipuram R, Feldman SR. Ultraviolet phototherapy for cutaneous diseases: A concise review. *Oral Dis* 2016;22:253-9.
8. Paul BS, Arndt KA. Response of transient acantholytic dermatosis to photochemotherapy. *Arch Dermatol* 1984;120:121-2.
9. Lüftl M, Degitz K, Plewig G, Röcken M. Bath psoralen-UV-A therapy for persistent Grover disease. *Arch Dermatol* 1999;135:606-7.
10. Breuckmann F, Appelhans C, Altmeyer P, Kreuter A. Medium-dose ultraviolet A1 phototherapy in transient acantholytic dermatosis (Grover's disease). *J Am Acad Dermatol* 2005;52:169-70.