



Identification of *Clostridium septicum* in a tubo-ovarian abscess: A rare case and review of the literature

Identifikacija bakterije *Clostridium septicum* u tuboovarijalnom apscesu

Ali Yavuzcan*, Mete Çağlar*, Serdar Dilbaz*, Selahattin Kumru*, Fatma Avcioglu†, Yusuf Üstün*

*Department of Obstetrics and Gynecology, †Department of Microbiology, Düzce University Faculty of Medicine, Düzce, Turkey

Abstract

Introduction. Tubo-ovarian abscess (TOA) is a conglomerated mass of pelvic organs including the tube, the ovary, and the bowel. The most commonly isolated organisms from TOAs are *Escherichia coli* (*E. coli*) and *Bacteroides species*.

Case Report. We reported a case of *Clostridium septicum* (*C. septicum*) infection from a ruptured TOA with atypical clinical features. Culture of intra-abdominal free fluid obtained during surgery yielded *C. septicum*. VITEK II (bioMérieux, France) automated system was used for advanced identification of the bacteria. Parenteral clindamycin in combination with an aminoglycoside was used. The patient was discharged 19 days after the surgery and was clinically asymptomatic 6 months after the surgery. **Conclusion.** The differential diagnosis of TOA caused by *C. septicum* can be difficult, due to the lack of the symptoms. Tissues infected with *C. septicum* can become necrotic. A combination of early, adequate antibiotic therapy and surgery is the key point of the treatment.

Key words:

pelvic inflammatory disease; abscess; rupture; clostridium septicum; gynecologic surgical procedures.

Apstrakt

Uvod. Tuboovarijalni apsces (TOA) predstavlja konglomerat koji zahvata karlične organe: jajovod, ovarijum i debelo crevo. Najčešće izazivači TOA su *Escherichia coli* (*E. coli*) i *Bacteroides species*. **Prikaz bolesnika.** Prikazali smo bolesnicu sa infekcijom izazvanom bakterijom *Clostridium septicum* (*C. septicum*), nastalom nakon rupture tuboovarijalnog apscesa (TDA) sa atipičnom kliničkom slikom. Iz kulture iz slobodne abdominalne tečnosti uzete tokom hirurškog zahvata, izolovana je *C. septicum*. Automatizovani sistem VITEK II (bioMérieux, France) korišćen je za brzu identifikaciju bakterija. Bolesnici je ordinirana parenteralna antibiotska terapija: klindamicin u kombinaciji sa aminoglikozidom. Otpuštena je iz bolnice 19. dana posle hirurškog zahvata i bila je bez kliničkih simptoma u narednih 6 meseci. **Zaključak.** Diferencijalna dijagnostika TOA uzrokovanog *C. septicum* može biti teška, zbog izostanka simptoma. Tkiva inficirana sa *C. septicum* mogu nekrotizovati, a kombinacija rane, adekvatne antibiotske terapije i hirurgije ključna je u lečenju TOA.

Ključne reči:

karlični organi, zapaljenske bolesti; apsces; ruptura; clostridium septicum; hirurgija, ginekološka, procedure.

Introduction

Pelvic inflammatory disease (PID), which is characterized by a polymicrobial infection in the upper genital tract, can include endometritis, salpingitis and tubo-ovarian abscess (TOA). It is generally caused by sexually transmitted infections (STIs) such as *Chlamydia trachomatis* and *Neisseria gonorrhoeae* that spread upward from the lower genital tract, infecting and causing inflammation of the uterus, fallopian tubes, and ovaries¹. Anaerobic, and facultative bacteria are the other microorganisms in the pathogenesis of PID². PID is one of the most common causes of hospitalization for

gynecologic disorders among woman in reproductive age. In the United States, 770,000 cases of PID are diagnosed every year³. The annual cost of PID and its consequences is estimated to be \$ 4.2 billion⁴. PID is usually sexually active women's disease. It may be the cause of sepsis and mortality in untreated cases. A TOA can be detected in about 15% of women with PID. TOA develops in up to 34% of patients hospitalized for PID⁵.

An end-stage process of acute PID is TOA. It is a conglomerated mass of pelvic organs including tube, ovary and bowel. Severe acute PID usually generates this disease. TOA could be defined in 18–34% of patients with PID⁵. Risk

factors for TOA are similar to that of PID and include multiple sexual partners, intrauterine device and low socioeconomic status⁶. Since the disease is commonly caused by the STIs, intercourse with a partner having infection is the most important risk factor in TOA formation. However, gynecologic surgery, genital malignancy, *in vitro* fertilization treatment, and perforated appendicitis have also been shown to cause TOA⁷.

The association of *Clostridium species*, which are gram-positive, anaerobic spore former, usually found in the soil and gastrointestinal tract, with post-traumatic and surgical wound complications is well-known. A total of 80–90% of all clostridial infections occur due to *C. perfringens*. *C. septicum* is isolated at 4–20% of clostridial infections⁸. Spontaneous *C. septicum* infections are rare and associated with cyclical neutropenia, diabetes mellitus and immunosuppression. A strong association of spontaneous *C. septicum* infection with haematological and colorectal malignancies is known. Cerebral abscess and aortic-ring abscess due to *C. septicum* have been also reported before^{9,10}. A survival rate of only 35% of patients with *C. septicum* has been reported regardless of the presence of an occult malignancy *versus* a clinically evident malignancy. It is mandatory to carry out a systematic and aggressive approach to the treatment of these patients¹¹. A ruptured TOA and septic shock with *Clostridium perfringens* in a postmenopausal woman was reported¹². *Clostridium sordellii* and *Clostridium perfringens* are responsible for a toxic shock after medical and spontaneous abortions¹³.

We reported a rare case of *C. septicum* infection from a ruptured TOA with atypical clinical features.

Case report

A 38 year-old Caucasian woman, para II, gravida II, was referred to our Department with a pelvic mass. She presented with a 10-day history of nausea, vomiting and right lower abdominal pain. She had a regular menstrual cycle, her history revealed two unremarkable cesarean sections. She had a total thyroidectomy. The patient did not have a personal and familial history of gastrointestinal disorders. She was not receiving immunosuppressive therapy. She had not received treatment for cancer. She had her intrauterine device (IUD) removed two months before after having it for several years.

On physical examination, there was right lower quadrant tenderness. There was guarding of muscle. She had white vaginal discharge. A large, immobile, 12 × 10 cm semisolid mass at the right adnexal region was palpated *via* bimanual pelvic exam. There was a fixed retroverted uterus. The uterosacral ligaments and parametrium were not tender. The patient was afebrile. Vital signs were in normal ranges. Laboratory investigations revealed a high white blood cell count of 32,900/ μ L, 90% of which comprised segmented neutrophils and a high trombocyte count of 722,000/ μ L. Serum C-reactive protein (CRP) level was found to be high. It was 48.1 mg/dL. Blood urea nitrogen (BUN) was 29 mg/dL; serum creatinine was 2.88 mg/dL; and uric acid was 8.6

mg/dL. Our ultrasonographic examination showed a 125 × 72 mm semisolid, heterogenous mass at the right adnexal region (Figure 1). There was fluid in the pouch of Douglas.

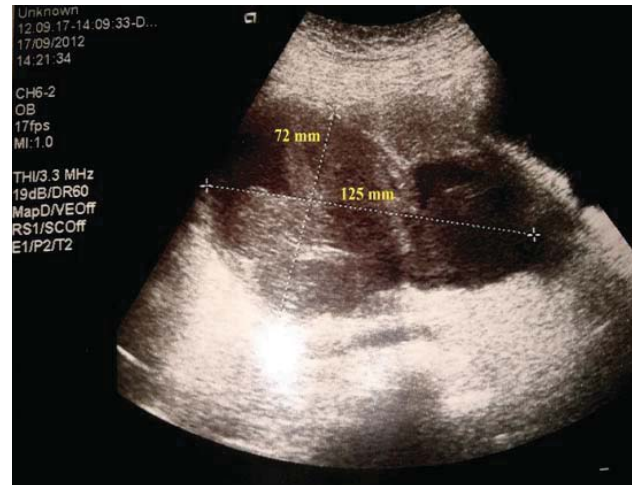

Fig. 1 – Preoperative transvaginal ultrasonographic view of the pelvis.

The serum levels of CA-125, CA-19-9, carcinoembryonic antigen (CEA) and α -fetoprotein (AFP) were 15.11, 14.30, 1.63 and 1.61 U/mL, respectively. The patient's serum β -human chorionic gonadotropin (hCG) level was 0.1 IU/L. She was negative for hepatitis B surface antigen. Antibody testing for HIV and HCV was done on serum specimens. Tests were negative. Clindamycin was used in a combination with an aminoglycoside by the parenteral route. The patient underwent laparotomy with a preoperative diagnosis of pelvic abscess. Mid-line laparotomy was performed. About 2,000 mL of infected fluid and pus were located inside the abdominal cavity. After draining, it was seen that the right tubo-ovarian abscess had already ruptured and adhered to the ileum, sigmoid colon and rectum. A sample of the peritoneal free fluid was taken. Dense adhesions between the mass and other pelvic structures were seen. Right tubo-ovarian complex was removed. Right salphingo-oophorectomy was performed. Samples of free fluid were cultured onto chocolate agar, blood agar, and eosin methylene-blue lactose agar. Two prepartate were made and evaluated with gram staining at the same time. Anaerobic culture media was put in a jar and oxygen-free environment was provided with using dry process gas packet (AnaeroGen – Oxoid, Basingstoke, UK veyá GENbox-bioMérieux, Lyon, France). Then chocolate agar was placed in the waxy jar. All of the media were incubated at 35–37°C for 48 hours. There was not bacterial overgrowth in blood culture. Bacteria that did not live or grow in the presence of oxygen was accepted as anaerobic bacteria. The structure of the colony was analyzed. Gram stain was performed to help identify colonies isolated from cultures. Also VITEK II (bioMérieux, France) automated system was used for advanced identification of bacteria. Large gram-positive, spore forming, obligate anaerobic, rod-shaped and motile bacteria (*C. septicum*) were obtained from intraabdominal free fluid (Figure 2).

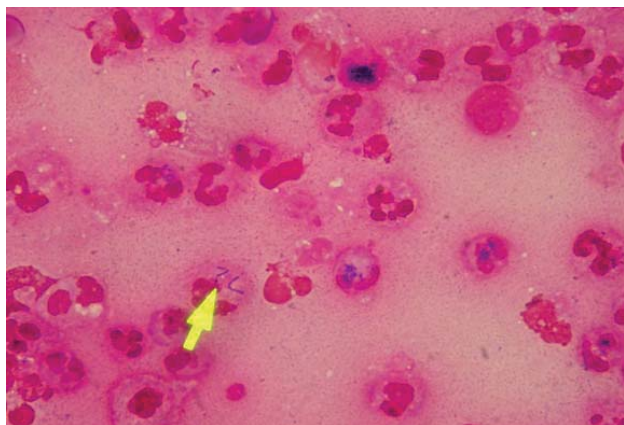


Fig. 2– *Clostridium septicum* obtained from intraperitoneal free fluid (dry process gas packet).

Combined upper and lower gastrointestinal endoscopy was performed after detection of *C. septicum* in order to eliminate a potential neoplasm of the gastrointestinal tract. The computed tomography (CT) scan of the chest, abdomen and pelvis was done. No tumor was visualized. Postoperative CT scans also showed contrast enhancement in the previous operation site (Figure 3). The patient was discharged 19 days after the surgery, and was clinically asymptomatic 6 months after the surgery.

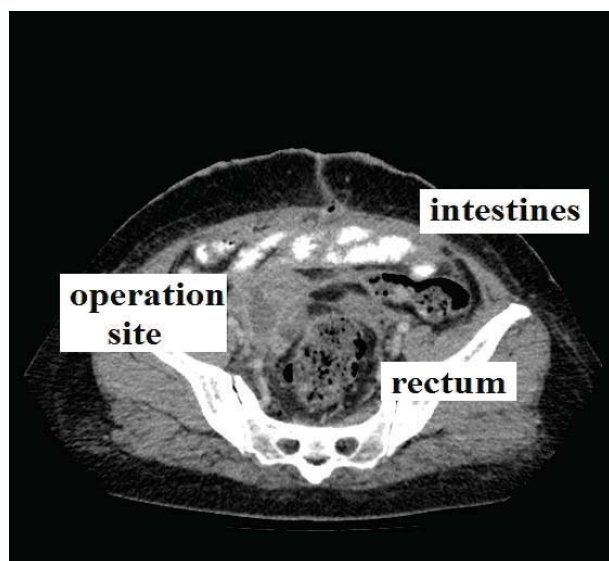


Fig. 3 – Postoperative computed tomography (CT) scan of the operation site.

Discussion

Various gynecological and nongynecological pathologies can be presented as pelvic masses. Infectious diseases should be considered in differential diagnosis. Following an acute salpingitis, fallopian tubes become distended with purulent material creating a TOA. PID can lead to tubal scarring and stenosis which become distended as the tubal secretions accumulate within the tubal lumen. This process leads to the formation of hydrosalpinx and presents as a tubular pelvic mass. Both of

these conditions can be chronic or acute and should be always suspected in any woman with a history of malodorous cervical discharge, pelvic pain and fever¹⁴. A purely clinical approach using the findings of lower genital tract inflammation (leukorrhea) associated with pelvic organ tenderness will identify the vast majority of women with PID¹⁵. The uterosacral ligaments and parametrium in our patient were not tender. There was no fever, malodorous cervical discharge, no the history of PID so it was quite difficult to diagnose preoperatively.

Infections due to *Neisseria gonorrhoeae*, like those resulting from *Chlamydia trachomatis*, are a major cause of PID in the United States¹⁶. But *Neisseria gonorrhoeae* and chlamydia are rarely recovered from an abscess. The most commonly isolated organisms from TOAs are *E. coli* and *Bacteroides species*¹⁷. There is an association between the presence of the vaginal flora bacteria and/or actinomycetes and TOA in women who use IUDs. There is an increased risk of ascending infection. IUD tails facilitate the transfer of bacteria from the vagina/cervix to the upper genital tract¹⁸. The presented patient used to have IUD but she had her IUD removed 2 months ago. No vaginal bacteria or actinomycetes in the specimens could be detected.

C. septicum causes myonecrosis through the release of exotoxins such as the alpha toxin, lethal toxin and hemolytic toxin. They were initially believed to be non-pathogenic. On the other hand, alpha toxin of *C. septicum* is necrotic and lethal. Bacteremic infections with *C. septicum* are associated with a mortality of 68% and should be treated as a medical emergency¹⁹. Owing to its anaerobic nature *C. septicum* can be detected in areas of decreased blood flow. *C. septicum* infections are often detected in individuals with the recent history of trauma, surgery, peripheral vascular disease, diabetes, colon cancer, skin infections or burns and septic abortions²⁰. The diagnosis of *C. septicum*-associated large bowel malignancy may be delayed or missed. Clinical manifestations are commonly nonspecific, mimicking more common disorders. At times, no clinical clue to a colon malignancy is present. Some clinicians may be unaware of the association. Bacterial sepsis may be the initial feature of previously undiagnosed and unsuspected large bowel carcinoma²¹. There are some atypical presentations of *C. septicum* infections that have been reported in recent years. The possible mechanism of these unusual presentations is generally hematogenous seeding of microorganism and defective circulation. Halak et al.²² reported a *C. septicum* infection at aortic graft. The patient had an abdominal aortic aneurysm reducing blood flow in the affected areas. It was reported that myonecrosis caused by *C. septicum* in an immunosuppressed patient with no colon cancer, but rather colonic mucosal inflammation produced by *C. difficile*²³. *C. septicum* infection may be detected in the orbita, brain, aorta and lower limb^{24–30}. *E. coli* may be a concomitant or predisposing factor²⁵. A rare mechanism is direct extension of infection, such as from incarcerated internal hernia²⁹. In 2009 Wagner et al.¹² reported a ruptured tubo-ovarian abscess and septic shock with *Clostridium perfringens* in a postmenopausal woman. The hysterectomy specimen of that patient revealed endometrial carcinoma¹². A fatal case of *Clostridium sordellii* septic shock

syndrome associated with medical abortion was reported³¹. Endomyometritis and toxic shock associated with *Clostridium sordellii* and *Clostridium perfringens* after medical and spontaneous abortion is well known¹³. Necrotising endomyometritis due to *C. sordellii* infection may be notable for lack of fever, haemoconcentration and a profound leukocytosis³². These properties are remarkably similar to those of ruptured TOA due to *C. septicum*. Ruptured TOA due to *C. septicum* is an extremely rare phenomenon. After evaluation, malignancy could be definitively ruled out in our patient. The presented patient, however, was not treated with immunosuppressive drugs. There was no evidence of immunosuppression.

There are few large randomized trials guiding appropriate clinical management of TOA, including antibiotic selection and timing of surgical management and drainage (Table 1)³³.

tient antibiotic regimen was suggested. Upon discontinuation of parenteral therapy, the CDC recommends clindamycin or metronidazole to be used with doxycycline for a total of 14 days of treatment³⁵. The best treatment alternative for ruptured TOA is surgery. Parenteral antibiotic therapy cannot be adequate for complete healing. Patients with larger abscesses usually need surgery^{34,36}. Dewitt et al.³⁶ reported a 60% failure rate of antibiotic treatment for abscesses with dimension of ≥ 10 cm. After intravenous antibiotics therapy, we performed salpingoophorectomy in the presented patient.

Conclusion

C. septicum may cause pelvic inflammatory disease and turbo-ovarium abscess in patients without any predisposing

Table 1

Recent cases of atypical presentations of *Clostridium septicum* infections

References	Localization	Predisposing disease	Concomitant infection
Halak et al. ²²	Aortic graft	Abdominal aortic aneurysm	None
Gnerlich et al. ²³	Colon	End-stage renal disease and immunodeficiency syndrome	<i>C. difficile</i> colitis
Fejes et al. ²⁴	Orbita	Colon tumour and lymphatic malignancy	None
Williams et al. ²⁵	Brain abscess	Haemolytic uraemic syndrome	<i>E. coli</i> 0157
Annapureddy et al. ²⁶	Aorta	Atheromatous disease of the aorta	None
Rewa and Smith ²⁷	Lower limb compartment syndrome	Non-Hodgkin's lymphoma	None
Ge and de Virgilio ²⁸	Aorta	Sigmoid colon adenocarcinoma.	None
Granok et al. ²⁹	Lung pleura	Incarcerated internal hernia	None
Burnell et al. ³⁰	Prosthetic joint of knee	Colonic malignancy	None

Radiographic size, leukocyte count, age, and parity are associated with operative or procedural treatment of TOA³⁴. Originally, treatment of TOA was thought to perform bilateral oophorectomy and hysterectomy. Medical management with broad spectrum antibiotics is nowadays generally considered as the initial management for unruptured TOAs². The Center for Disease Control (CDC) and Prevention Sexually Transmitted Diseases Treatment Guidelines recommend inpatient intravenous antibiotics for at least 24 hours. No specific inpa-

factor. Diagnosis of turbo-ovarium abscess due to *C. septicum* is very hard. Lack of fever and malodorous cervical discharge, no history of pelvic inflammatory disease, no pain on movement of cervix are difficulties. The infected issues with *C. septicum* can become necrotic. A combination of early adequate antibiotic therapy and surgery is the key point of treatment. Although there was no malignancy in the presented patient, malignancy should be kept in mind for all kinds of infections due to *C. septicum*.

R E F E R E N C E S

1. Susan M. Pelvic inflammatory disease and tubo-ovarian abscess. *Infect Dis Clin N Am* 2008; 22(4): 693–708.
2. Landers DV, Sweet RL. Tubo-ovarian abscess. In: Sweet RL, editor. *Pelvic Inflammatory Disease*. London, UK: Taylor & Francis; 2006. p. 101–24.
3. Sutton MY, Sternberg M, Zaidi A, St Luis ME, Markovitz LE. Trends in pelvic inflammatory disease hospital discharges and ambulatory visits, United States, 1985-2001. *Sex Transm Dis* 2005; 32(12): 778–84.
4. Quan M. Pelvic inflammatory disease: diagnosis and management. *J Am Board Fam Pract* 1994; 7(2): 110–23.
5. Beigi RH, Wiesenfeld HC. Pelvic inflammatory disease: new diagnostic criteria and treatment. *Obstet Gynecol Clin North Am* 2003; 30(4): 777–93.
6. Washington AE, Aral SO, Wolner-Hanssen P, Grimes DA, Holmes KK. Assessing risk for pelvic inflammatory disease and its sequelae. *JAMA* 1991; 266(18): 2581–6.
7. Protopapas AG, Diakomanolis ES, Milingos SD, Rodolakis AJ, Markaki SN, Vlachos GD, et al. Tubo-ovarian abscesses in postmenopausal women: gynecological malignancy until proven otherwise. *Eur J Obstet Gynecol Reprod Biol* 2004; 114(2): 203–9.
8. Mayer G, Kang R. Gas gangrene, diabetes, and cholecystitis. *Am J Emerg Med* 1985; 3(1): 42–5.
9. Marangou AG, Joske RA, Kaard AO, Thomas W. Cerebral abscess due to *Clostridium septicum*. *J R Soc Med* 1992; 85(10): 641.
10. Cohen CA, Almeder LM, Israni A, Maslow JN. *Clostridium septicum* endocarditis complicated by aortic-ring abscess and aortitis. *Clin Infect Dis* 1998; 26(2): 495–6.
11. Kornbluth AA, Danzig JB, Bernstein LH. *Clostridium septicum* infection and associated malignancy. Report of 2 cases and review of the literature. *Medicine* 1989; 68(1): 30–7.

12. *Wagner A, Russell C, Ponterio JM, Pessolano JC.* Ruptured tubo-ovarian abscess and septic shock with *Clostridium perfringens* in a postmenopausal woman: a case report. *J Reprod Med* 2009; 54(10): 652–4.
13. *Cohen AL, Bhatnagar J, Reagan S, Zane SB, Angeli MD, Fischer M,* et al. Toxic shock associated with *Clostridium sordellii* and *Clostridium perfringens* after medical and spontaneous abortion. *Obstet Gynecol* 2007; 110(5): 1027–33.
14. *Stenchever MA, Droegenmueller W, Hebrst AL, Miscbell DR.* Differential diagnosis of major gynecological problems by age group. In: *Lentz G, Lobo R, Gershenson D, Katz V,* editors. *Comprehensive gynecology.* 5th ed. Philadelphia, PA; Mosby Elsevier; 2001. p. 137–55.
15. *Jaiyeoba O, Soper DE.* A practical approach to the diagnosis of pelvic inflammatory disease. *Infect Dis Obstet Gynecol* 2011; 2011: 753037.
16. *Centers for Disease Control and Prevention.* 2011 Sexually Transmitted Diseases Surveillance. [updated 2013 March 5]. Available from: www.cdc.gov/std/stats11
17. *Landers DV, Sweet RL.* Tubo-ovarian abscess: contemporary approach to management. *Rev Infect Dis* 1983; 5(5): 876–84.
18. *Toglia MR, Schaffer JL.* Tubo-ovarian abscess formation in users of intrauterine devices remote from insertion: a report of three cases. *Infect Dis Obstet Gynecol* 1996; 4(2): 85–8.
19. *Johnson S, Driks MR, Tweten RK, Ballard J, Stevens DL, Anderson DJ,* et al. Clinical courses of seven survivors of *Clostridium septicum* infection and their immunologic responses to alpha toxin. *Clin Infect Dis* 1994; 19(4): 761–4.
20. *Smith-Slatas CL, Bourque M, Salazar JC.* *Clostridium septicum* infections in children: a case report and review of the literature. *Pediatrics* 2006; 117(4): e796-805.
21. *Mao E, Clements A, Feller E.* *Clostridium septicum* Sepsis and Colon Carcinoma: Report of 4 Cases. *Case Rep Med* 2011; 2011: 248453.
22. *Halak M, Heldenberg E, Silverberg D, Schneiderman J.* *Clostridium septicum* post-endovascular aneurysm repair stent-graft infection. *Vascular* 2012; 20(2): 104–6.
23. *Gnerlich JL, Ritter JH, Kirby JP, Mazuski JE.* Simultaneous necrotizing soft tissue infection and colonic necrosis caused by *Clostridium septicum*. *Surg Infect (Larchmt)* 2011; 12(6): 501–6.
24. *Fejes I, Degi R, Vegh M.* *Clostridium septicum* gas gangrene in the orbit: a case report. *Infection* 2013; 41(1): 267–70.
25. *Williams EJ, Mitchell P, Mitra D, Clark JE.* A microbiological hazard of rural living: *Clostridium septicum* brain abscess in a child with E coli 0157 associated haemolytic uraemic syndrome. *BMJ Case Rep* 2012; 2012. doi:pii:bcr2012006424.
26. *Annareddy N, Agarwal SK, Kanakadandi V, Sabbarwal MS, Ammakkanavar N, Simoes P,* et al. *Clostridium septicum* aortitis in a patient with extensive atheromatous disease of the aorta. *J Infect Chemother* 2012; 18(6): 948–50.
27. *Reva O, Smith CA.* Medical cause of compartment syndrome: a fatal case of *Clostridium septicum*. *BMJ Case Rep* 2012; 2012. pii: bcr1220115434.
28. *Ge PS, de Virgilio C.* *Clostridium septicum* aortitis with associated sigmoid colon adenocarcinoma. *Ann Vasc Surg* 2012; 26(2): 280.e1–4.
29. *Granok AB, Mabon PA, Bieseke GW.* *Clostridium septicum* Emyema in an Immunocompetent Woman. *Case Rep Med* 2010; 2010: 231738.
30. *Burnell CD, Turgeon TR, Hedden DR, Bohm ER.* Paraneoplastic *Clostridium septicum* infection of a total knee arthroplasty. *J Arthroplasty* 2011; 26(4): 666.e9–11.
31. *Wiebe E, Guilbert E, Jacot F, Shannon C, Winikoff B.* A fatal case of *Clostridium sordellii* septic shock syndrome associated with medical abortion. *Obstet Gynecol* 2004; 104(5 Pt 2): 1142–4.
32. *Centers for Disease Control and Prevention (CDC).* *Clostridium sordellii* toxic shock syndrome after medical abortion with mifepristone and intravaginal misoprostol—United States and Canada, 2001–2005. *MMWR Morb Mortal Wkly Rep* 2005; 54(29): 724.
33. *Chappell CA, Wiesenfeld HC.* Pathogenesis, diagnosis, and management of severe pelvic inflammatory disease and tuboovarian abscess. *Clin Obstet Gynecol* 2012; 55(4): 893–903.
34. *Greenstein Y, Shah AJ, Vragovic O, Cabral H, Soto-Wright V, Borgatta L,* et al. Tuboovarian abscess. Factors associated with operative intervention after failed antibiotic therapy. *J Reprod Med* 2013; 58(3–4): 101–6.
35. *Centers for Disease Control and Prevention, Workowski KA, Berman SM.* Sexually transmitted diseases treatment guidelines, 2006. *MMWR Recomm Rep* 2006; 55(RR–11): 1–94.
36. *Dewitt J, Reining A, Allsworth JE, Peipert JF.* Tuboovarian abscesses: is size associated with duration of hospitalization & complications. *Obstet Gynecol Int* 2010; 2010: 847041.

Received on April 6, 2013.

Revised on May 6, 2013.

Accepted on July 8, 2013.

OnLine-First June, 2014.

Copyright of Vojnosanitetski Pregled: Military Medical & Pharmaceutical Journal of Serbia & Montenegro is the property of Military Medical Academy INI and its content may not be copied or emailed to multiple sites or posted to a listserv without the copyright holder's express written permission. However, users may print, download, or email articles for individual use.