

CASE REPORT
OLGU SUNUMUABSTRACT
ÖZETAPPENDICO-ILEAL FISTULA IN AN ACUTE ILEUS PATIENT
BİR AKUT İLEUS OLGUSUNDA APENDİKO-İLEAL FİSTÜLMehmet Yaşar¹, Arif Aslaner², Orhan Bat³

Appendico-ileal fistula is a rare condition with acute ileus. We report a case of appendico-ileal fistule in a 46-year-old man patient who has undergone laparotomy for intestinal mechanical obstruction. Intraoperatively, an appendix with a lumen was found with a fistula to the terminal ileum. It has been observed that proximal ileal and jejunal intestinal anses were distended. Appendectomy, segmental ileum resection and end-to-end anastomoses were performed as a surgical procedure. This case describes an elderly man with acute ileus presenting with small bowel obstruction. We conclude that, appendico-ileal fistula should be kept in mind in cases with acute ileus presenting with small bowel obstruction.

Key words: Appendix, Fistula, Ileum, Ileus

Appendiko-ileal fistül akut ileus tablosu ile nadir görülür. Bu yazıda mekanik barsak tıkanıklığı nedeni ile laparotomi uygulanan apendikoileal fistüllü 46 yaşında erkek olgu sunuldu. Cerrahi sırasında apendiks lümeni ile terminal ileum arasında bir fistül olduğu gözlemlendi. Ayrıca proksimal ileal ve jejunal ansaların gergin olduğu da saptandı. Apendektomi, segmental ileum rezeksiyonu ve uçuca anastomoz cerrahi işlem olarak uygulandı. İnce barsak tıkanıklığı ile akut ileus tablosu gelişen hastalarda, apendiko-ileal fistülün akılda bulunması gerektiğini düşünmekteyiz.

Anahtar kelimeler: Apendiks, Fistül, İleum, İleus

Introduction

Appendico-ileal fistule is a very rare condition in the healthy population. Internal appendicular-intestinal fistulae can occur as a complication of many cases, primarily with acute appendicitis. Ileocecal resection and fistulectomy with primary reconstruction are the standard procedures. If there is an appendectomy history it should be kept in mind that appendico-ileal fistula can be seen in patients with acute ileus.

Case Report

A 46-year-old man was admitted to our emergency department complaining of abdominal pain, nausea and vomiting. On physical examination, the abdomen was markedly distended. Abdominal palpation revealed rebound and severe tenderness. The patient revealed a blood pressure of 100/70 mmHg, and a pulse rate of 78 beats/min. Laboratory investigations were normal except for mild leucocytosis (WBC: 11500/mm³). On the plain abdominal radiographies there were multiple air fluid levels (Figure 1). Abdominal tomography revealed a right lower quadrant cecal wall thickening of up to 1cm and dilatation of intestinal segments. For an appropriate mechanical preparation of the colon, colonoscopy is not effectively made. F When the diagnosis of acute ileus was established, the patient underwent laparotomy. During surgery, the distal 10 cm of the terminal ileum with a reduced caliber and distortion was seen. This distortion was caused by a thickened appendix lying within the mesentery and, therefore, covered by peritoneum. Apparently, the appendix initially had become inflamed, thereby distorting the ileum and creating a mechanical obstruction. The proximal small intestine was seen to be increasingly distended. On further dissection, a fistula arising from the tip of the appendix was found to be attached firmly to the terminal ileum that was dissecting the passage of the small intestine (Figure 2). Appendectomy, segmental ileum resection and end-to-end anastomosis were performed. The postoperative course of the patient was uneventful and he was discharged on the postoperative 5th day of the operation with no complaints.

The histological findings of the appendix showed a fibrotic wall with signs of chronic inflammation. Goblet cells were increased in numbers. There was a copious amount of eosinophilic material in the lumen.

Discussion

In general, appendico-ileal fistulae are very rare within the otherwise healthy population (1-3) Even a case of a congenital appendico-ileal fistula has been published, possibly a sequela of intrauterine perforation (4). Schier describes a young woman with cystic fibrosis presenting with small bowel obstruction. Intraoperatively, an appendix

¹Department of General Surgery, Faculty of Medicine, Düzce University, Düzce, Turkey

²Department of General Surgery, Antalya Training and Research Hospital, Antalya, Turkey

³Department of General Surgery, Fatih Sultan Mehmet Training and Research Hospital, İstanbul, Turkey

Submitted/Geliş Tarihi
16.10.2011

Accepted After Revision
Düzeltilme Sonrası Kabul Tarihi
10.01.2012

Correspondance/Yazışma
Dr. Mehmet Yaşar,
Department of General Surgery,
Faculty of Medicine, Düzce
University, Düzce, Turkey
Phone: +90 380 542 13 90-5546
e.mail: myasar59@yahoo.com
myasar59@gmail.com

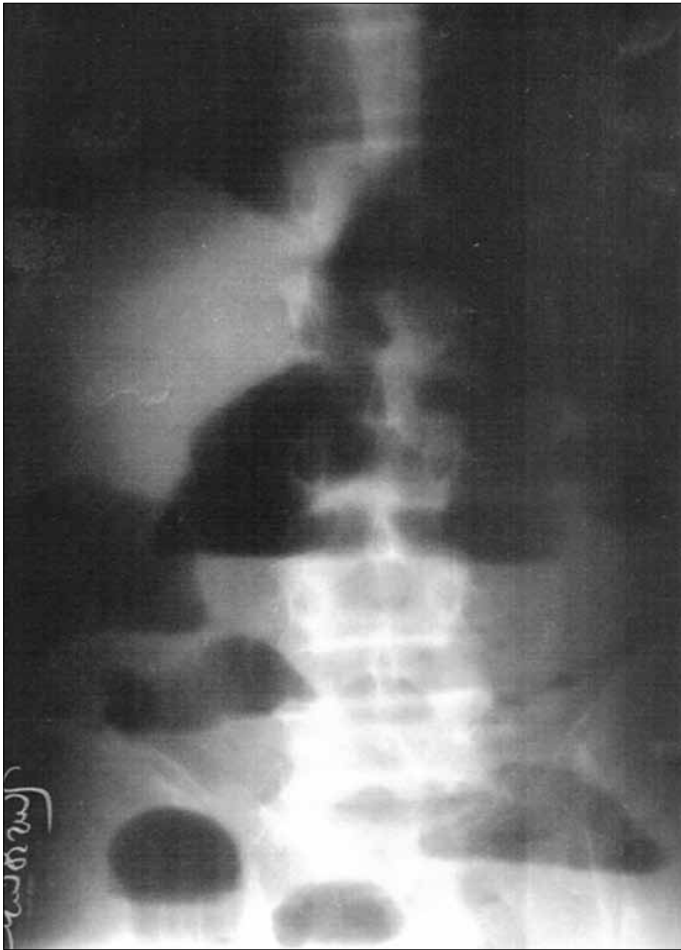

Figure 1. Multiple air fluid levels seen on plain abdominal graphy

with a wide lumen was found with a fistula into the distal ileum (5). Internal appendicular-intestinal fistula as a complication of acute appendicitis (6), appendico-enteric fistula (7, 8) and appendico-ileal fistula were also present as an ileal mass (1). An appendico-ileo-vesical fistula secondary to appendiceal diverticulitis demonstrates the importance of barium enema and colonoscopic examinations in the diagnosis and treatment of a complicated enterovesical fistula. Ileocecal resection and fistulectomy with primary reconstruction were performed (9).

As a result, it was kept in mind that, appendico-ileal fistula can be seen in patients with acute ileus presenting with small bowel obstruction masses in the right lower quadrant masses and ileus with small bowel obstruction if there is any history of appendectomy. Intraoperative exploratory diagnosis is superficial to preoperative radiologic methods such as ultrasonography and computerized tomography.

Conflict of interest

No conflict of interest was declared by the authors.

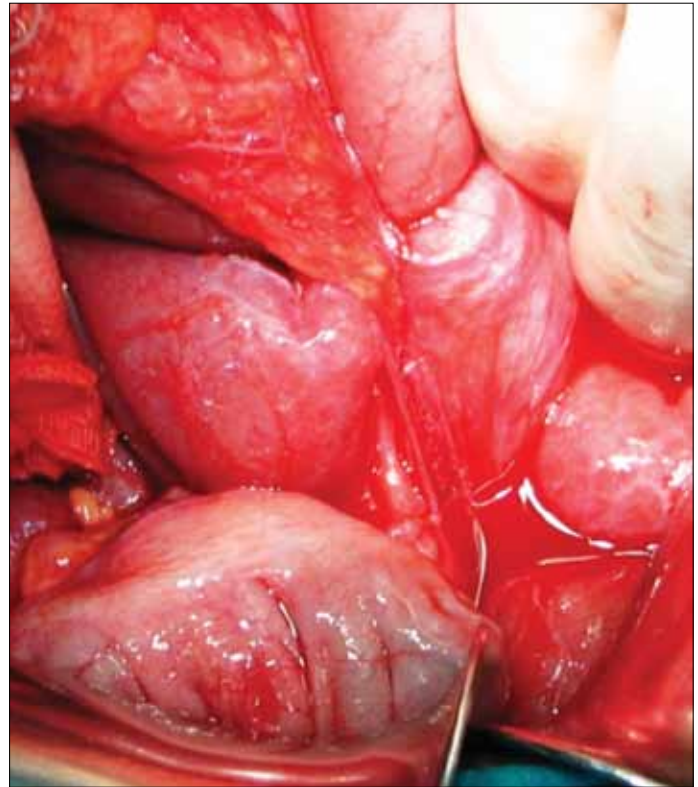


Figure 2. Intraoperative finding showing the appendico-ileal fistula

Authors' contributions: Conceived and designed the experiments: MY, AA. Performed the experiments: MY, AA, OB. Analyzed the data: OB. Wrote the paper: MY, AA, OB. All authors read and approved the final manuscript.

References

1. Fennessy JJ, Evans RH. Appendico-ileal fistula presenting as an ileal mass. Report of a case. *Am J Dig Dis* 1968; 13: 1012-6. [\[CrossRef\]](#)
2. Keeley JL. Appendico-ileal fistula. A complication of acute appendicitis with perforation. *AMA Arch Surg* 1951; 63: 211-3. [\[CrossRef\]](#)
3. Shallow TA, Eger SE, Knowles HJ. Appendico-ileal fistula. *Am J Surg* 71; 1957: 423-4. [\[CrossRef\]](#)
4. Garcia DA. Congenital anastomosis of the appendix with the ileum. Report of a case. *J Philippine MA* 1940; 20: 725-6.
5. Schier F. Appendico-ileal fistula in cystic fibrosis. *J Pediatr Surg* 2000; 35: 634-5. [\[CrossRef\]](#)
6. Bokhan KL. Internal appendicular-intestinal fistula as complication of acute appendicitis. (Russian) *Khirurgiia (Mosk)* 1993; 12: 73-4.
7. Sejdinaj I, McNeil J, Powers RC. Appendico-enteric fistula. *IMJ III Med J* 1971; 140: 505-7.
8. Walker LG Jr, Rhame DW, Smith RB. Enteric and cutaneous appendiceal fistulae. *Arch Surg* 1969; 99: 585-8. [\[CrossRef\]](#)
9. Kawamura YJ, Sugamata Y, Yoshino K, Abo Y, Nara S, Sumita T, et al. Appendico-ileo-vesical fistula. *J Gastroenterol* 1998; 33: 868-71. [\[CrossRef\]](#)

Copyright of Erciyes Medical Journal is the property of Aves Yayincilik Ltd. STI and its content may not be copied or emailed to multiple sites or posted to a listserv without the copyright holder's express written permission. However, users may print, download, or email articles for individual use.