

## Multidisciplinary approach in “pat pat” injuries: the role of vascular surgeon

Okay Güven Karaca<sup>1</sup>, İlhan Mavioglu<sup>1</sup>, Mustafa Haluk Akbaş<sup>1</sup>, Ayşegül Koç<sup>1</sup>, Zekeriya Okan Karaduman<sup>2</sup>, Ayşegül Kunt<sup>3</sup>

<sup>1</sup>Department of Cardiovascular Surgery, Faculty of Medicine Düzce University, Düzce, Turkey

<sup>2</sup>Department of Orthopedics and Traumatology, Faculty of Medicine Düzce University, Düzce, Turkey

<sup>3</sup>Department of Cardiovascular Surgery, Tepecik Training and Research Hospital, Izmir, Turkey

### ABSTRACT

In Turkey, farm machinery accidents are important factors for morbidity and mortality. In Western Black sea region, a specific farming tool is used, called 'Pat Pat'. In our clinic, we operated two patients with multiple lower extremity injuries occurred due to Pat Pat machines. First case had a right Gustilo-Anderson type IIIC open tibial fracture, anterior tibial artery disruption, and a left massive soft tissue defect with popliteal nerve and artery disruption as determined by digital subtraction angiography. The second case had a right Gustilo-Anderson type IV open proximal tibial fracture, distal femoral fracture, and popliteal artery disruption. All injuries of popliteal arteries and veins repaired with saphenous vein interposition. On follow up, we observed that the saphenous vein grafts were thrombosed. We suppose that vascular injuries occurred in those cases due to both penetrating and blunt mechanisms. Repeated thrombectomy was performed, and the patency of the grafts were achieved. Heparin infusion (1000U/hour) was administered in first postoperative 24 hours, and the patient was followed up every hour to keep activated clotting time  $\geq 200$  sec. Consequently, saphenous veins of both cases were protected from thrombosis. In conclusion, combination of penetrating and blunt trauma causing fractures and vascular injury to lower extremities can be managed with coordination of orthopedic, vascular and plastic surgeons. Prompt diagnosis, early intervention, heparin infusion in first 24 hours and continuing with low-molecular-weight heparin results in successful management with palpable distal pulses and limb salvage in those challenging injuries.

**Keywords:** Popliteal artery; popliteal vein; vascular system injuries.

Farm machinery accidents are an important factors for morbidity and mortality in Turkey.<sup>[1]</sup> 'Pat Pat' is one of the specific farming tool used frequently in hazelnut production in Western Blacksea region. It is similar to terrain vehicles, and acts as a small-scale tractor. Moreover, it contains various multifunctional tools. A number of organs including vessels, bones, muscles and nerves may be affected in the accidents occurring with this machine.<sup>[2]</sup> Of one them is vascular injury that only endangers extremities or may be fatal particularly when a rotating blade attachment is used. Herein, we discussed such multi-trauma patients with multiple organ injuries.

### CASE REPORT

**Case 1-** A 60-year-old man applied to the emergency department after a motor vehicle accident, occurred with a vehicle called 'Pat-Pat'. He had a right Gustilo-Anderson type IIIC open tibial fracture, anterior tibial artery disruption, and also a left massive soft tissue defect including popliteal nerve and artery disruption, as determined with digital subtraction angiography (DSA) (Figures 1, 2). Left popliteal artery and right anterior tibial artery injuries were repaired with saphaneous vein interposition, using excision of contralateral saphaneous veins. Then, left tibial

**Received:** October 18, 2016 **Accepted:** December 06, 2016 **Published online:** January 30, 2017

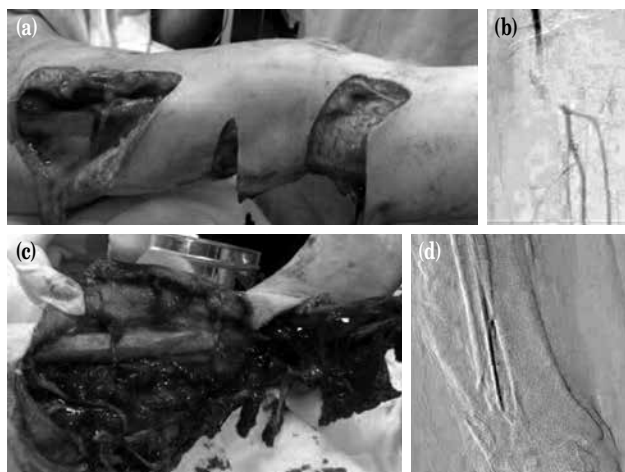
**Correspondence:** Okay Güven Karaca, MD. Düzce Üniversitesi Tıp Fakültesi Kalp ve Damar Cerrahisi Anabilim Dalı, 81000 Düzce, Turkey.  
e-mail: drguven@gmail.com

#### Citation:

Karaca OG, Mavioglu İ, Akbaş MH, Koç A, Karaduman ZO, Kunt A. Multidisciplinary approach in “pat pat” injuries: the role of vascular surgeon. Turk J Vasc Surg 2019;28(1):46-50

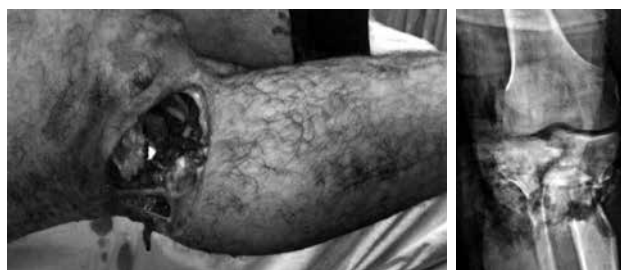The article was presented in 16<sup>th</sup> European Congress of Trauma and Emergency Surgery, May 10-12, 2015, Amsterdam, Netherlands.

©2019 National Vascular and Endovascular Surgery Society. All rights reserved.



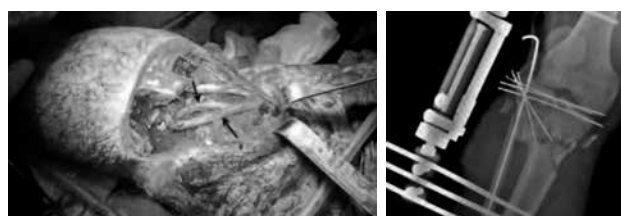
**Figure 1.** (a) Preoperative photograph of left lower extremity of our first case in emergency department. (b) Preoperative angiography showed popliteal artery injury of left lower extremity. (c) Preoperative photograph of right lower extremity of the same patient. (d) Anterior tibial artery injury and the fractures of right tibia and fibula are seen in the preoperative angiography of right lower extremity.

nerve repair, open reduction and internal fixation of right lateral malleolus of tibia and debridement were performed by the orthopedist and neurosurgeon. On control examination two hours later, we observed that the saphenous vein grafts have been thrombosed. Repeat thrombectomy was performed, and the patency of the grafts were achieved; 2 U of erythrocyte suspension and 1 U of fresh frozen plasma were replaced intraoperatively, and the patient was taken to cardiovascular surgery intensive care unit. During postoperative follow-up, four-compartment fasciotomy was performed liberally to prevent compartment syndrome below the open left knee through both medial and lateral longitudinal incisions. Heparin infusion (1000 U/hour) was administered, and the patient was followed by hourly measurements of activated clotting time (ACT). The patient had minimal bleeding, in the style of leakage from the bandage, however heparin infusion was continued, and ACT was kept over 200 seconds. Two units of erythrocyte suspension were replaced on the first postoperative day, and subcutaneous low-molecular-weight heparin (LMWH) (enoxaparin), 1000 IU/10 kg twice daily was given instead of heparin after the first 24 hours. Distal pulses were palpable in both lower extremities on the postoperative examination. Then, the patient was transferred to plastic surgery and orthopedics clinics. The soft tissue defect was reconstructed with free vascularized soft tissue flap transfer by plastic surgeons.



**Figure 2.** Preoperative photograph and X-ray of our second case: Left popliteal artery and vein injuries together with the bone fractures, and near-subtotal amputation are seen.

*Case 2-* A 29-year-old man applied to the emergency department after a motor vehicle accident, occurred with a vehicle called ‘Pat-Pat’. He had a right Gustilo-Anderson type IV open proximal tibial fracture, distal femoral fracture, and popliteal artery disruption. DSA could not be performed due to hemodynamic instability of the patient. Popliteal artery and vein injuries were repaired with saphenous vein interposition (Figure 3). Then, external fixation and debridement were performed by the orthopedist (Figure 3). On the control examination two hours after surgery, we observed that the saphenous vein grafts were thrombosed. Repeat thrombectomy was performed, and patency was achieved. Four-compartment open fasciotomy through both medial and lateral longitudinal incisions were performed liberally intraoperatively because of pending compartment syndrome. 4 U erythrocyte suspension and 1 U fresh frozen plasma were given intraoperatively, heparin infusion (1000 U/hour) was administered, and the patient was followed up every hour for ACT. He was followed up similar to our first patient postoperatively, and only 1 U erythrocyte suspension replacement was made on the first day. After first 24 hours, subcutaneous LMWH (enoxaparin 1000 IU/10 kg, 2×1) was started, and it was seen that bilateral lower extremity distal pulses were palpable in the postoperative course. The patient subsequently developed a massive soft tissue defect in his lower leg. The soft tissue defect was reconstructed with free vascularized soft tissue transfer by plastic surgeons.



**Figure 3.** Perioperative vascular repair with saphenous vein interposition, and postoperative X-ray of our second case.

## DISCUSSION

In Turkey, farm machinery accidents are important factors for morbidity and mortality.<sup>[1]</sup> Similarly, Gerberich et al.<sup>[3]</sup> showed that among all injuries that occurred due to agricultural instruments, 19.8% were caused by the large-scale farming tools, 8.9% with tractors, and 9.4% with farm equipment that could be used with hand and smaller than tractors, and the rest of the injuries were combined injuries. In Western Blacksea region, a farm tool called Pat Pat is used for transportation and agriculture on mountainous areas that are not suitable for agricultural vehicles such as tractors. Karapolat et al.<sup>[2]</sup> reported that Pat Pat-related injuries were more common in the second and fourth decades of life, and could have serious consequences similar to other agricultural tool-related injuries. In the same study, it was reported that the most frequent injuries were head, neck and spine injuries in 53.3% of the patients, followed by thoracic trauma in 42.9%, and upper extremity traumas in 42.9% of the patients.

Fifty percent of all arterial injuries are seen at the extremities.<sup>[4]</sup> Among them, upper extremity arterial injuries are more frequent, but lower extremity arterial injuries are more serious injuries, and generally occur due to trauma. Traumatic injuries cause limb loss and even death.<sup>[4]</sup> Both of our patients admitted with lower extremity arteriovenous injuries, close to the knee.

The patients that are evaluated in the emergency department with open fractures, vascular injury and massive soft tissue defects in lower extremity are important because of the decision of amputation or limb salvage. In the treatment of a severely damaged limb, amputation is decided rather than an attempt of salvage. In 1969, Gustilo designated complicated fractures as types I, II, and III.<sup>[5]</sup> Based on the grade of the injury and the order of poor prognosis, Gustilo et al.<sup>[6]</sup> subdivided type III injuries into three subgroups as III-A, IIIB, and III-C in 1984. The severity of a type III-C fracture alone is reflected by amputation rates that range from 42% to 78%. Furthermore, Russell et al.<sup>[7]</sup> developed a limb injury index, which was based on skin (0 to 1 points), muscle (0 to 2 points), bone (0 to 2 points), nerve (0 to 2 points), vein (0 to 1 points) and arterial injuries (0 to 2 points), and also length of warm ischemia time (0 to 4 points).

In this study, Russell identified the score of the patients who were given amputation decision, as 6 and over. These indexes are able to support the decision of the surgeon by assisting the assessment of viability of the injured limb, and the possibility of success in

salvaging the limb. Several principles were reported to guide the surgeons for decision of amputation.

First, amputation is a collective decision in which the vascular injury may be the least important component. The destiny of the damaged limb is often decided with the degree of nerve, bone, and soft-tissue damages, but for the reconstruction these elements are less amenable than the artery. Secondly, except for open subtotal amputations, the decision of amputation is always given intraoperatively. The damaged limb should be examined carefully under optimally controlled conditions of the operating room. This is the only reliable way to assess the full extent of the damage, and the nerve continuity is a particularly critical factor in the decision.

In a study of Franz et al.,<sup>[4]</sup> arterial injuries were categorized into penetrating mechanisms (56%) and blunt mechanisms (44%). Vascular injuries in our cases probably occurred due to the both types of mechanisms, because of the rotating blade apparatus of the Pat Pat machine.

Early diagnosis is the most important factor in vascular injuries. In the diagnosis of the vascular injury, there are hard and soft signs that helps in the clinic. Clinical evaluation of a vascular injury includes examination of distal pulses, color and temperature of the extremity. Hard signs are active hemorrhage, absent pulses, large expanding hematoma, distal ischemia and bruit or thrill. The soft signs are small hematoma, nerve deficit, diminished distal pulses, and history of arterial bleeding. In one of our two patients, there was a subtotal amputation, and or both patients had no pulse with loss of temperature. Although physical examination is the determining factor in injury, Doppler ultrasonography, computed tomography with contrast angiography (CT-A), multi-detector computerized tomography with contrast angiography (MDCT-A), and magnetic resonance angiography are used in the diagnosis. DSA is still the gold standard for diagnosing arterial lesions in patients with traumatic extremity injuries.<sup>[8]</sup> If the traumatic patient has active bleeding, immediate surgical intervention can be done without imaging.<sup>[9]</sup> In our first case, we used arteriography after initial assessment to establish the exact level of arterial injury. However our second case was unstable, and had a subtotal amputation; therefore he underwent urgent surgery without imaging. Concomitant venous and arterial injuries occur mostly in the superficial femoral and popliteal vessels.<sup>[10]</sup> Similarly, there was accompanying popliteal vein injury in our second case, and the diagnosis was done intraoperatively.

**Table 1. Indications for fasciotomy**

Absolute indications	Potential indications
Tense compartment plus either <ul style="list-style-type: none"> <li>• Pain with passive motion of muscles traversing the same compartment or</li> <li>• Paresis/paresthesias referable to the same compartment</li> </ul>	Acute ischemia >6 h with few collaterals
Tense compartment in a patient who cannot be examined serially due to obtundation or need for other operations	Combined arterial and venous traumatic injuries
Intracompartmental pressure minus mean blood pressure <40 mmHg	Plegmasia serula dolans
Intracompartmental pressure minus diastolic blood pressure <10 mmHg	Tense compartment after crush injury or fracture

The patients that have combination of orthopedic and vascular injuries need coordination of various departments in surgery to provide circulation and stabilize the extremity. If the extremity is viable in presence of a fracture, perfusion may be assessed after reduction, because reduction may basically restore perfusion. Restoration of perfusion is a priority in case of malperfusion.<sup>[10]</sup> Barros suggested that the fractures may be reduced and stabilized either by internal or external fixation before repairing artery and vein.<sup>[11]</sup> Barros also recommended bridging shunts between the ends of injured vessels to avoid ischemia and its pathophysiological sequelae.<sup>[11]</sup> Popliteal vein and accompanying popliteal artery injuries may be repaired with end-to-end anastomoses, saphenous vein interposition grafts obtained from the contralateral lower extremity, primary repairs such as lateral repair and patching, or ringed polytetrafluoroethylene (PTFE) interposition grafts when indicated.<sup>[9]</sup> Ekim et al.<sup>[9]</sup> used saphenous vein interposition or PTFE grafts in treatment, but they performed bone stabilization after vascular surgery. If it is possible, endovascular techniques are employed after imaging. Balloon occlusion and percutaneous transcatheter embolization are available endovascular techniques. In addition, placement of endovascular stents and stent grafts can be alternative to open surgery. We performed saphenous vein interposition in the surgical treatment of our two cases.

Compartment syndrome developed in both of our patients. Compartment syndrome is an emergency situation that is observed as a complication of diverse conditions, and treated by vascular surgeons. The diagnosis of acute compartment syndrome begins with a high index of suspicion. Symptoms of the compartment syndrome include pain that is disproportionate to the magnitude of injury and paresthesia in distal extremity. Intracompartmental pressure (ICP) should be recorded regularly, particularly in case of suspicion, loss of senses, and pediatric patients with suspected compartment syndrome. The most commonly used ICP measuring systems are arterial line manometer,

handheld Stryker system, and White side manometer. It has been recommended that near-infrared spectroscopy and laser Doppler flowmetry may be used as noninvasive techniques to aid identification of an evolving compartment syndrome. We use an arterial line manometer. Clinical criteria for a fasciotomy include a swollen and tense compartment, pain with passive motion of muscle groups which are traversing that compartment, and neurologic findings referable to the compartment. Indications for fasciotomy are summarized in Table 1, as absolute and potential indications.<sup>[12]</sup>

We performed vascular surgery at the beginning of surgery, before the bone stabilization. In our both cases, early thrombosis occurred in the repaired vascular structures. Patency was achieved with repeat thrombectomy surgeries in both of our patients. We supposed that the arterial injury that occurred due to Pat Pat machine included two mechanisms (penetrating and blunt mechanisms). We supposed that 24-hour heparin infusion provided an ACT longer than 200 sec. Then continuing with LMWH may be helpful to prevent thrombosis of grafts, despite bleeding risk in a large tissue injury. In our experience, there was oozing bleeding from the lesions, and 2 U of erythrocyte suspension replacement was needed for our first patient while the only 1 U of erythrocyte suspension replacement was required for our second patient.

Combination of penetrating and blunt traumas generating fractures and vascular injury to lower extremities can be managed in coordination of orthopedic, vascular and plastic surgeons. Prompt diagnosis, early intervention, liberal use of fasciotomy and 24-hour heparin infusion with continuing LMWH resulted in successful management of those difficult injuries with palpable distal pulses, and salvage of the limb.

#### Declaration of conflicting interests

The authors declared no conflicts of interest with respect to the authorship and/or publication of this article.

### Funding

The authors received no financial support for the research and/or authorship of this article.

### REFERENCES

1. Ozturk OH, Eken C. Analysis of the effects of vehicle sales on traffic accidents. *SDÜ Tıp Fak Derg* 2006;13:12-5.
2. Karapolat S, Saritas A, Kandis H, Cikman M, Gezer S, Ozaydin I, et al. The evaluation of Pat-Pat related injuries in the Western Black Sea region of Turkey. *Scand J Trauma Resusc Emerg Med* 2011;19:40.
3. Gerberich SG, Gibson RW, French LR, Lee TY, Carr WP, L Kochevar et al. Machinery-related injuries: regional rural injury study-I (RRIS-I). *Accid Anal Prev* 1998;30:793-804.
4. Franz RW, Shah KJ, Halahavi D, Franz ET, Hartman JF, Wright ML. A 5 year review of management of lower extremity arterial injuries at an urban level I trauma center. *J Vasc Surg* 2011;53:1604-10.
5. Gustilo RB, Anderson JT. Prevention of infection in the treatment of one thousand and twenty-five open fractures of long bones: retrospective and prospective analyses. *J Bone Joint Surg [Am]* 1976;58:453-8.
6. Gustilo RB, Mendoza RM, Williams DN. Problems in the management of type III (severe) open fractures: a new classification of type III open fractures. *J Trauma* 1984;24:742-6.
7. Russell WL, Sailors DM, Whittle TB, Fisher DF Jr, Burns RP. Limb salvage versus traumatic amputation. A decision based on a seven-part predictive index. *Ann Surg* 1991;213:473-80.
8. Levy BA, Zlowodzki MP, Graves M, Cole PA. Screening for extremity arterial injury with the arterial pressure index. *Am J Emerg Med* 2005;23:689-95.
9. Ekim H, Basel H, Odabasi D. Management of traumatic popliteal vein injuries. *Injury* 2012;43:1482-5.
10. McCready RA, Logan NM, Daugherty ME, Mattingly SS, Crocker C, Hyde GL. Long-term results with autogenous tissue repair of traumatic extremity vascular injuries. *Ann Surg* 1987;206:804-8.
11. Barros D'Sa AA, Harkin DW, Blair PH, Hood JM, McIlrath E. The Belfast approach to managing complex lower limb vascular injuries. *Eur J Vasc Endovasc Surg* 2006;32:246-56.
12. Chunk J, Modrall JG. Compartment syndrome. In: Cronenwett JL, Johnston WJ, editors. *Rutherford's Vascular Surgery*. 8th ed. Philadelphia: WB Saunders; 2014. p. 2544-54.