



ORIGINAL RESEARCH

Medicine Science 2018;7(4):848-51

## Relationship between adnexal mass and endometrial thickness in postmenopausal period

Alper Basbug<sup>1</sup>, Ozan Dogan<sup>2</sup>, Murat Yassa<sup>3</sup>, Cigdem Pulatoglu<sup>4</sup>, Aski Ellibes Kaya<sup>1</sup>, Eray Caliskan<sup>5</sup>

<sup>1</sup>Duzce University Hospital Department of Obstetrics and Gynecology, Duzce, Turkey

<sup>2</sup>Health Sciences University, Sisli Hamidiye Etfal Research and Training Hospital Department of Obstetrics and Gynecology, Istanbul, Turkey

<sup>3</sup>Health Sciences University, Fatih Sultan Mehmet Training and Research Hospital Department of Obstetrics and Gynecology, Istanbul, Turkey

<sup>4</sup>Bayburt Government Hospital Department of Obstetrics and Gynecology, Bayburt, Turkey

<sup>5</sup>Bahcesehir University School of Medicine, Department of Obstetrics and Gynecology, Istanbul, Turkey

Received 18 May 2018; Accepted 04 June 2018

Available online 10.09.2018 with doi:10.5455/medscience.2018.07.8874

Copyright © 2018 by authors and Medicine Science Publishing Inc.

### Abstract

Endometrial cancer is the most common gynecological cancer. Increased postmenopausal endometrial thickness may be an indicator of endometrial cancer. Transvaginal ultrasound (TV-USG) is the primary imaging method for evaluating endometrial thickness in the postmenopausal period. The aim was to employ transvaginal ultrasonography in the evaluation of adnexal masses synchronously seen in postmenopausal women with increased endometrial thickness. The work was designed as a retrospective study. The medical records of 155 patients evaluated for increased postmenopausal endometrial thickness were examined. Ultrasonography had been performed on the women in the study for routine follow-up, postmenopausal hemorrhage, pelvic pain, pelvic mass on examination and family history of gynecological cancer. All patients had undergone endometrial evaluation with fractional dilatation and curettage (D & C) or pipelle endometrial sampling. Histopathological diagnosis was based on endometrial sampling results. Adnexal mass was present simultaneously in 17.4% (n = 27) of the women included in the study, while 82.6% (n = 128) had no gynecological pathology other than increased endometrial thickness. The endometrial thickness in the women with postmenopausal adnexal masses was greater than in those without adnexal mass (11.7 mm vs. 7.8 mm, p = 0.009). Non-atypical and atypical endometrial hyperplasia was more frequent in the group with postmenopausal adnexal mass (11.1% vs. 2.8%, 11.1% vs. 3.79, p = 0.03, p = 0.04, respectively). Final histopathological evaluation of patients operated on for adnexal masses revealed tubo-ovarian abscess in 1.9% (n = 1), benign ovarian tumor in 25.9% (n = 7) and malignant ovarian tumor in 11.1% (n = 3) of the patients. In postmenopausal women, adnexal masses can be seen simultaneously with increased endometrial thickness. In this regard, transvaginal ultrasound offers important opportunities for evaluation of both the endometrium and adnexa. Pre-surgery transvaginal ultrasound as well as multivariate serum markers may be used in evaluation models.

**Keywords:** Adnexal masses, endometrial thickness, postmenopausal women

### Introduction

Endometrial cancer is the most common gynecological cancer and its frequency has risen gradually over the past 20 years [1]. Increased postmenopausal endometrial thickness as detected by sonography may be an indicator of endometrial cancer. Transvaginal ultrasound (TV-USG) is the primary imaging method for evaluating increase in endometrial thickness in the postmenopausal period [2,3]. When a thickness of the endometrium of more than 5 mm is detected in postmenopausal women by TV-USG, histopathological examination may be required [4,5]. In addition, TV-USG provides significant contributions in the imaging display of the adnexa. Although the efficacy of TV-USG for asymptomatic women in the screening for ovarian cancer is controversial, during assessment of the endometrium, the adnexa can be assessed simultaneously and

abnormal findings recorded [6,7]. Postmenopausal adnexal mass is an important clinical condition that is usually detected incidentally, and thus gynecologists may experience some difficulties in follow-up or treatment [8]. Because many are benign, a good evaluation of these masses can defer the diagnosis of ovarian cancer and prevent unnecessary surgery [9].

There is insufficient evidence in the literature showing that increased postmenopausal thickness may be associated with adnexal masses. In the postmenopausal period, except for ovarian tumors that can continue hormonal activity, there is no information about adnexal masses that are synchronous with increased endometrial thickness [10]. In this study, we evaluated the possibility of postmenopausal adnexal masses being synchronous with increased endometrial thickness.

### Materials and Methods

#### Study design

This retrospective study included a total of 155 women who had

\*Corresponding Author: Ozan Dogan, Health Sciences University, Sisli Hamidiye Etfal Research and Training Hospital Department of Obstetrics and Gynecology, Istanbul, Turkey  
E-mail: [ozandogan02@hotmail.com](mailto:ozandogan02@hotmail.com)

undergone endometrial biopsy for increased postmenopausal endometrial thickness at the Düzce University Medical Faculty Obstetrics and Gynecology Clinic between January 2015 and January 2017. Patients who had hormone replacement therapy because of menopause, who had a history of gynecological cancer and those diagnosed with endometrial hyperplasia in previously excised biopsies were not included in the study. Written informed consent was obtained from all women before the study commenced. All procedures in the study were carried out in accordance with the ethical standards of the institutional research committee and in accordance with the Helsinki Declaration of 1964 and subsequent amendments or comparable ethical standards. The study was approved by the Düzce University Ethics Committee (Ethics Committee No. 2017/07). This study followed the Strengthening the Reporting of Observational studies in Epidemiology (STROBE) guidelines

Ultrasonography had been performed on the women in the study for various reasons including routine follow-up, postmenopausal hemorrhage, pelvic pain, pelvic mass on examination and family history of gynecological cancer. All sonographic evaluations were performed using a 6.5 MHz endovaginal probe with the patient at the lithotomy position and having an empty bladder. The cutoff value for increased postmenopausal endometrial thickness was taken as 5 mm [4,5].

The medical records of the patients were examined in terms of demographic characteristics such as age, body mass index (BMI), age at menopause, gravida and parity. All patients had undergone endometrial evaluation with fractional dilatation and curettage (D & C) or pipette endometrial sampling. Histopathological diagnosis was based on endometrial sampling results. Histopathological results were classified as benign, endometrial polyp, endometritis, endometrial hyperplasia, or endometrium cancer. Proliferative endometrium, secretory endometrium, irregular and atrophic endometrium were considered as benign histologic changes.

We did not perform the power or sample size calculation for this study, because we planned to include all eligible patients in the study. The Statistical Package for the Social Sciences (SPSS) 22.0 program was used to analyze the data. Quantitative data were tabulated with mean  $\pm$  SD (standard deviation) and median (maximum-minimum) values, while categorical data were given as n (number) and percent (%). The Student's t-test and Mann-Whitney U test were used to compare independent groups, whereas the Pearson Chi-Square and Fisher Exact tests were used to compare categorical data. The data were analyzed at 95% confidence level, with a p-value of 0.05 considered as significant, while greater than 0.05 was considered insignificant.

## Results

A total of 155 women who had presented at our clinic and who had undergone sonographic evaluation for increased postmenopausal endometrial thickness were included in the study. Adnexal mass was present simultaneously in 17.4% (n = 27), while 82.6% (n = 128) had no gynecological pathology other than increased endometrial thickness. No statistically significant difference was seen in terms of age, gravida, parity, BMI or comorbid chronic diseases (Table 1). The number using tamoxifen because of breast cancer was greater amongst the group with simultaneous increased

postmenopausal endometrial thickness and adnexal masses than in the group without adnexal masses. The difference between the groups was statistically significant (7.4% vs. 2.8%, p = 0.04).

**Table 1.** Demographic data of patients included in the study

	Postmenopausal adnexal mass (+) (n=27)	Postmenopausal adnexal mass (-) (n=128)	p-value
<b>Age</b>	57.75 $\pm$ 11.89	60.44 $\pm$ 9.32	0.11
<b>Menopause duration</b>	11.23 $\pm$ 7.65	10.28 $\pm$ 8.11	0.29
<b>Gravida</b>	5 (0-12)	4 (0-12)	0.35
<b>Parity</b>	4 (0-12)	3 (0-10)	0.22
<b>BMI (kg/m<sup>2</sup>)</b>	33.60 $\pm$ 3.90	31.62 $\pm$ 3.12	0.23
<b>Concomitant systemic disease</b>			
Diabetes Mellitus	5 (18.5%)	19 (15.2%)	0.69
Hypertension	11 (40.7%)	42 (32.8%)	0.06
Hypothyroidism	3 (11.1%)	13 (10.3%)	0.34
Hyperthyroidism	4 (14.8%)	10 (7.9%)	0.26
Chronic vascular disease	3 (11.9%)	9 (6.7%)	0.23
<b>Tamoxifen use</b>	2 (7.4%)	4 (2.8%)	0.04*

Values are expressed as mean  $\pm$  standard deviation, median (min-max) and %.  
BMI: Body mass index

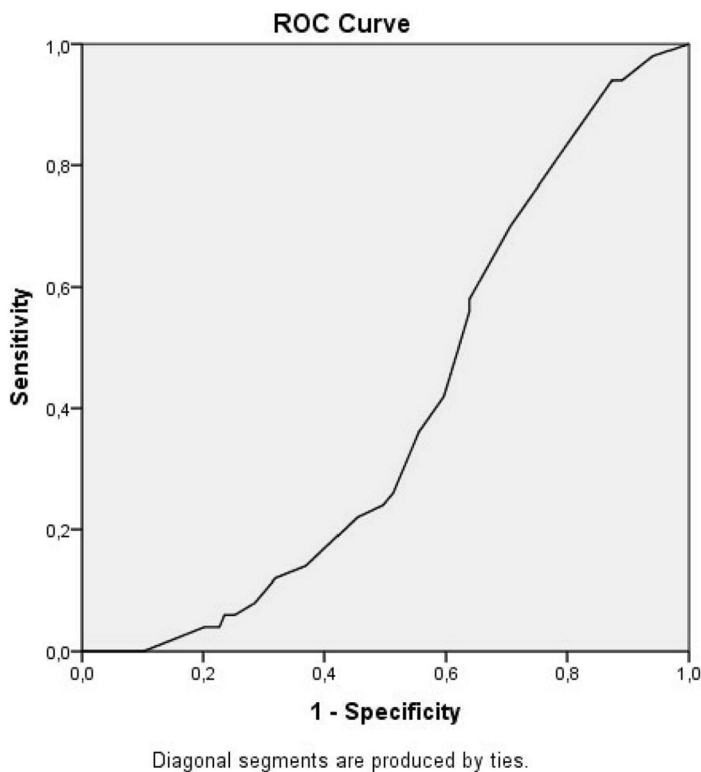
Women with postmenopausal adnexal masses had greater endometrial thickness than women without adnexal mass and the difference between the groups was statistically significant (11.7 mm vs 7.8 mm, p = 0.009). Histopathological examination of endometrial biopsy specimens showed benign endometrial tissues, endometrial polyps, endometritis and malignancy in similar proportions, whereas non-atypical and atypical endometrial hyperplasia was more frequent in the group with postmenopausal adnexal mass (11.1% vs. 2.8%, 11.1% vs. 3.9%; p = 0.03, p = 0.04, respectively). Of the patients, 59.2% (n = 16) were put under observation and 40.8% [11] were operated on. Final histopathological evaluation of patients operated on for adnexal masses revealed tubo-ovarian abscess in 1.9% (n = 1), benign ovarian tumor in 25.9% (n = 7) and malignant ovarian tumors in 11.1% (n = 3) of the patients (Table 2).

**Table 2.** Sonographic and histopathological results of the patients included in the study

	Postmenopausal adnexal mass (+) (n=27)	Postmenopausal adnexal mass (-) (n=128)	p-value
<b>Endometrial thickness (mm)</b>	11.73 $\pm$ 5.97	7.81 $\pm$ 2.82	0.009*
<b>Endometrial histopathological evaluation</b>			
Benign	16 (59.2%)	82 (63.7%)	0.12
Endometrial polyp	3 (11.1%)	26 (19.7%)	0.09
Endometritis	1 (3.3%)	4 (3.5%)	0.65
Non-atypical endometrial hyperplasia	3 (11.1%)	3 (2.8%)	0.03*
Atypical endometrial hyperplasia	3 (11.1%)	5 (3.9%)	0.04*
Endometrium cancer	1 (3.7%)	8 (6.3%)	0.16
<b>Final histopathological result of adnexal mass after surgery</b>			
Tubo-ovarian abscess	1 (3.7%)		
Benign ovarian tumor	7 (25.9%)		
Malignant ovarian tumor	3 (11.1%)		

Values are expressed as mean  $\pm$  standard deviation and %.

Figure 1 shows the estimated diagnostic performance for adnexal mass synchronous with increase in endometrial thickness as measured by TV-USG. Accordingly, the area remaining under the ROC curve was 0.39 [95% CI (0.31-0.48)].



**Figure 1.** ROC curve for detection of adnexal mass with endometrial thickness measurement via TV-USG

## Discussion

Findings from our study show that 17.4% of patients with increased postmenopausal endometrial thickness had synchronous adnexal masses. The mean endometrium thickness was higher and both atypical and non-atypical endometrial hyperplasia were more common in the women with postmenopausal adnexal mass. However, the diagnostic performance was low for measurement of postmenopausal endometrial thickness with synchronous adnexal mass.

Because of its high efficacy and non-invasiveness, TVUSG is used routinely in the evaluation of the postmenopausal endometrium. In general, this is done to rule out endometrial cancer [11,12]. Another problem seen in the postmenopausal period is adnexal masses. The use of TV-USG has been long acknowledged as a means of distinguishing benign and malign adnexal masses, but the method depends on the experience and evaluation of the person performing the ultrasonography. Thus, ultimately, the accuracy and reliability of the technique are based on subjective judgment. In many studies, the sensitivity and specificity of TV-USG has been reported as 80% and 60%, respectively, in distinguishing between benign and malignant adnexal masses [13,14]. Bakour et al. noted that adnexal mass was detected synchronously in 4.9% of the patients in their study who complained of postmenopausal hemorrhage, and that less than 10% of them were malignant; however, increased endometrial thickness was not evaluated in

this study [7]. In our study, the incidence of malignant ovarian tumors in women with adnexal mass and synchronous increased postmenopausal endometrial thickness was found to be 11%.

Long-term studies have been carried out on the screening of postmenopausal patients for gynecological cancers. Early on in these studies, postmenopausal women were recommended to undergo a full pelvic scan during ultrasonographic evaluation [15,16]. However, in recent years, some authors have suggested that due to the suboptimal specificity of TV-USG, adnexal scanning increases both the duration and cost of screening and exposes women to unnecessary surgical interventions and their complications, and if no pathological finding is found on the physical pelvic examination and if the endometrium is sonographically normal, there is no need for the adnexa to be seen [17,6]. The results from our study show that in postmenopausal women, atypical and non-atypical endometrial hyperplasia, in particular, may be synchronous with adnexal masses. Therefore, we believe that patients with endometrial hyperplasia detected as a result of histopathological examination should be screened by ultrasonography if they have not been previously evaluated.

Various algorithms have been developed for the management of asymptomatic postmenopausal adnexal masses [18,19]. When serum markers such as Ca-125 and HE-4 are at normal levels, the observational approach is reasonable here. Patients can be checked again at intervals of 3-6 months. In these patients, the TV-USG findings alone should not be used to determine the surgical decision, but also the doppler USG and, if necessary, tomography and MRI. Multivariate evaluation models such as the Simple Rules Risk (SRrisk) score, Risk of Malignancy Index (RMI), Risk of Ovarian Cancer Algorithm (ROCA), and Risk of Ovarian Malignancy Algorithm (ROMA) can be used with both imaging and serum markers [20,21]. With postmenopausal patients having incidentally detected adnexal masses, the task of the gynecologists is to counsel them after undergoing TV-USG and, if deemed necessary, to refer them to gynecological oncologists. The data obtained with TV-USG alone may be insufficient. Making decisions only from TV-USG results in unnecessary anxiety in patients, and their possible exposure to unnecessary surgical procedures and resulting complications. Of the women with postmenopausal adnexal masses who participated in our study, 26.6% had undergone surgery for benign gynecological reasons.

There are very few studies in the literature regarding postmenopausal endometrial pathologies and adnexal mass synchronization. In this study, symptomatic patients with postmenopausal hemorrhage or adnexal mass detectable on physical examination were evaluated. In this respect, our study can provide a strong base for future studies assessing asymptomatic patients. The retrospective nature of the study and the relatively low number with postmenopausal adnexal masses in the group can be seen as limitations of the study.

## Conclusion

In conclusion, adnexal masses may be synchronous with increased postmenopausal endometrial thickness, but it should be kept in mind that a large majority of these masses may be benign. The TV-USG is a diagnostic tool that can simultaneously provide important contributions to both the examination of the endometrium and to the diagnosis of synchronous adnexal masses. In addition to TV-

USG, evaluation models using multivariate serum markers can be used for distinguishing malignant adnexal masses.

#### Competing interests

*The authors declare that they have no competing interest*

#### Financial Disclosure

*The financial support for this study was provided by the investigators themselves.*

#### Ethical approval

*Before the study, permissions were obtained from local ethical committee.*

#### References

1. Timmermans A, Opmeer BC, Khan KS, et al. Endometrial thickness measurement for detecting endometrial cancer in women with postmenopausal bleeding: A systematic review and meta-analysis. *Obstet Gynecol.* 2010;116:160-7.
2. Gupta JK, Chien PFW, Voit D, et al. Ultrasonographic endometrial thickness for diagnosing endometrial pathology in women with postmenopausal bleeding: A meta-analysis. *Acta Obstet Gyn Scan.* 2002;81:799-816.
3. Tabor A, Watt H C, Wald N J. Endometrial thickness as a test for endometrial cancer in women with postmenopausal vaginal bleeding. *Obstetrics & Gynecology.* 2002;99:663-70.
4. Goldstein SR. The endometrial echo revisited: Have we created a monster? *Am J Obstet Gynecol.* 2004;191:1092-96.
5. Kanat-Pektas M, Gungor T, Mollamahmutoglu L. The evaluation of endometrial tumors by transvaginal and doppler ultrasonography. *Arch Gynecol Obstet.* 2008;277:495-99.
6. Rosenthal AN, Fraser L, Manchanda R et al. Results of annual screening in phase 1 of the united kingdom familial ovarian cancer screening study highlight the need for strict adherence to screening schedule. *J Clin Oncol* 2013;13:49-57.
7. Bakour S, Emovan E, Nevin Jet al. Is routine adnexal scanning for postmenopausal bleeding of value? Observational study of 2101 women. *J Obstet Gynaecol.* 2017;37:779-82.
8. American College of Obstetricians and Gynecologists. Management of adnexal masses. *ACOG Practice Bulletin No. 83.* *Obstet Gynecol.* 2007;110:201-14.
9. Kaijser J, Van Hoorde K, Van Calster B, et al. Diagnosing adnexal tumours before surgery: A critical appraisal of recent evidence. *TOG.* 2015;17:163-71.
10. Famuyide AO, Shazly SA, Makdisi PB, et al. Impact of simple ovarian cysts on the interpretation of endometrial thickness in women with postmenopausal bleeding. *J Womens Health.* 2016;9:889-96.
11. Wolfman W, Leyland N, Heywood M, et al. Asymptomatic endometrial thickening. *J Obstet Gynaecol Can.* 2010;32:990-9.
12. Dueholm M, Marinovskij E, Hansen ES, et al. Diagnostic methods for fast-track identification of endometrial cancer in women with postmenopausal bleeding and endometrial thickness greater than 5 mm. *Menopause.* 2015;22:616-26.
13. Valentin L, Hagen B, Tingulstad S, et al. Comparison of pattern recognition and logistic regression models for discrimination between benign and malignant pelvic masses: A prospective cross validation. *Ultrasound Obstet Gynecol.* 2001;18:357-65.
14. Timmerman D, Schwarzler P, Collins WP, et al. Subjective assessment of adnexal masses with the use of ultrasonography: An analysis of interobserver variability and experience. *Ultrasound Obstet Gynecol.* 1999;13:11-6.
15. Gredmark T, Kvint S, Havel G, et al. Histopathological findings in women with postmenopausal bleeding. *BJOG.* 1995;102:133-6.
16. Gupta JK, Wilson S, Desai P, et al. How should we investigate women with postmenopausal bleeding? *Acta Obstet Gyn Scan.* 1996;75:475-9.
17. Sharma A, Gentry-Maharaj A, Burnell M, et al. Assessing the malignant potential of ovarian inclusion cysts in postmenopausal women within the UK Collaborative Trial of Ovarian Cancer Screening (UKCTOCS): A prospective cohort study. *BJOG.* 2012;119:207-19.
18. Myers ER, Bastian LA, Havrilesky LJ, et al. Management of adnexal mass. *Evid Rep Technol Assess.* 2006;130:1-145.
19. van Nagell JR, DePriest PD. Management of adnexal masses in postmenopausal women. *Am J Obstet Gynecol.* 2005;193:30-35.
20. Ueland FR, Desimone CP, Seamon LG, et al. Effectiveness of a multivariate index assay in the preoperative assessment of ovarian tumors. *Obstet Gynecol.* 2011;117:1289-97.
21. Hentze JL, Høgdall C, Kjær SK, et al. Searching for new biomarkers in ovarian cancer patients: Rationale and design of a retrospective study under the Mermaid III project. *Contemp Clin Trials Commun.* 2017;13:167-74.