

The diagnosis to be kept in mind in resistant epilepsy; tuberous sclerosis

Dirençli epilepside akılda tutulması gereken tanı; tuberoskleroz

Fatih Kurt^{ORCID}, Recep Eröz^{ORCID}, Mustafa Doğan^{ORCID}

Atf/Cite as: Kurt F, Eröz R, Doğan M. The diagnosis to be kept in mind in resistant epilepsy; Tuberous sclerosis. Northwestern Med J.2022;2(1):59-64.

ABSTRACT

Drug-Resistant Epilepsy is the continuation of seizures despite administering two tolerable antiepileptic drugs at the appropriate dose and time, which are selected according to the type of seizure. Growth retardation, focal neurological findings, organic brain lesions, specific EEG disorders, and epilepsy in the family are risk factors for resistant epilepsy. Tuberous sclerosis is a multisystemic and autosomal dominant genetic disease with hamartomas in many organs such as the skin, central nervous system, kidney, and lungs. Brain hamartomas and other central nervous system lesions cause resistant epilepsy in tuberous sclerosis.

In this article, we present a 16-year-old patient with tuberous sclerosis who was followed up with the diagnosis of resistant epilepsy, despite typical physical examination findings. This research emphasised that tuberous sclerosis should be kept in mind in the aetiology of resistant epilepsy and how important physical examination is.

Keywords: tuberous sclerosis, resistant epilepsy, TSC2 gene

ÖZ

İlaça Dirençli epilepsi; nöbet tipine uygun seçilmiş, tolere edilebilen iki antiepileptik ilacın uygun doz ve sürede verilmesine rağmen nöbetlerin devam etmesidir. Gelişme geriliği, fokal nörolojik bulguların olması, organik beyin lezyonu olması, spesifik EEG bozukluğu ve ailede epilepsi varlığı dirençli epilepsi açısından risk faktörleridir.

Tuberoskleroz hastalığı deri, merkezi sinir sistemi, böbrek ve akciğer gibi birçok organda hamartomlarla seyreden, multisistemik, otozomal dominant geçişli genetik bir hastalıktır. Tuberoskleroz hastalığında görülen beyin hamartomları ve diğer santral sinir sistemi lezyonları dirençli epilepsinin ortaya çıkmasına neden olmaktadır.

Bu yazıda dirençli epilepsi tanısıyla takip edilen, tipik fizik muayene bulguları olmasına rağmen 16 yaşında Tuberoskleroz tanısı alan hasta sunuldu. Dirençli epilepsi etyolojisinde Tuberosklerozun akılda tutulması gerektiği ve fizik muayenenin ne kadar önemli olduğunu tekrar vurgulanmak istendi.

Anahtar kelimeler: tuberoskleroz, dirençli epilepsi, TSC2 geni

Received: 05.24.2021

Accepted: 12.16.2021

Publication date: 01.05.2022

Corresponding Author:

F. Kurt

ORCID: 0000-0003-1975-6492

Duzce Ataturk State Hospital,

Pediatrics Clinic, Duzce, Turkey

✉ fatihkurt_04@hotmail.com

R. Eröz

ORCID: 0000-0003-0840-2613

Duzce University, Faculty Of

Medicine, Department Of Genetics,

Duzce, Turkey

M. Doğan

ORCID: 0000-0003-0464-6565

Turgut Özal University, Faculty of

Medicine, Department of Genetics,

Malatya, Turkey

INTRODUCTION

According to the definition of the International League Against Epilepsy, drug-resistant epilepsy is when seizure-freeness cannot be achieved despite the administration of two tolerable antiepileptic drugs (monotherapy or combined) at the appropriate dose and time (1-4). Growth retardation, focal neurological findings, organic brain lesions, specific EEG disorders, and epilepsy in the family are risk factors for resistant epilepsy (5). Brain hamartomas in tuberous sclerosis cause resistant epilepsy (6).

This article presents clinical and laboratory findings of an adolescent male patient with tuberous sclerosis and refractory epilepsy. It emphasised the importance of physical examination in diagnosing tuberous sclerosis and keeping tuberous sclerosis in mind in the differential diagnosis of resistant epilepsy cases.

CASE REPORT

The 16-year-old patient whose seizures could not be controlled despite the use of ≥ 2 antiepileptic drugs, who had been followed up for generalised tonic-clonic seizures since the age of one, presented to the paediatrics clinic. Although the patient had been using Valproate, Levetiracetam, Topiramate, Vigabatrin, and Diazepam for the past year at appropriate doses, it was learned that the patient had generalised tonic-clonic seizures lasting approximately 10 minutes, 4-5 times a week.

His parents informed that the developmental stages of the patient up to 1-years-old were compatible with his peers. The patient does not go to school because he has frequent seizures. He has a learning disability and can not take care of himself independently.

Light reflexes were obtained in both eyes in the patient's physical examination. He was conscious, oriented, and cooperative. His neurological examination, muscle strength and cerebellar

tests were normal. There were 5 hypopigmented macules in the right lower extremity sural region, the largest of which were 0.5x3 cm in size, 1 in the gluteal region of the left lower extremity, and 1 in the right scapula, 1x3 cm in size (Figure 1a, b, c). Multiple angiofibromas are present in the nose, nasolabial folds, and cheeks (Figure 1d). It was learned that the patient's hypopigmented lesions were congenital, and the angiofibromas on the face began to develop at the age of 14. It was learned that the patient's echocardiography and abdominal ultrasound (USG) were normal. His urinary system USG was normal, and there was no nodular lesion or renal angiomyolipoma. No retinal hamartoma was detected on the ophthalmological examination. In brain magnetic resonance imaging (MRI), cortical atrophy and signal increases in both periarterial white matter and vertex level in the white matter compatible with gliosis were found. It has been reported that focal epileptiform abnormalities were detected in his electroencephalography (EEG).

In the genetic examination of the patient, the change in the TSC2 gene in exon 40 (c.5252_5259 + 19del) (NM_000548.5) was heterozygous. There was no kinship between the patient's mother and father. His father and his 13-year-old brother also had hypopigmented macules. In contrast, hypopigmented macules and angiofibroma were not detected in his mother and 7-year-old sister (Figure 2). The patient was referred to suitable clinics for further examinations and a genetic examination.

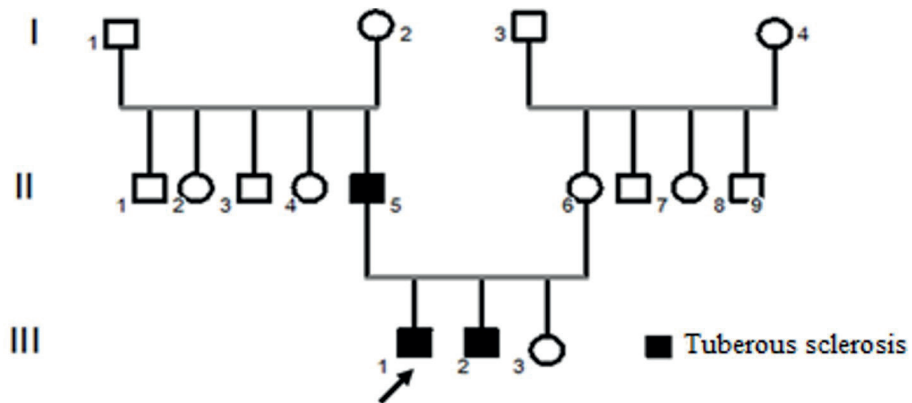
The family was informed about the article, and the informed consent form was signed.

DISCUSSION

Tuberous sclerosis, which Desire-Magloire Bourneville first described as 'Bourneville disease' in 1880, is a multisystemic, autosomal dominant genetic disease with hamartomas in many organs such as the skin, central nervous system, kidney, and lungs. Tuberous sclerosis approximately affects one in 10,000 newborns, and most

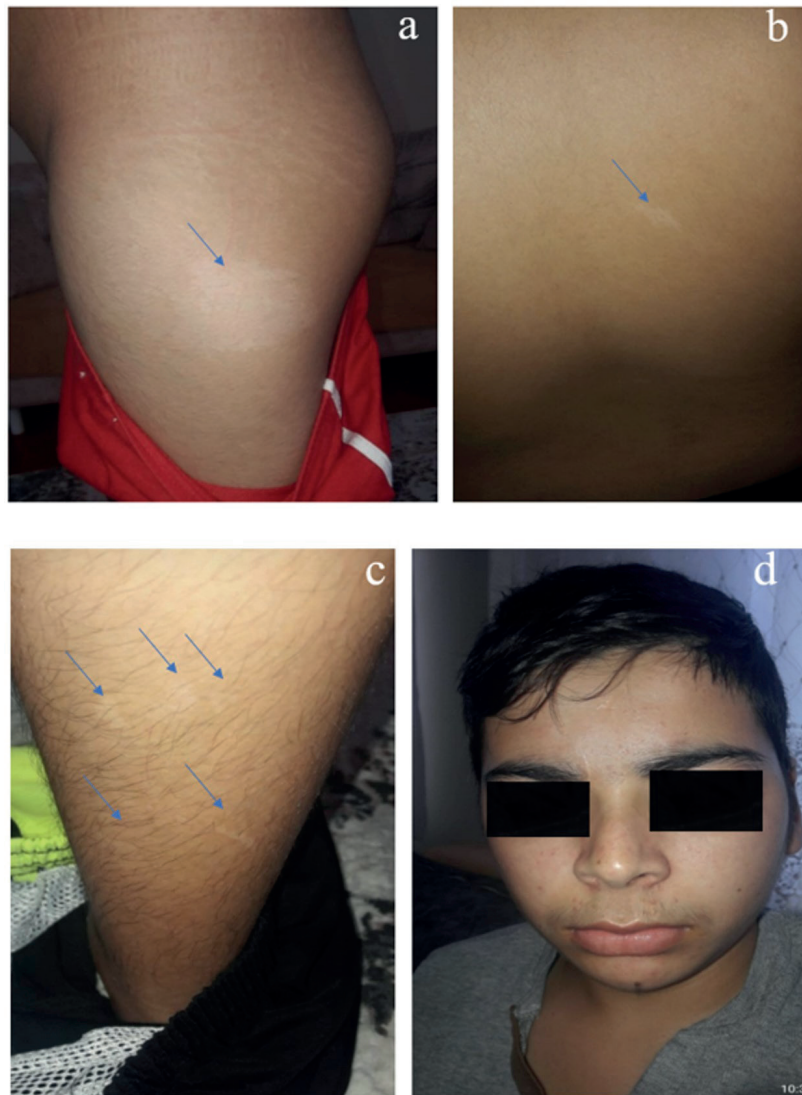

Figure 1. Hypopigmented macules, the largest being 5x4 cm and the smallest 0.5x1 cm in both lower extremities and right scapular region (a, b, c), angiofibromas in the facial area (d).



c.5252_5259 + 19del (rs137854397)

heterozygous mutation in exon 40 of *TSC2* gene

Figure 2. Pedigree of the patient and *TSC2* gene c.5252_5259 + 19del rs137854397 heterozygous mutation in exon 40.

Table 1. Tuberous sclerosis Diagnostic Criteria.

Diagnostic Criteria	The patient
1-hypomelanotic macules (3 or more, at least 5 mm diameter)	+
2-angiofibromas (3 or more) or fibrous cephalic plaque	+
3-non-traumatic unguar or periunguar fibroma (2 or more)	-
4-shagreen patch	-
5-multiple retinal nodular hamartomas	-
6-cortical dysplasias (include tubers and cerebral white matter migration lines)	+
7-subependymal nodule	-
8-subependymal giant cell astrocytoma	-
9-cardiac rhabdomyoma	-
10-lymphangiomyomatosis (LAM)*	-
11-angiomyolipomas	-
1-dental enamel pits: 3 or more for the entire dentition	-
2-intraoral fibromas (2 or more)	-
3-non-renal hamartomas	-
4-retinal achromic patch	-
5-'confetti' skin lesions	-
6-multiple renal cysts	-

Definitive TS complex: either 2 major features or 1 major and 2 or more minor

Possible TS complex: either 1 major or ≥2 minor

patients are diagnosed in the first 15 months of life. Diagnosis of some patients is delayed due to wide phenotypic variability (6,7). The TSC2 gene located in the chromosome 16p13 region produces the tuberlin, while the TSC1 gene located in the 9p34 region produces hamartin. Tuberlin and hamartin play a role in intracellular signal transduction (8). Failure of TSC1 (9q34) and TSC2 (16p13) tumour suppressor genes causes mTOR activation to increase in cells, increase in cell size and growth (3,4). Tuberous sclerosis complex has 3 components: epilepsy, mental retardation, and cutaneous angiofibromas. Cortical tubers, subependymal nodules, subependymal giant cell astrocytoma, and white matter abnormalities are central nervous system findings. Such abnormalities are blamed for epilepsy, mental retardation, and behavioural disorders (6,9). Cortical tubers are present in 95% of patients (10). In the patient's brain MRI, cortical atrophy and signal increases compatible with gliosis in the periarterial white matter and vertex levels were detected (Table 1).

Table 2. Pathogenicity of TSC2 Variants.

GENE	TSC2
Genbank transcript ID	NM_000548.5
Chromosomal Locus	16p13.3
dbSNP	rs137854397
Variant	c.5252_5259+19del
Variant Location	Exon 41
Variant Type	Deletion
Varseak	Splice junction loss
GnomAD exomes	No entry
ClinVAR	pathogenic
Conservation	protected
DANN score	No data
ACMG Classification	Pathogenic
ACMG Pathogenicity Criteria	PVS1,PM2,PP3,PP5

TSC2: Tuberous Sclerosis Complex 2

ACMG: The American College of Medical Genetics and Genomics

Hypopigmented macules, confetti-style skin lesions, facial angiofibromas, fibrous plaques, unguar fibromas, and shagreen patches are skin lesions seen at a frequency of 81-95% in tuberous sclerosis. Hypomelanotic macules and fibrous plaques occur earlier than typical facial angiofibromas and periunguar fibromas. In addition, dental pitting can be seen in the teeth (11). The patient had 7 hypopigmented macules in both lower extremities and the right scapula region, the largest being 5x4 cm and the smallest 0.5x1 cm. He also had angiofibromas on the face.

Cardiac rhabdomyoma is the most common heart tumour and is considered a hamartoma of cardiac myocytes. Approximately 75% of affected children are 1-years-old, and 33% are 1-month-old. Cardiac rhabdomyoma is associated with tuberous sclerosis complex (TSC) in 50-86% of cases (12). Rhabdomyomas usually regress spontaneously (13). ECHO of the patient, whose echocardiography (ECHO) was not taken before the application, was normal. It is not possible to comment on the presence of rhabdomyoma in the first years of the patient's life, considering that it regresses spontaneously.

Renal pathologies such as simple cysts, polycystic kidney disease, and renal cell carcinoma are the most common in tuberous sclerosis complex (50-80%) (14). No pathology was found in the urinary USG of the patient.

Tuberous sclerosis cases with hepatic angiomyolipoma have been reported in the literature. It has been reported that renal angiomyolipoma and TSC2 gene mutation are present in all cases with hepatic angiomyolipoma (15,16). No abnormal finding was found in the patient's abdominal USG. Retinal astrocytic hamartoma, one of the most important criteria for diagnosing tuberous sclerosis complex, is approximately seen in 50% of patients. In infancy, bilateral hamartomas are seen in 30% of tuberous sclerosis patients (17,18). No retinal hamartoma was detected in the patient's eye examination.

The malfunction of TSC1 (9q34) and TSC2 (16p13) tumour suppressor genes in tuberous sclerosis patients cause these cells to increase in size and grow (4). It shows autosomal dominant inheritance (2). TSC2 mutations (55-90%) are more common (19). In the genetic examination of the patient, a c.5252_5259 + 19del heterozygous mutation was found in exon 40 of the splice-site (mutation that disrupts splicing) TSC2 gene. This variant has been previously described in the literature (rs137854397) and has been associated with tuberous sclerosis compatible phenotypes. This change was evaluated with the patient's clinical findings, in silico analysis data, and family segregation data. It was evaluated as Class 1 and a pathological mutation according to the American College of Medical Genetics (ACMG) classification. It was considered the cause of the disease (Table 2).

Tuberous sclerosis occurs in two-thirds of affected individuals due to a de novo pathogenic variant in the TSC1 and TSC2 genes. On the other hand, affected individuals have a 50% chance of passing this disease to their children. If a pathogenic variant is identified in an affected family member, prenatal diagnosis is available for high-risk pregnancies, and families can be offered pre-implantation genetic diagnosis opportunities.

In this article, we aimed to remind that patients followed up with the diagnosis of resistant epilepsy should be examined repeatedly. We

highlighted the importance of café-au-lait spots, axillary and inguinal freckles, neurofibromas, Lisch nodules, hypopigmented macules, confetti-style skin lesions, facial angiofibromas, fibrous plaques, ungual fibromas, shagreen spots, and port-wine nevi that can be seen on skin examination while making the diagnosis.

Conflict of Interest: The authors have declared that they have no conflict of interest.

Funding: The authors have declared that they have not received any financial support.

REFERENCES

1. Ertaşoğlu Toydemir H, Özkara Ç. Dirençli Epilepsilere Yaklaşım. Türkiye Klinikleri J Neurol-Special Topics. 2012; 5: 102.
2. Jimbow K, Tuberous sclerosis and guttate leukoderma. *Semin Cutan Med Surg.* 1997; 16: 30-5. [https://doi.org/10.1016/S1085-5629\(97\)80033-8](https://doi.org/10.1016/S1085-5629(97)80033-8)
3. Kwiatkowski DJ. Rhebbing up mTOR: new insights on TSC1 and TSC2, and the pathogenesis of tuberous sclerosis. *Cancer Biol Ther.* 2003; 2: 471. <https://doi.org/10.4161/cbt.2.5.446>
4. Tsang SH, Sharma T. Tuberous Sclerosis. *Adv Exp Med Biol.* 2018; 1085: 205-7. https://doi.org/10.1007/978-3-319-95046-4_43
5. Akdağ G, Algin D, Erdiñç OO. Epilepsi. *Osmangazi Tıp Dergisi.* 2016; 38: 35-41. [Turkish] <https://doi.org/10.20515/otd.88853>
6. Çalışaneller T, Özdemir Ö, Caner H, Altınörs N. Bir Tüberoskleroz Hastasında Serebellar Kalsifikasyon: Olgu Sunumu. *Türk Nöroşirürji Dergisi.* 2008; 18: 134-7. [Turkish]
7. Portocarrero LKL, Quental KN, Samorano LP, Oliveira ZNP, Rivitti-Machado MCDM. Tuberous sclerosis complex: review based on new diagnostic criteria. *An Bras Dermatol.* 2018; 93: 323-31. <https://doi.org/10.1590/abd1806-4841.20186972>
8. Henske EP, Jóźwiak S, Kingswood JC, Sampson JR, Thiele EA. Tuberous sclerosis complex. *Nat Rev Dis Primers.* 2016; 2: 16035. <https://doi.org/10.1038/nrdp.2016.35>
9. Christophe C, Sekhara T, Rypens F, Ziereisen F, Christiaens F, Dan B. MRI Spectrum of Cortical Malformations in Tuberous Sclerosis Complex. *Brain Dev.* 2000; 22: 487-93. [https://doi.org/10.1016/S0387-7604\(00\)00186-8](https://doi.org/10.1016/S0387-7604(00)00186-8)
10. Yakar F, Erođlu U, Özgüral O, Dođan İ, Uđur H, Çađlar Ş. Dirençli Epilepsi Nöbetleri ile Seyreden Tüberoz Skleroz Olgusu: Olgu Sunumu ve Literatür Derlemesi. *Türk Nöroşir Derg.* 2016; 26: 153-7.

11. Erol I, Savas T, Sekerci S, et al. Tuberous Sclerosis Complex; Single Center Experience. *Turk Pediatri Ars.* 2015; 50: 51-60. <https://doi.org/10.5152/tpa.2015.2138>
12. Dogan V, Yesil S, Kayali S, et al. Regression of Symptomatic Multiple Cardiac Rhabdomyomas Associated with Tuberous Sclerosis Complex in a Newborn Receiving Everolimus. *J Trop Pediatri.* 2015; 61: 74-7. <https://doi.org/10.1093/tropej/fmu056>
13. Castro-Monsalve J, Alvarado-Socarras JL, Mantilla KA, Forero L, Moreno A, Prada CE. Cardiac Rhabdomyomas in Tuberous Sclerosis Complex. *J Pediatr.* 2018; 192: 264. <https://doi.org/10.1016/j.jpeds.2017.09.050>
14. Bernstein J. Renal Cystic Disease in the Tuberous Sclerosis Complex. *Pediatr Nephrol* 1993; 7: 490-5. <https://doi.org/10.1007/BF00857581>
15. Yan Z, Grenert JP, Joseph NM, Ren C, Chen X, Shafizadeh N, Kakar S. Hepatic Angiomyolipoma: Mutation Analysis and Immunohistochemical Pitfalls in Diagnosis, Histopathology. 2018; 73: 101-8. <https://doi.org/10.1111/his.13509>
16. Józwiak S, Sadowski K, Borkowska J, Domanska-Pakieła D, Chmielewski D, Jurkiewicz E, Jaworski M, Urbanska M, Ogrodnik M, Słowinska M, Kotulska K. Liver Angiomyolipomas in Tuberous Sclerosis Complex-Their Incidence and Course, *Pediatr Neurol.* 2018; 78: 20-6. <https://doi.org/10.1016/j.pediatrneurol.2017.09.012>
17. Zimmer-Galler IE, Robertson DM. Tüberosklerozda Retina Lezyonlarının Uzun Süreli Gözlemi. *Ben J Ophthalmol.* 1995; 119: 318-24. [https://doi.org/10.1016/S0002-9394\(14\)71174-2](https://doi.org/10.1016/S0002-9394(14)71174-2)
18. Mishra C, Kannan NB, Ramasamy K, Balasubramanian DA. Retinal Astrocytic Hamartoma in Tuberous Sclerosis. *Indian Dermatol Online J.* 2019; 10: 753-4. https://doi.org/10.4103/idoj.IDOJ_23_19
19. https://tr.qwe.wiki/wiki/Tuberous_sclerosis