

## Cases of allergic coronary syndrome (Kounis syndrome) : what we should know

Türkay Akbaş<sup>1</sup>, Adnan Kaya<sup>2</sup>, Gülşah Altun<sup>3</sup>, Ümit Eşbah<sup>4</sup>  
and Attila Önmez<sup>3</sup>

<sup>1</sup>*Division of Intensive Care, Department of Internal Medicine, Faculty of Medicine, Düzce University, Düzce, Türkiye*

<sup>2</sup>*Department of Cardiology, Faculty of Medicine, Düzce University, Düzce, Türkiye*

<sup>3</sup>*Department of Internal Medicine, Faculty of Medicine, Düzce University, Düzce, Türkiye*

<sup>4</sup>*Department of Anesthesia and Reanimation, Faculty of Medicine, Düzce University, Düzce, Türkiye*

### ABSTRACT

Kounis syndrome (KS) is an acute coronary syndrome that occurs with allergic, hypersensitivity, anaphylactic, or anaphylactoid reactions associated with mast cell activation, and entails significant morbidity and mortality risks. We present four cases of acute coronary syndrome developing after insect bites, chemotherapy, and coronary stent implantation. Two patients were lost due to anaphylactic shock-related multiorgan failures and sudden cardiac death. Since a wide range of drugs, foods, environmental conditions, and disease states may be associated with KS, all physicians must be aware of the syndrome.

Keywords: allergic reaction, chest pain, coronary vasospasm, mast cell activation

Abbreviations:

CAG: coronary angiography

ECG: electrocardiography

EF: ejection fraction

ICU: intensive care unit

KS: Kounis syndrome

TTE: transthoracic echocardiography

This is an Open Access article distributed under the Creative Commons Attribution-NonCommercial-NoDerivatives 4.0 International License. To view the details of this license, please visit (<http://creativecommons.org/licenses/by-nc-nd/4.0/>).

### INTRODUCTION

Kounis syndrome (KS) is the presentation of acute coronary syndromes, such as coronary spasm, acute myocardial infarction, and stent thrombosis associated with mast cell activation deriving from allergic, hypersensitivity, anaphylactic, or anaphylactoid reactions. Inflammatory cytokines released through mast cell activation lead to coronary artery vasospasm and/or athero-

---

Received: August 5, 2021; accepted: November 17, 2021

Corresponding Author: Türkay Akbaş, MD

Division of Intensive Care, Department of Internal Medicine, Faculty of Medicine, Düzce University,

Konuralp Yerleşkesi, Beciyorukler Mevkii, Düzce 81620, Türkiye

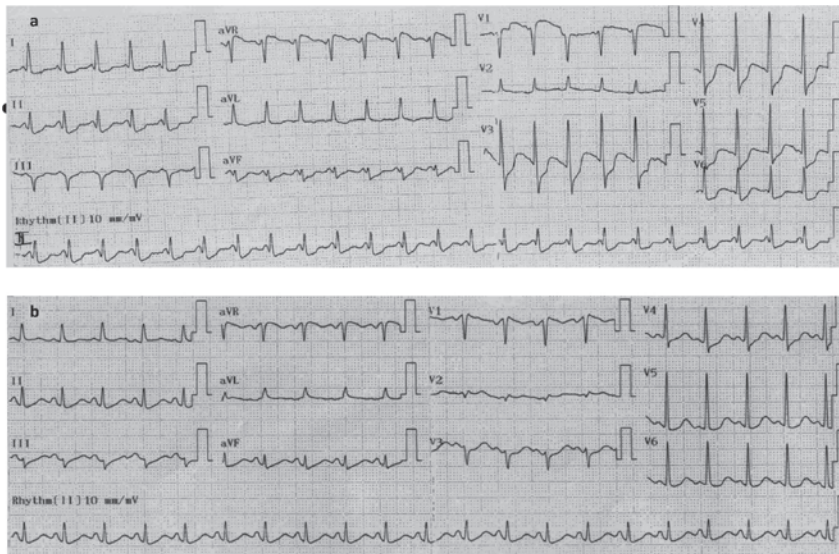Tel: +90-532-238-3197, Fax: +90-380-542-1302, E-mail: [turkayakbas@duzce.edu.tr](mailto:turkayakbas@duzce.edu.tr)

matous plaque erosion/rupture concluding in acute coronary syndrome.<sup>1,2</sup> Numerous conditions, including environmental factors, foods, clinical states, and drugs can trigger KS.<sup>1,3-5</sup> Chest pain, ST/T segment changes at electrocardiography (ECG), arrhythmias, and elevated cardiac enzymes are the principal manifestations.<sup>1,2</sup> Patients become hemodynamically unstable in severe, potentially fatal, cases. Three types of KS have been defined to date.<sup>1</sup> Type I involves coronary vasospasm in the setting of normal or nearly normal coronary arteries, while type II is encountered in patients with underlying inactive coronary artery diseases in whom allergic insults lead to coronary artery vasospasm with normal cardiac enzymes, or plug erosion/rupture leading to acute myocardial infarctions. Type III involves stent thrombosis due to hypersensitivity reaction. We report four cases of KS including all three types, and in which all patients were followed-up in a medical intensive care unit (ICU).

## CASE REPORT

### *Case 1*

A 44-year-old woman with a history of epilepsy was originally admitted to a public hospital emergency department following a wasp sting, and was discharged home after medical therapy. The patient was readmitted to the hospital 12 hours subsequently with symptoms of dyspnea and chest pain. Her blood pressure on arrival was 85/44 mm Hg, respiratory rate 24/min, temperature 37.8°C, and heart rate 113/min. ECG revealed ST elevation in the V1 and aVR, QS in the D III, and ST depression in the V3-6, aVF, DI and DII leads (Fig. 1a), with a troponin I level of 9.99 ng/mL. Due to the presence of deep metabolic acidosis with hemodynamic instability (pH, 6.918; HCO<sub>3</sub>, 10 mEq/L; lactate, 11.46 mmol/L), the patient was intubated and transferred to the cardiology department for coronary angiography (CAG) with the support of noradrenalin and dopamine infusion. The patient experienced a ventricular fibrillation attack during CAG and was defibrillated. CAG was normal except for circumflex exit anomaly and global hypokinesis with an ejection fraction (EF) of 50%. The patient was admitted to the ICU with hypotension and high-dose noradrenalin infusion (1.5 µg/kg/min) requirement. Control troponin I and creatine kinase-MB on arrival at the ICU were 14.23 ng/mL (normal range, 0–0.16 ng/mL) and 104 IU/L (normal range, 0–24 IU/L), respectively. The vasopressor was stopped after 8 hours, and the patient was extubated 18 hours after ICU admission. ECG revealed minimal ST depression in the V4 and inferior leads (Fig. 1b), and her troponin I level decreased to 2.32 ng/mL on the second day. Her EF increased to 60% with good global cardiac functions on day 3. The patient was discharged home on day 5. Pheniramine, ranitidine, and ivabradine (for sinus tachycardia) therapy was administered in the ICU.



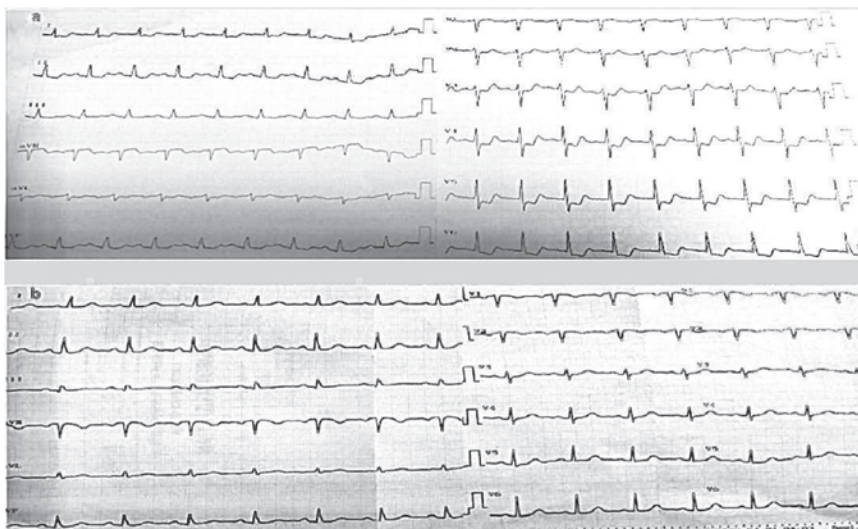
**Fig. 1** ECG in Case 1

**Fig. 1a:** Initial electrocardiogram showing ST elevation in the V1 and aVR, QS in the DIII, and marked ST depression in the V3-6, aVF, DI and DII leads with a sinus rhythm of 150/minute.

**Fig. 1b:** Repeated ECG showing resolution of ST elevations and QS changes and minimal ST depression in the V3-4 and inferior leads with a sinus rhythm of 125/minute. The patient benefited from ivabradine therapy for sinus tachycardia.

### Case 2

A 44-year-old woman with a history of peripheral neuropathy was admitted to the emergency department with symptoms of fatigue, myalgia, abdominal pain, rash, and periorbital edema after a brown spider bite. Her vital signs were normal, while her admission creatine kinase-MB and troponin I levels were mildly elevated, but ECG was normal. She was hospitalized to the ward for observation. The patient experienced chest pain 10 hours after hospital admission. Control ECG showed ST depression in the V2-6 and lateral leads (Fig. 2a). Serial troponin I measurement revealed marked elevation from 0.32 ng/mL to 6.76 ng/mL. Transthoracic echocardiography (TTE) revealed anteroseptal and midbasal hypokinesia with an EF of 50%. CAG was normal except for 20% stenosis due to a plaque in the proximal parts of the left anterior descending artery and the right coronary artery. The patient was followed-up in the ICU due to the ongoing chest pain, and nitroglycerin infusion was initiated. The chest pain resolved within 24 hours with normalization of ECG (Fig. 2b), and the myalgia and abdominal pain resolved after 48 hours. The patient was discharged home on day 4. Pheniramine, ranitidine, methylprednisolone, and nitroglycerin therapy was administered in the ICU.



**Fig. 2** ECG in Case 2

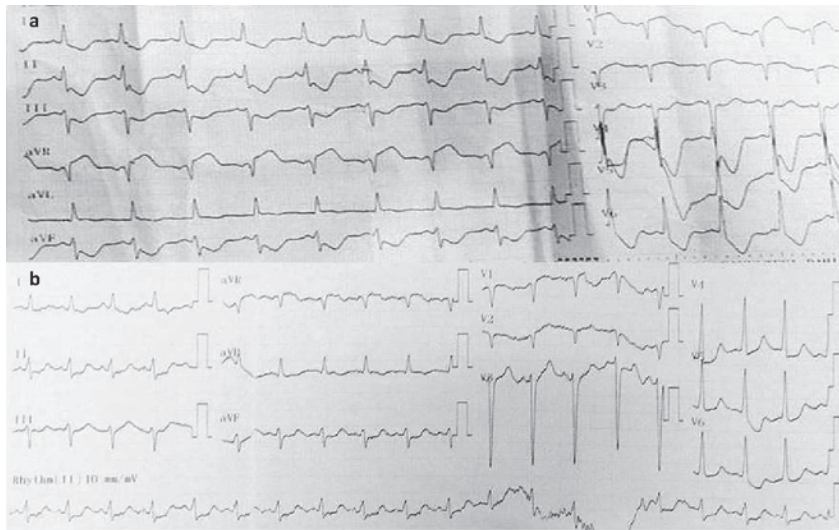
**Fig. 2a:** Initial ECG showing ST depression in the V2-6 and lateral leads with the sinus rhythm.

**Fig. 2b:** Control ECG showing the resolution of ST changes.

### Case 3

A 66-year-old man with RAS wild-type metastatic colon cancer was receiving maintenance therapy consisting of FOLFOX (oxaliplatin leukovorin, 5-fluorouracil) plus panitumumab and achieving partial regression under this regimen. Headache, nausea, and vomiting occurred just 10 minutes after the beginning of oxaliplatin infusion (his 40th dose of oxaliplatin) during 20/2 FOLFOX plus panitumumab chemotherapy. The chemotherapy was stopped. The patient's body temperature was 38.5°C, and diphenhydramine, dexamethasone, and ondansetron therapy was promptly administered. The patient then became hypotensive. ECG showed ST elevation in the V1-2 and aVR, and ST depression in the V3-6, DI and inferior leads (Fig. 3a). Acetylsalicylic acid, heparin and ticagrelor were ordered on the ward. Serial troponin I measurements revealed marked elevation from 1.85 to 9.39 ng/ml, with normal renal and liver function tests. CAG was performed following hemodynamic stabilization with fluid and noradrenalin. This revealed the non-critical left anterior descending artery and right coronary artery stenosis (20–30%) and a moderate mid left circumflex artery stenosis (50–70%). Functional assessment with functional flow reserve was planned, since the lesion was thought to be a stable plaque. TTE showed moderate mitral and tricuspid regurgitation and increased pulmonary artery pressures (65 mm Hg) with an EF of 60%. A computed tomography scan of chest with contrast medium ruled out pulmonary embolism, aortic dissection, and pneumonia. Control arterial blood gas study revealed deep metabolic acidosis (pH, 7.199; PCO<sub>2</sub>, 29 mm Hg; HCO<sub>3</sub>, 9 mEq/L; lactate, 13.5 mmol/L), and tachypnea developed during the ward follow-up. The patient was intubated and then admitted to the ICU. On arrival at the ICU, he was anuric, on noradrenalin infusion (1.2 µg/kg/min), and with a Glasgow coma score of 6. Control ECG revealed QS in the V1-2 and minimal ST depression in the V4-6, DII and AVF leads (Fig. 3b). Control troponin I, creatine kinase-MB, international normalized ratio, creatinine, aspartate aminotransferase, alanine transaminase and lactate levels on the day of admission to the ICU were >25 ng/mL, 177 IU/L, 3.03, 2.72 mg/dL, 4228 IU/L, 9250 IU/L, and 16.5 mmol/L, respectively. The patient died three days later due to

multiorgan failures. All cultures taken in the ward and ICU were negative. The patient received piperacillin-tazobactam (empirically started), methylprednisolone, diphenhydramine, ranitidine, acetylsalicylic acid, enoxaparin, and ticagrelor therapy in the ICU.



**Fig. 3** ECG in Case 3

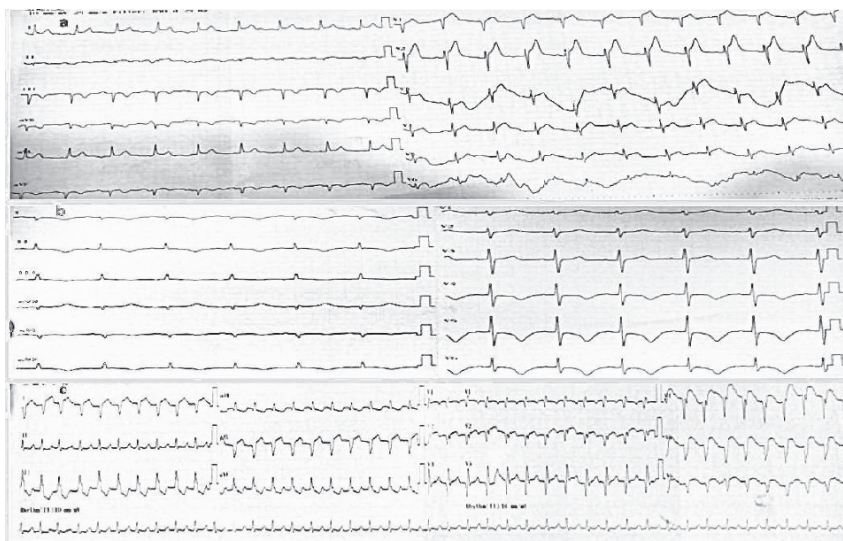
**Fig. 3a:** Initial ECG showing ST elevation in the V1-2 and aVR, ST depression in the V3-6, DI-III and aVF, and T inversion in the aVL leads.

**Fig. 3b:** Control ECG showing QS in the V1-2 and minimal ST depression in V4-6, DII and AVF leads.

#### Case 4

A 46-year-old man with a 75-pack-year smoking history was brought to the emergency department after 15 minutes of cardiopulmonary resuscitation and three defibrillations in his workplace. The patient was taken to the angiography laboratory with a diagnosis of hyperacute anterior myocardial infarction (Fig. 4a). A 3.5 × 15 mm bare metal stent was implanted to the proximal part of the totally occluded left anterior descending artery after appropriate predilatation. TTE showed anteroseptal hypokinesis with an EF of 50%. The patient was then transferred to the ICU with a Glasgow coma score of 5. ECG demonstrated T wave inversion in the DI, DII, AVF and V4-6 leads with first-degree AV block on admission to the ICU (Fig. 4b). The patient was stable during the follow-up period, with no organ dysfunction, except for hypoxic encephalopathy, and received antibiotherapy for aspiration pneumonia. He became hypotensive on the 5th day in the ICU, and ST segment elevation was noticed on the ECG monitor at the same time. Control ECG showed ST segment elevation with Q wave in the V1-6 and lateral leads and incomplete right bundle branch block (Fig. 4c). Troponin I was elevated at >75 ng/mL, and TTE showed a severely hypokinetic anterior wall, apical akinesis, and apex aneurysm with an EF of 25%. The new CAG indicated stent thrombosis. The lesion was crossed and multiple dilatations were performed with a 3.5 × 12 mm non-compliant balloon. Good distal blood flow was restored with thrombolysis in myocardial infarction 3 (TIMI-3). Asystole occurred 3 hours after the second intervention and did not respond to cardiopulmonary resuscitation. The patient received acetylsalicylic acid, clopidogrel, enoxaparin, atorvastatin, metoprolol, and ampicillin-

sulbactam therapy in the ICU.



**Fig. 4** ECG in Case 4

- Fig. 4a:** Initial ECG showing hyperacute T wave tapering in the V1-2, and minimal ST segment elevation in the DI and aVL leads with T inversion in the DIII and aVF leads.
- Fig. 4b:** ECG on admission to the ICU showing T wave inversion in the DI, DII, AVF and V4-6 leads with first-degree AV block.
- Fig. 4c:** Control ECG showing ST segment elevation with Q wave in the V1-6 and lateral leads, and incomplete right bundle branch block with sinus tachycardia.

## DISCUSSION

KS is an allergic disease of the coronary arteries provoked by allergic, hypersensitivity, anaphylactic, or anaphylactoid reactions through mast cell activation. It should be regarded as a systemic disease since the skin, and respiratory and vascular systems are concomitantly involved in nearly all cases. Cerebral and mesenteric arteries other than coronary arteries are also affected.<sup>1</sup> Numerous factors including drugs, foods, environmental exposures, and health conditions can result in KS.<sup>1,4,5</sup> Although any drug can cause the syndrome, the most culpable agents are antibiotics, analgesics, anesthetics, antineoplastics, herbal medicines, and contrast media.<sup>1,3-5</sup> Even acetylsalicylic acid and glucocorticoids, the principal drugs used in the treatment of acute coronary syndromes and allergic reactions, can cause KS.<sup>3,6</sup> Insect bites or stings, or contact with animal saliva, grass cuttings, latex, or metal are commonly seen environmental factors for KS.<sup>1</sup> Several types of foods, including milk, eggs, fish, canned food, fruits, vegetables, and mushrooms have been implicated in KS.<sup>1,4</sup> Additionally, various health states also predispose patients to KS development, such as vascular stenting (bare metal or drug eluting), asthma, angioedema, mastocytosis and serum sickness. The reported incidence of KS among patients with allergy, hypersensitivity, anaphylaxis, or anaphylactic reactions is between 2% and 3.4%.<sup>5,7</sup> Since KS is largely described in the form of case reports, mortality rates differ widely, from 0% to 50%.<sup>4,5,7</sup> One retrospective study including the data of 235,420 patients hospitalized for allergy,

hypersensitivity, anaphylaxis, or anaphylactic reactions between 2007 and 2014 calculated a mortality rate of 7%.<sup>8</sup> There are no specific diagnostic criteria for KS. It can present in a variety of clinical and laboratory states, such as chest pain, any arrhythmia, ST/T changes, elevated cardiac markers, coronary vasospasm, acute myocardial infarction, stent thrombosis, acute cardiac failure, and even sudden death. Postmortem studies have implicated mast cell degranulation in up to 13% of sudden deaths.<sup>9</sup> Physicians should be alert to the possibility of KS when treating patients with any allergic reaction or with new onset or aggregated cardiac symptoms. ECG and cardiac enzymes should be checked for the exclusion of KS in allergic patients.

Three types of KS have been described.<sup>1,2</sup> The type 1 variant is encountered in patients with normal or nearly normal coronary arteries, and coronary artery spasm is responsible for the clinical situation. Such patients may exhibit normal cardiac biomarkers or acute myocardial infarction with elevated cardiac biomarkers. The type 2 KS variant includes patients with pre-existing atheromatous diseases in whom acute inflammatory mediators induce either coronary artery spasm with normal cardiac biomarkers, or else cause plaque erosion/rupture together with coronary artery spasm resulting in myocardial infarction. The type 3 variant can develop in both drug-eluted and bare stents, since all stent components can act as allergens.<sup>10</sup> The pathophysiology of KS depends on the activation of mast cells present in any tissue in the body, including in the intimal layer of the coronary arteries and atherosclerotic plaques. After exposure to an allergic insult, mast cell degranulation leads to local and systemic release of several mediators including histamine, tryptase, chymase, cathepsin-D, platelet activating factor, thromboxane, leukotrienes, and cytokines involved in the development of KS.<sup>1,2</sup> Histamine, thromboxane, and leukotrienes are responsible for vasoconstriction. Neutral proteinases released by mast cells, such as tryptase, chymase, and cathepsin-D, activate matrix metalloproteinases which organize matrix degradation within plaques, and therefore, promote plaque disruption and rupture.<sup>2,11</sup> Activation of platelets and expression of vascular tissue factors by histamine and thromboxane lead to thrombosis formation.<sup>2</sup> Platelet activating factor prompts the activation of thrombotic cascades, directly alters the heart rate, and can result in coronary artery vasoconstriction.<sup>12</sup> All these reactions can lead to the appearance of KS. The study of mast cell degranulation in terms of the diagnosis of KS has no clinical utility due to the shorter half-lives of the major mediators. The half-lives of platelet activating factor, histamine and tryptase are <5 minutes, <15 minutes and approximately 2 hours, respectively.<sup>13</sup>

The treatment of KS is challenging since both cardiac and allergic symptoms must be dealt with together. Intravenous H<sub>1</sub> and H<sub>2</sub> antihistamines and corticosteroids are used for the treatment of allergic reactions. Nitrate and calcium canal blockers are vasodilators that should be used for the treatment of allergic vascular spasm.<sup>1,2</sup> Beta-blockers can exacerbate coronary spasm due to causing unopposed alpha-adrenergic receptors. Adrenalin can also aggravate coronary spasm and worsen the clinical situation. Glucagon should be preferred over adrenalin for the treatment of anaphylactic reaction when patients present with KS.<sup>14</sup> Morphine, codeine and meperidine should not be used, since these can also induce mast cell degranulation. Fentanyl and its derivatives should be employed for analgesia. CAG is of crucial importance for the application acute coronary event protocols and intrastent thrombus removal in patients with type II and III KS.<sup>1</sup>

The first two cases described in this report were examples of the type 1 variant in which KS was caused by insect bites. The third case was a severe example of KS developing due to the oxaliplatin chemotherapy. That patient experienced severe anaphylactic shock together with coronary artery vasospasm and died from multiorgan failures. Oncological drugs are well-known causes of KS, with platinum agents being generally reported.<sup>15</sup> The fourth case was an example of early stent thrombosis occurring in the ICU. This stent thrombosis may have been associated with either allergic reactions to the stent components, or with the drugs ordered in the ICU, namely acetylsalicylic acid, clopidogrel, and ampicillin-sulbactam. All these drugs have previously

been reported to cause KS.<sup>1,3</sup>

Since any allergen can trigger KS, physicians should always maintain a high index of suspicion for KS when treating patients with allergic, hypersensitive, anaphylaxis, or anaphylactoid reactions. KS can present from chest pain with no myocardial injury to acute myocardial infarction, and even sudden death. KS should also be excluded in critically ill patients when they exhibit signs of coronary artery diseases or hemodynamic instability with or without allergic manifestations. Critically ill patients are prone to KS due to polypharmacy used in the ICU and to the greater numbers of elderly patients with generally high rates of cardiovascular comorbidities being admitted to the ICU. Another important point requiring consideration is that KS can lead the interventional cardiologist to misdiagnose stable moderate coronary atherosclerotic plaques (50–70%) and vasospasm as the causative factor and thus to proceed with percutaneous coronary intervention, which is not appropriate in this situation and may be deleterious to the patient.

#### ACKNOWLEDGEMENT

Part of this study was presented at the 15th Congress of The Turkish Society of Medical and Surgical Intensive Care Medicine - 7th Euro-Asian Critical Care Meeting, November 21–24, Antalya, Türkiye, 2018.

#### AUTHOR CONTRIBUTIONS

T Akbaş designed the study, followed the patients, collected the raw study data, performed the literature searches, contributed to the writing of the paper, and was the principal author study. A Kaya followed the patients, gathered the cardiologic data of the study, performed the literature searches, contributed to the writing of the paper. G Altun, Ü Eşbah and A Önmez followed the patients, gathered the raw study data, performed the literature searches, and contributed to the writing of the paper. All authors read, edited and ultimately approved the final manuscript.

#### FUNDING

This research received no specific grant from any funding agency in the public, commercial, or not-for-profit sectors.

#### ETHICAL REVIEW

Written informed consent for patient information and images to be published was provided by the patients or legally authorized representatives.

#### DECLARATION OF CONFLICTING INTEREST

The authors declare no conflict of interest.

## REFERENCES

- 1 Kounis NG, Koniari I, Velissaris D, Tzani G, Hahalis G. Kounis Syndrome-not a single organ arterial disorders but a multisystem and multidisciplinary disease. *Balkan Med J.* 2019;36(4):212–221. doi:10.4274/balkanmedj.galenos.2019.2019.5.62.
- 2 Kounis NG. Coronary hypersensitivity disorder: the Kounis syndrome. *Clin Ther.* 2013;35(5):563–571. doi:10.1016/j.clinthera.2013.02.022.
- 3 Renda F, Landoni G, Trotta F, et al. Kounis syndrome: An analysis of spontaneous reports from international pharmacovigilance database. *Int J Cardiol.* 2016;203:217–220. doi:10.1016/j.ijcard.2015.10.003.
- 4 Li J, Zheng J, Zhou Y, Liu X, Peng W. Acute coronary syndrome secondary to allergic coronary vasospasm (Kounis Syndrome): a case series, follow-up and literature review. *BMC Cardiovasc Disord.* 2018;18(1):42. doi:10.1186/s12872-018-0781-9.
- 5 Aköz A, Tanboğa Hİ, Emet M, et al. A prospective study of Kounis syndrome: Clinical experience and cardiac magnetic resonance imaging findings for 21 patients. *Acta Med Mediterr.* 2013;29(4):811–816.
- 6 Kounis NG, Koniari I, Soufras GD, Chourdakis E. Anaphylactic shock with methylprednisolone, Kounis syndrome and hypersensitivity to corticosteroids: a clinical paradox. *Ital J Pediatr.* 2018;44(1):143. doi:10.1186/s13052-018-0579-5.
- 7 Yanagawa Y, Kondo A, Ishikawa K, et al. Kounis syndrome should be excluded when physicians treat patients with anaphylaxis. *Ann Allergy Asthma Immunol.* 2017;119(4):392. doi:10.1016/j.anai.2017.08.003.
- 8 Desai R, Parekh T, Patel U, et al. Epidemiology of acute coronary syndrome co-existent with allergy/hypersensitivity/anaphylactic reactions (Kounis syndrome) in the United States: a nationwide inpatients analysis. *Int J Cardiol.* 2019;292:35–38. doi:10.1016/j.ijcard.2019.06.002.
- 9 Schwartz HJ, Yunginger JW, Schwartz LB. Is unrecognized anaphylaxis a cause of sudden unexpected death? *Clin Exp Allergy.* 1995;25(9):866–870. doi:10.1111/j.1365-2222.1995.tb00029.x.
- 10 Kounis NG, Koniari I, Roumeliotis A, et al. Thrombotic responses to coronary stents, bioresorbable scaffolds and the Kounis hypersensitivity-associated acute thrombotic syndrome. *J Thorac Dis.* 2017;9(4):1155–1164. doi:10.21037/jtd.2018.10.102.
- 11 Johnson JL, Jackson CL, Angelini GD, George SJ. Activation of matrix-degrading metalloproteinases by mast cell proteases in atherosclerotic plaques. *Arterioscler Thromb Vasc Biol.* 1998;18(11):1707–1715. doi:10.1161/01.atv.18.11.1707.
- 12 Montrucchio G, Alloati G, Camussi G. Role of platelet-activating factor in cardiovascular pathophysiology. *Physiol Rev.* 2000;80(4):1669–1699. doi:10.1152/physrev.2000.80.4.1669.
- 13 Beck SC, Wilding T, Buka RJ, Baretto RL, Huissoon AP, Krishna MT. Biomarkers in human anaphylaxis: a critical appraisal of current evidence and perspectives. *Front Immunol.* 2019;10:494. doi:10.3389/fimmu.2019.00494.
- 14 Tanno LK, Alvarez-Perea A, Poussel G. Therapeutic approach of anaphylaxis. *Curr Opin Allergy Clin Immunol.* 2019;19(4):393–401. doi:10.1097/ACI.0000000000000539.
- 15 Kounis NG, Koniari I, Hahalis G. Cardio-oncology, immune-oncology, onco-cardiology and onco-immunology. *Int J Cardiol.* 2016;223:254–257. doi:10.1016/j.ijcard.2016.08.219.