



ORIGINAL ARTICLE / *Oncology*

Effectiveness of percutaneous vertebroplasty in cases of vertebral metastases

O.F. Nas^{a,*}, M.F. Inecikli^b, E. Kacar^c, R. Buyukkaya^d,
G. Ozkaya^e, O. Aydın^f, C. Erdogan^a, B. Hakyemez^a

^a Department of Radiology, Faculty of Medicine, Uludag University, Bursa, Turkey

^b Department of Radiology, Faculty of Medicine, Recep Tayyip Erdogan University, Rize, Turkey

^c Department of Radiology, Faculty of Medicine, Afyon Kocatepe University, Afyonkarahisar, Turkey

^d Department of Radiology, Faculty of Medicine, Duzce University, Duzce, Turkey

^e Department of Biostatistics, Faculty of Medicine, Uludag University, Bursa, Turkey

^f Radiology Clinic, Ali Osman Sonmez Oncology Hospital, Bursa, Turkey

KEYWORDS

Percutaneous vertebroplasty (PV);
Vertebral metastases;
Visual analogue scale (VAS);
Polymethylmethacrylate (PMMA)

Abstract

Purpose and objectives: To assess the effectiveness of percutaneous vertebroplasty (PV) in patients with vertebral collapse due to metastases.

Materials and methods: PV procedures performed on 95 vertebrae in 52 patients with primary malignancy were retrospectively evaluated. Vertebral metastases, primary malignancies of the patients, pain before and after PV on a visual analogue scale (VAS), amount of polymethylmethacrylate (PMMA) cement applied to the vertebral body during PV, PMMA cement leakage and vertebral approaches were evaluated.

Results: VAS scores of 43 patients (in total 79 vertebrae) were evaluated. Median VAS scores of patients declined from 8 (4–10) before PV to 3 (0–7) within one day after the procedure, to 2 (0–9) one week after the procedure and eventually to 2 (0–9) 3 months after the procedure ($p < 0.001$). PMMA amount applied to the vertebral body during PV varied between 1.5–9 mL (average \pm SD 4.91 \pm 1.61). There was no significant statistical correlation between PMMA amounts and VAS scores within one day after, 1 week after and 3 months after the PV procedure ($p > 0.05$).

* Corresponding author.

E-mail addresses: omerfatihnas@gmail.com (O.F. Nas), drinecikli@gmail.com (M.F. Inecikli), dremrekacar@yahoo.com (E. Kacar), rbuyukkaya@gmail.com (R. Buyukkaya), ozkaya@uludag.edu.tr (G. Ozkaya), oaydindr@yahoo.com (O. Aydın), cerdogan@uludag.edu.tr (C. Erdogan), bhakyemez@uludag.edu.tr (B. Hakyemez).

<http://dx.doi.org/10.1016/j.diii.2015.05.001>

2211-5684/© 2015 Published by Elsevier Masson SAS on behalf of the Éditions françaises de radiologie.

Please cite this article in press as: Nas OF, et al. Effectiveness of percutaneous vertebroplasty in cases of vertebral metastases. Diagnostic and Interventional Imaging (2015), <http://dx.doi.org/10.1016/j.diii.2015.05.001>

Conclusion: PV is a simple, effective, reliable, easy to perform and minimally invasive procedure in patients with painful vertebral metastases.

© 2015 Published by Elsevier Masson SAS on behalf of the Éditions françaises de radiologie.

Metastatic disease of a primary malignancy is most commonly seen in the skeletal system after lungs and liver, and vertebrae are the most commonly involved bones [1,2]. Pain is an important symptom in patients with spinal metastasis. Progression of spinal metastasis can result in compression of the spinal column caused by fracture of vertebral bodies [3].

Percutaneous vertebroplasty (PV) is a minimally invasive procedure with polymethylmethacrylate (PMMA) bone cement injection into the vertebral body [4]. It is one of the modalities accepted for treating vertebral fractures caused by osteoporosis, malignancies and trauma [5]. PV was first described in 1987 by Galibert et al. in treatment of a painful vertebral hemangioma [6]. Two main indications of PV in spinal metastasis treatment are analgesia and vertebral column stabilization [7]. The superiority of PV in malignant spinal involvement is that it is less invasive than open surgery and faster in relieving pain than radiotherapy and other conventional treatment methods [5]. PV effects occur quickly and it is a supplementary procedure to radiotherapy or chemotherapy in patients with malignant spinal involvement [8]. Balloon kyphoplasty (BK), radiofrequency (RF) kyphoplasty and plasma-mediated radiofrequency ablation (coblation) can be used to treat vertebral fractures in addition to PV. Bone metastases can also be treated with percutaneous ablation [9].

From our study, outcomes of PV procedures performed in our department on patients with vertebral metastasis and known primary malignancies over a six-year period are presented. The purpose of our study was to assess the effectiveness of PV in patients with vertebral collapse due to metastases.

Materials and methods

Protocol

PV procedures performed on 95 vertebrae in 52 patients with primary malignancy between April 2008 and April 2014 were retrospectively evaluated. The only indication of vertebroplasty was severe back pain, and this pain generally limited body movements of patients and was unresponsive to different painkillers. Most of our patients were using level 3 (moderate to severe pain) painkillers. Magnetic resonance (MR) imaging was performed on all patients before the procedure, in order to assess the localization of vertebral metastasis and the extent of tumoral infiltration into the spinal canal and paravertebral tissue. Conventional sagittal

T1-weighted, T2-weighted and STIR images were acquired on a 3 T (Achieva TX, Philips, Best, Netherlands) or a 1.5 T scanner (Magnetom Vision plus, Siemens, Erlangen, Germany) using a spine coil. Sagittal post-contrast T1-weighted images were acquired after administration of 0.1 mmol/kg MR contrast media when necessary. The MR sequence parameters used are indicated in Table 1. Metastatic involvement of the vertebrae was detected clinically and radiologically in patients with known primary malignancies. Twelve of 52 patients were treated with chemotherapy, 2 with radiotherapy and 38 with both therapies before or after the procedure. Biopsies were performed on vertebrae with suspicious metastatic findings. The extent of metastatic involvement in vertebral bodies was assessed using the semi-quantitative visual assessment index showing vertebral deformity developed by Genant et al. [10]. In this index, height loss in the anterior, middle and/or posterior columns of a vertebral body is defined as, grade 0: normal, grade 1: 20–25% mild, grade 2: 25–40% moderate, grade 3: > 40% severe. Our study was approved by the ethical committee.

Operative technique

PV was performed with sterile conditions, under sedoanalgesia (midazolam 0.03 mg/kg i.v. and/or fentanyl 1 µ/kg i.v. and/or ketamine 1 mg/kg i.v. or propofol 3–5 mg/kg i.v. and/or pethidine 1 mg/kg i.m.), in a biplane, flat-paneled angiography unit (AXIOM Artis FD Biplane Angiosuite, Siemens Medical Solutions, Erlangen, Germany). Ampicillin 1000 mg-sulbactam 500 mg combination was administered i.v. before the procedure for antibioprophyllaxis. Patients laid down on the angiography table in prone position. During the procedure, 11, 13 or 14 gauge single use only bone biopsy needles were used. Biopsy needles were placed into the vertebral body through the vertebral pedicle with the guidance of anteroposterior and/or lateral fluoroscopic imaging. Left transpedicular, right transpedicular and bipedicular approaches were used to reach the vertebral bodies. Biopsies were performed on vertebrae with suspicious metastatic findings. PMMA (Cemento Fixx, Optimed, San Possidonio, Italy) bone cement was applied to the vertebral body under fluoroscopy in a slow and controlled way manually or using an injection gun. The cement was applied preferentially to the lytic zone of the vertebra. No rupture in the posterior wall of the vertebral body was observed. PV was performed on 2, 3 or even 4 or 5 vertebral levels in the same session. Patients were followed in the observation room for 3 hours after the procedure and consequently discharged within the same day.

Table 1 MR sequence parameters.

Sequences	MR (T)	TR (ms)	TE (ms)	TI (ms)	Matrix	NSA	Slice thickness (mm)	Slice gap (mm)	FOV	Time (s)
Sagittal T2-weighted	3	3500	110	—	200 × 286	2	4	0.4	300 × 160	190
	1.5	4200	90	—	192 × 512	2	3	0.3	340 × 200	150
Sagittal T1-weighted	3	460	8	—	200 × 300	2	4	0.4	300 × 160	110
	1.5	550	15	—	192 × 256	2	3	0.3	340 × 200	180
Sagittal STIR	3	3000	80	210	124 × 169	2	4	0.4	300 × 160	160
	1.5	4000	90	160	192 × 512	3	3	0.3	340 × 200	210

STIR: short tau inversion recovery; MR: magnetic resonance; TR: time to repetition; TE: time to echo; TI: inversion time; NSA: number of signal averages; FOV: field of view; T: Tesla; mm: millimeter; ms: millisecond; s: second.

Pain assessment

Visual analogue scale (VAS) was used to assess patients' pain scores the day before, within one day after, 1 week and 3 months after the procedure. VAS involves the standard pain scale from 0 to 10 (0=no pain, 10=intolerable, the most severe pain ever felt in a patient's life) in order to determine the level of pain objectively. VAS scores of the patients were assessed by talking face to face or by phone calls before, within one day after, 1 week and 3 months after the procedure.

Statistical analysis

All statistical analyses were performed with the SPSS 22.01 statistical package program. Descriptive values of variables are expressed as means ± standard deviation or medians (minimum-maximum). Shapiro-Wilk Test was used to determine the normal distribution of data. Wilcoxon Signed Rank Test was used for group comparisons. Relationships between variables were reviewed using Spearman's Rank Correlation Coefficient. The levels of significance were defined as $\alpha = 0.05$.

Results

In total, 52 patients (24 men [46.2%] and 28 women [53.8%], age range: 21–86 years [mean 63.98 ± 12.97]) were enrolled. The primary tumor locations in descending order of frequency were the breast ($n = 14/52$; [26.9%]), lung ($n = 9/52$; [17.3%]), prostate ($n = 7/52$; [13.5%]), kidney ($n = 5/52$; [9.6%]), stomach ($n = 5/52$; [9.6%]) and others ($n = 12/52$; [23.1%]). Others were malignancies like colon, lymphoma, pancreas and larynx. Biopsy was performed during the procedure on 15 ($n = 15/95$; [15.8%]) vertebrae with certain primary malignancy but suspicious metastases. Metastatic carcinoma was detected in 6 ($n = 6/95$; [6.3%]) and non-specific findings such as blood elements, fibrin and trabecular particles were detected in 9 ($n = 9/95$; [9.5%]) of these vertebrae.

PV was performed on 95 vertebrae (54 lumbar [56.8%] and 41 thoracic [43.2%]). PV was most frequently performed at the L1 level ($n = 17/95$; [17.9%]) for lumbar and at the T12 level ($n = 13/95$; [13.7%]) for thoracic vertebrae. A single vertebra was involved in 25 patients ($n = 25/52$; [48%]) and more than one vertebrae were involved in 27 patients ($n = 27/52$; [52%]) (in 15 patients: 2, in 9 patients: 3, in 2 patients: 4, and in 1 patient: 5). According to the semi-quantitative visual assessment index developed by Genant et al. [8], height losses of vertebrae were grade 0: 7 ($n = 7/95$; [7.4%]), grade 1: 30 ($n = 30/95$; [31.6%]), grade 2: 31 ($n = 31/95$; [32.6%]) and grade 3: 27 ($n = 27/95$; [28.4%]). Left transpedicular ($n = 63/95$; [66.3%]), right transpedicular ($n = 7/95$; [7.4%]) and bipedicular ($n = 25/95$; [26.3%]) approaches were used for PV procedures.

The efficacy of percutaneous vertebroplasty was assessed by considering VAS scores before and after PV, PMMA amount applied to the vertebral body and PMMA leakage.

The PV procedure was performed on 95 vertebrae in 52 patients. Nine patients could not be reached by phone. VAS scores of 79 vertebrae in 43 patients were assessed. Median VAS scores of patients declined from 8 (4–10) before PV to 3 (0–7) within one day after, to 2 (0–9) 1 week after and eventually to 2 (0–9) 3 months after the procedure ($p < 0.001$) (Fig. 1). There was a significant statistical difference between average VAS scores within one day after, and 1 week after the procedure ($p < 0.001$); within one day after and 3 months after the procedure ($p < 0.001$); and 1 week after and 3 months after the procedure ($p = 0.002$).

PMMA amount applied to the vertebral body varied between 1.5 and 9 mL (average ± SD 4.91 ± 1.61). There was no significant statistical correlation between PMMA amounts and VAS scores within one day after, 1 week after and 3 months after the procedure ($p > 0.05$).

No complication was observed in 52 vertebrae ($n = 52/95$; [54.7%]). PMMA leakage was present in a total of 43 vertebrae ($n = 43/95$; [45.3%]) (intradiscal leakage in 20 vertebrae ($n = 20/95$; [21.1%]), leakage into the epidural or paravertebral veins in 20 vertebrae ($n = 20/95$; [21.1%]) and leakage into both disc and the epidural or paravertebral veins in 3 vertebrae ($n = 3/95$; [3.1%]). No neurological deficits or

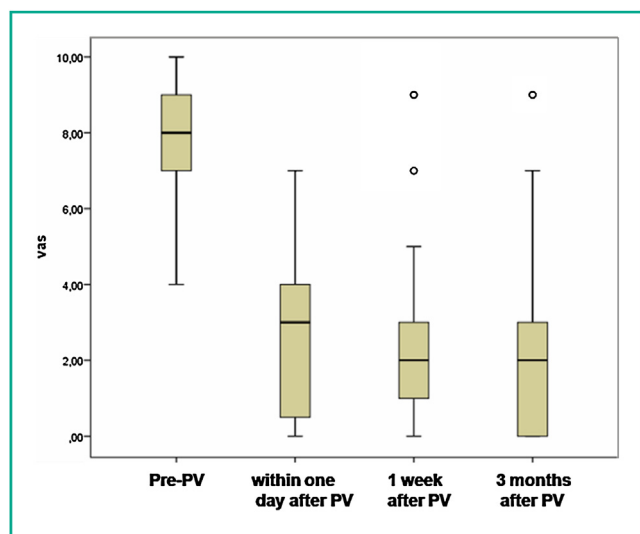


Figure 1. VAS scores before, within one day after, 1 week after and 3 months after the PV procedure (median min–max).

clinical symptoms were observed as a result of this leakage.

Table 2 shows the detailed analysis of 52 patients and their primary malignancies. Case examples are shown in Figs. 2 and 3.

Discussion

This study demonstrates that PV decreases the pain of patients with vertebral metastases who have excessive pain and/or surgery has great risks. Vertebral metastasis is often asymptomatic, but it can become symptomatic due to vertebral destruction caused by pathological fractures resulting in development of spinal instability and neural compression. It has been proven that chemotherapy, radiotherapy and hormonal treatments reduce osteolytic destruction and neurological damage. But these treatment modalities may not help with spinal stability, cord compression and pain reduction. Surgery can help with spinal stability, cord compression and pain reduction but it presents great risks for critical patients [11].

PV is a minimally invasive procedure where PMMA bone cement is injected into the vertebral body to treat the pain due to a vertebral compression fracture. Cement provides structural stabilization and a pain reduction effect in the vertebral body [12]. The main indication for PV in metastatic patients is to control local pain [13]. It can also be used to stabilize bones having lytic metastases and high fracture risk [14]. Weill et al. [15] succeeded in reducing pain in 24 out of 33 procedures in spinal metastasis patients using PV. Mikami et al. [13] state that the preoperative mean VAS score was reduced from 7.3 to postoperative 1.9 with PV performed on 141 metastatic vertebrae of 69 patients. Tseng et al. [4] showed that the preoperative mean VAS score of 8.1 decreased to 3.8 one day after and to 2.8 six months after PV. Alvarez et al. [11] reported that the preoperative VAS score of 9.1 decreased to 3.2 immediately after and to 2.8 three months after PV. Barragán-Campos et al. observed a

Table 2 Assessment of 52 patients with primary malignancy who had the PV procedure.

Sex (men/women)	24/28
Average age	63.98 ± 12.97 (21–86)
Median VAS score before PV	8 (4–10)
Median VAS score within one day after PV	3 (0–7)
Median VAS score 1 week after PV	2 (0–9)
Median VAS score 3 months after PV	2 (0–9)
Primary malignancy	52
Breast	14/52
Lungs	9/52
Prostate	7/52
Renal	5/52
Stomach	5/52
Others	12/52
Localization	95
Thoracic	41/95
T6	2/95
T7	5/95
T8	4/95
T9	2/95
T10	8/95
T11	7/95
T12	13/95
Lumbar	54/95
L1	17/95
L2	13/95
L3	8/95
L4	8/95
L5	8/95
PV approaches	95
Left transpedicular	63/95
Right transpedicular	7/95
Bipedicular	25/95
Vertebral loss of height	95
Grade 0	7/95
Grade 1	30/95
Grade 2	31/95
Grade 3	27/95
Complications on vertebral level	43/95
Leaks into the disc	20/95
Leaks into the epidural or paravertebral vein	20/95
Leaks into the disc and epidural or paravertebral vein	3/95

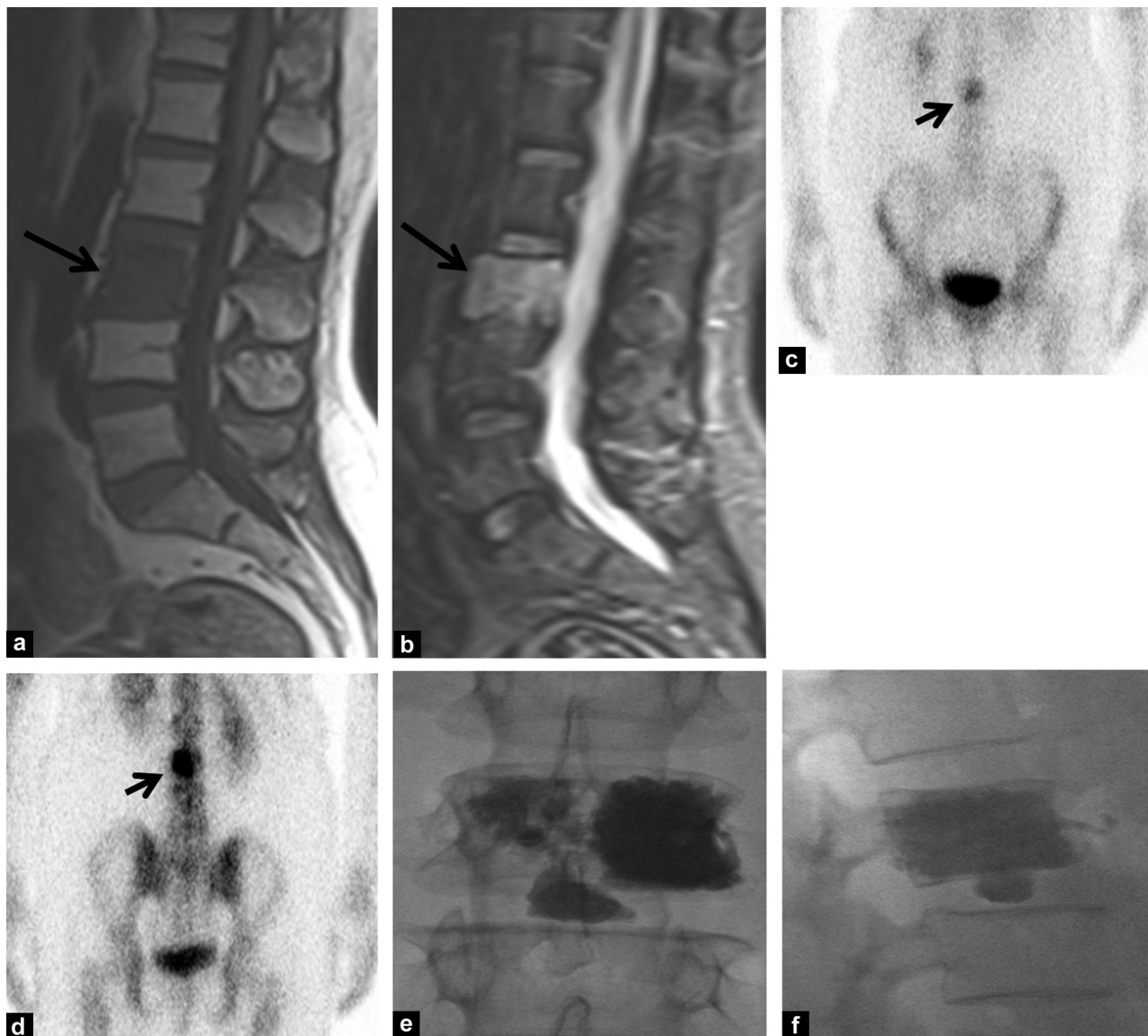

Figure 2. Hypointense metastatic involvement on sagittal T1-weighted image on L3 vertebral body (large arrow) (a) and hyperintense metastatic involvement on STIR sagittal image (large arrow) (b) in a 45-year-old woman with primary breast malignancy before PV. Increase in metabolic activity on L3 vertebral body is shown on bone scintigraphy scan (small arrow) (c, d). PMMA bone cement leakage into the L3-L4 disc and left paravertebral vein after PV (e, f).

significant decrease in VAS scores of patients with vertebral metastases of breast cancer [16]. In our department, median VAS scores of 79 metastatic vertebrae of 43 patients with primary malignancy was 8 before, 3 within one day after, 2 after 1 week and 2 three months after the procedure. In our study, the decreases in VAS scores after the procedure was consistent with the literature data. PV provides a quick relief of pain in patients with vertebral metastasis.

PMMA cement prevents the collapse of vertebra by strengthening the vertebral body [7]. PMMA causes damage to nerve endings and cytotoxic effects because of its heat releasing effect during polymerization [7,17]. Decrease in tumor progression or recurrence can be obtained from the antitumoral effect of the cement [18]. In order to achieve vertebral stiffness after PV, an average of 3.5 mL volume of PMMA is sufficient [4,19]. To achieve vertebral stiffness

after PV, Tseng et al. used [4] 5.16 ± 1.63 mL, Chew et al. [5] used less than 5 mL, and Barragán-Campos et al. [7] used 4.7 ± 1.55 mL of PMMA. The average PMMA amount used in our study to achieve sufficient vertebral stiffness was 4.91 ± 1.61 mL and was similar to what was used in other studies. In addition, there was no significant correlation between PMMA amount and VAS scores.

Serious complications of PV are rare [12,20,21]. Serious complications have been reported in approximately 1.1–1.3% of published cases [21]. Small leakage of PMMA into the pulmonary vessels through epidural or paravertebral veins is usually clinically insignificant. However, there are reported cases of pulmonary embolism [7,20,22,23]. The main reason for complications is believed to be the leakage of PMMA. The incidence of symptomatic and asymptomatic cement leakage varies from 2 to 73% [13], but Mousavi et al.

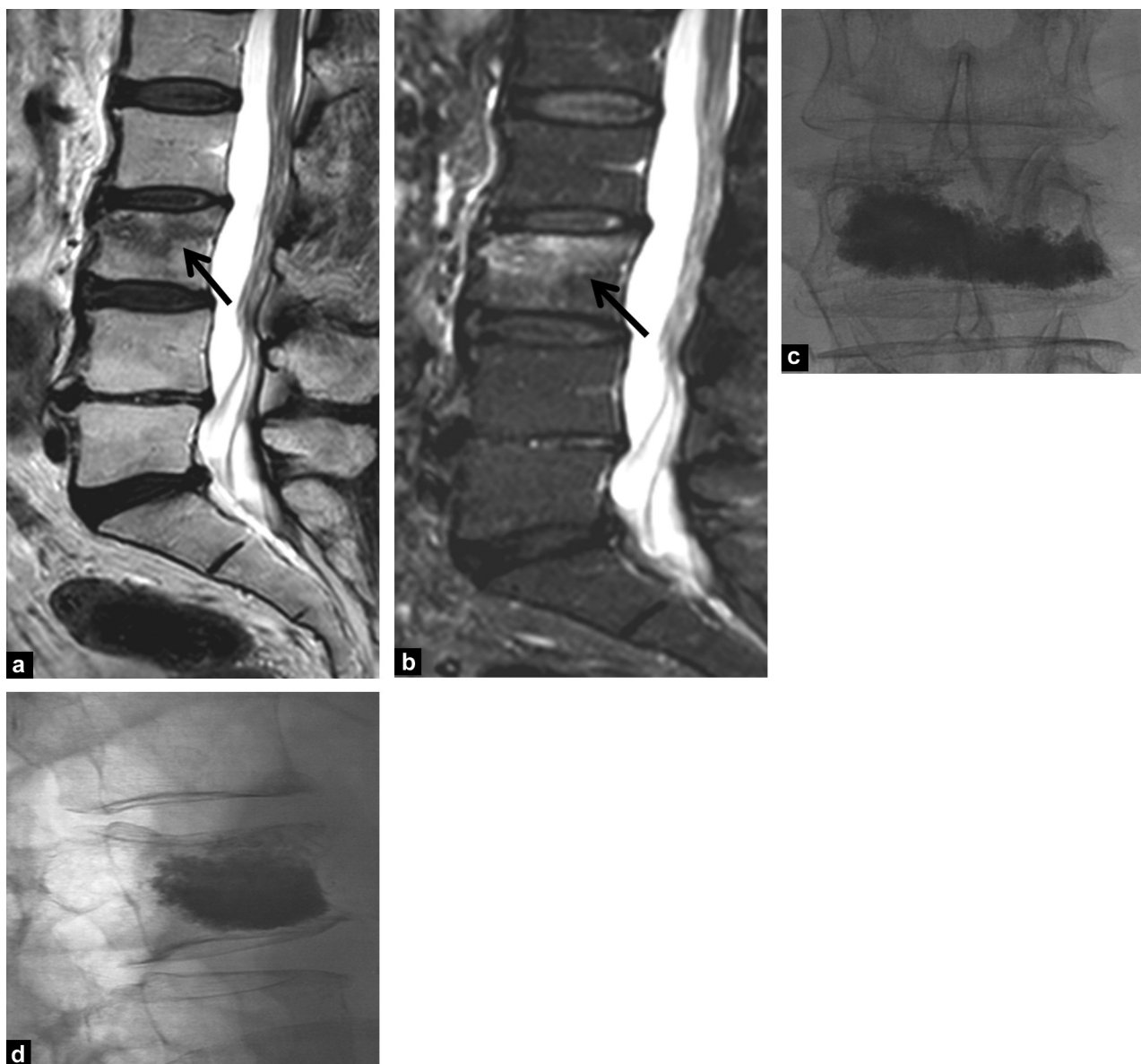


Figure 3. Hypointense metastatic involvement on sagittal T1-weighted image on L3 vertebral body (large arrow) (a) and hyperintense metastatic involvement on STIR sagittal image (large arrow) (b) in a 63-year-old woman with primary colon malignancy before PV. X-rays show metastatic involvement in L3 vertebra confirmed by bone biopsy after PV (c, d).

found a higher ratio of 87.9%. While there is no significant correlation between the reduction of pain and cement leakage or amount, serious complications are related to cement leakage [24]. Alvarez et al. [11] did not observe serious complications in patients with vertebral metastasis after PV, but they reported cement leakage in 12 of 27 vertebrae (44.4%). Mikami et al. [13] detected cement leakage in 49% of 69 patients with vertebral metastasis. Complications other than these are vertebral transverse process or pedicle fracture, paravertebral hematoma, epidural abscess, pneumothorax, cerebrospinal fluid leakage, seizure because of oversedation or respiratory arrest and death [20]. In our study, PMMA leakage was present in a total of 43 vertebrae (45.3%) (intradiscal leakage in 20 vertebrae [21.1%], leakage into the epidural or paravertebral veins in 20 vertebrae [21.1%] and leakage into both disc and the epidural or

paravertebral veins in 3 vertebrae [3.1%]). But no serious complications were observed in our patients.

BK, RF kyphoplasty, percutaneous ablation (radiofrequency or cryotherapy) and plasma-mediated radiofrequency ablation (coblation) can be used to treat vertebral fractures in addition to PV. Surgical vertebral body cementoplasty can be an alternative method for palliative treatment of patients who are not suitable for PV [25]. PV and BK are the most frequently used percutaneous interventional methods for vertebral compression fractures. RF kyphoplasty is a technique approved in the USA and Germany in 2007 and 2009, respectively. With this technique, ultraviscous cement activated by ex-vitro radiofrequency is applied to the vertebral body in a constant and controlled way. Thus, destruction of the spongy microarchitecture of the vertebral body is minimized. Röllinghoff et al.

provided fast and permanent improvement in treatment of 30 osteoporotic vertebral fractures by RF kyphoplasty [26]. Deschamps et al. successfully treated 75% of vertebral metastases smaller than 3 cm with percutaneous ablation (radiofrequency) [9]. Coblation is the process of giving radiofrequency at relatively low temperatures (40–70 °C) into the targeted tissue to dissolve molecular bonds, make a cavity and filling the cavity with PMMA. Coblation is an effective and reliable method used in high-risk patients who have excessive pain. Prologo et al. provided fast improvement in 14 of 15 patients who had painful vertebral metastases [27].

There are some limitations of our study. First, it is a retrospective study with no control group. Second, most of patients had no long-term follow-up because of their primary malignancies. Third, on follow-up, some patients could only be reached by phone. Face to face communication could be more effective than speaking on the phone. Fourth, VAS scores could be assessed at a maximum of 3 months after the procedure because some patients did not come to the control examination and could not be reached by phone.

Conclusion

PV is a simple, effective, reliable, easy to perform and minimally invasive procedure in patients with vertebral metastases, who have excessive pain and/or surgery has great risks.

Disclosure of interest

The authors declare that they have no conflicts of interest concerning this article.

References

- [1] Qian Z, Sun Z, Yang H, Gu Y, Chen K, Wu G. Kyphoplasty for the treatment of malignant vertebral compression fractures caused by metastases. *J Clin Neurosci* 2011;18:763–7.
- [2] Mesfin A, Buchowski JM, Gokaslan ZL, Bird JE. Management of metastatic cervical spine tumors. *J Am Acad Orthop Surg* 2015;23:38–46.
- [3] Dalbayrak S, Onen MR, Yilmaz M, Naderi S. Clinical and radiographic results of balloon kyphoplasty for treatment of vertebral body metastases and multiple myelomas. *J Clin Neurosci* 2010;17:219–24.
- [4] Tseng YY, Lo YL, Chen LH, Lai PL, Yang ST. Percutaneous polymethylmethacrylate vertebroplasty in the treatment of pain induced by metastatic vertebral column tumor. *Surg Neurol* 2008;7:78–83.
- [5] Chew C, Ritchie M, O'Dwyer PJ, Edwards R. A prospective study of percutaneous vertebroplasty in patients with myeloma and spinal metastases. *Clin Radiol* 2011;66:1193–6.
- [6] Galibert P, Deramond H, Rosat P, Le Gars D. Preliminary note on the treatment of vertebral angioma by percutaneous acrylic vertebroplasty. *Neurochirurgie* 1987;33:166–8.
- [7] Barragán-Campos HM, Vallée JN, Lo D, Cormier E, Jean B, Rose M, et al. Percutaneous vertebroplasty for spinal metastases: complications. *Radiology* 2006;238:354–62.
- [8] Chew C, Craig L, Edwards R, Moss J, O'Dwyer PJ. Safety and efficacy of percutaneous vertebroplasty in malignancy: a systematic review. *Clin Radiol* 2011;66:63–72.

- [9] Deschamps F, Farouil G, de Baere T. Percutaneous ablation of bone tumors. *Diagn Interv Imaging* 2014;95:659–63.
- [10] Genant HK, Wu CY, Van Kuijk C, Nevitt MC. Vertebral fracture assessment using a semiquantitative technique. *J Bone Miner Res* 1993;8:1137–48.
- [11] Alvarez L, Pérez-Higueras A, Quiñones D, Calvo E, Rossi RE. Vertebroplasty in the treatment of vertebral tumors: postprocedural outcome and quality of life. *Eur Vertebral Column J* 2003;12:356–60.
- [12] Anselmetti GC, Marcia S, Saba L, Muto M, Bonaldi G, Carpegiani P, et al. Percutaneous vertebroplasty: multi-centric results from EVEREST experience in large cohort of patients. *Eur J Radiol* 2012;81:4083–6.
- [13] Mikami Y, Numaguchi Y, Kobayashi N, Fuwa S, Hoshikawa Y, Saida Y. Therapeutic effects of percutaneous vertebroplasty for vertebral metastases. *Jpn J Radiol* 2011;29:202–6.
- [14] Deschamps F, de Baere T. Cementoplasty of bone metastases. *Diagn Interv Imaging* 2012;93:685–9.
- [15] Weill A, Chiras J, Simon JM, Rose M, Sola-Martinez T, Enkaoua E. Spinal metastases: indications for and results of percutaneous injection of acrylic surgical cement. *Radiology* 1996;199:241–7.
- [16] Barragán-Campos HM, Le Faou AL, Rose M, Livartowski A, Doz M, Astagneau P, et al. Percutaneous vertebroplasty in vertebral metastases from breast cancer: interest in terms of pain relief and quality of life. *Interv Neuroradiol* 2014;20:591–602.
- [17] San Millán Ruíz D, Burkhardt K, Jean B, Muster M, Martin JB, Bouvier J, et al. Pathology findings with acrylic implants. *Bone* 1999;25:85–90.
- [18] Roedel B, Clarençon F, Touraine S, Cormier E, Molet-Benhamou L, Le Jean L, et al. Has the percutaneous vertebroplasty a role to prevent progression or local recurrence in spinal metastases of breast cancer? *J Neuroradiol* 2014, <http://dx.doi.org/10.1016/j.neurad.2014.02.004>.
- [19] Farooq N, Park JC, Pollintine P, Annesley-Williams DJ, Dolan P. Can vertebroplasty restore normal load-bearing to fractured vertebrae? *Vertebral Column* 2005;30:1723–30.
- [20] Jensen ME, McGraw JK, Cardella JF, Hirsch JA. Position statement on percutaneous vertebral augmentation: a consensus statement developed by the American Society of Interventional and Therapeutic Neuroradiology, Society of Interventional Radiology, American Association of Neurological Surgeons/Congress of Neurological Surgeons, and American Society of Vertebral column Radiology. *AJNR Am J Neuroradiol* 2007;28:1439–43.
- [21] Barr JD, Jensen ME, Hirsch JA, McGraw JK, Barr RM, Brook AL, et al. Position statement on percutaneous vertebral augmentation: a consensus statement developed by the Society of Interventional Radiology (SIR), American Association of Neurological Surgeons (AANS) and the Congress of Neurological Surgeons (CNS), American College of Radiology (ACR), American Society of Neuroradiology (ASNR), American Society of Vertebral column Radiology (ASSR), Canadian Interventional Radiology Association (CIRA), and the Society of NeuroInterventional Surgery (SNIS). *J Vasc Interv Radiol* 2014;25:171–81.
- [22] Padovani B, Kasriel O, Brunner P, Peretti-Viton P. Pulmonary embolism caused by acrylic cement: a rare complication of percutaneous vertebroplasty. *AJNR Am J Neuroradiol* 1999;20:375–7.
- [23] Calmels V, Vallée JN, Rose M, Chiras J. Osteoblastic and mixed spinal metastases: evaluation of the analgesic efficacy of percutaneous vertebroplasty. *AJNR Am J Neuroradiol* 2007;28:570–4.
- [24] Mousavi P, Roth S, Finkelstein J, Cheung G, Whyne C. Volumetric quantification of cement leakage following percutaneous vertebroplasty in metastatic and osteoporotic vertebrae. *J Neurosurg* 2003;99:56–9.

- [25] N'dri Oka D, Tokpa A, Derou L. Surgical vertebral body cementoplasty as spinal cancer metastasis management. *Br J Neurosurg* 2014;30:1–6.
- [26] Röllinghoff M, Zarghooni K, Zeh A, Wohlrab D, Delank KS. Is there a stable vertebral height restoration with the new radiofrequency kyphoplasty? A clinical and radiological study. *Eur J Orthop Surg Traumatol* 2013;23:507–13.
- [27] Prologo JD, Bueth J, Mortell K, Lee E, Patel I. Coblation for metastatic vertebral disease. *Diagn Interv Radiol* 2013;19:508–15.