

RESEARCH ARTICLE

Reliability of Colposcopy in Turkey: Correlation with Pap Smear and 1-year Follow Up

Simender Mesci-Haftaci¹, Handan Ankarali², Mete Caglar³, Ali Yavuzcan³

Abstract

Background: A cytologic reading of a Papanicolaou (pap) smear followed, if the result is positive, by a colposcopic search for abnormal cells is the most common screening method for cervical cancer used worldwide. We aimed to present the correlation of smear and colposcopic findings with 6- to 12-month follow-up results and related factors in women who underwent colposcopy in Turkey. **Materials and Methods:** The study population consisted of women who attended the gynecology department and were referred for colposcopic evaluation in 2011-2012. A total of 232 women between ages 17 and 68 years were included. Colposcopy indications were ASCUS and higher lesions at cervical smear, macroscopic suspicious lesions, post-coital bleeding history with suspicious smear, and repeated cervical inflammation. All patients were recalled for 6- to 12-month follow-ups. **Results:** The most common colposcopy indication was ASCUS, and the most common biopsy result was inflammation. Nearly half of the patients returned for the control 6-month follow-up, and almost 20% of patients for a 1-year follow up. **Conclusions:** Colposcopic biopsy is an effective method in indicated patients but is not sufficient in itself if awareness of the subject is not raised in the population. One of the most important aims of cancer screening programs should be enabling patients in developing countries to take responsibility. Patients must be encouraged to apply to the hospital for better disease control.

Keywords: Cervical cancer - smear - colposcopy - compliance - Turkey

Asian Pac J Cancer Prev, 15 (17), 7317-7320

Introduction

Cervical cancer is the second most common malignancy in women worldwide after breast cancer, and is one of the leading causes of death for middle-aged women in the developing world, yet it is almost completely preventable if precancerous lesions are identified and treated appropriately (Ferlay et al, 2010, Aksan-Desteli et al, 2014). A cytologic reading of a Papanicolaou (Pap) smear followed, if the result is positive, by a colposcopic search for abnormal cells is the most common screening method for cervical cancer used worldwide. When correctly performed in a sufficient percentage of a population at risk, with proper confirmation of positive results, and proper treatment and follow-up, cytologic screening has been associated with reductions in the incidence and mortality rates of the disease. Currently, carcinogenic HPV testing is much more sensitive, but less specific, than cytology for prediction of subsequent risk of precancerous lesions (Porras, 2011). Although many countries are considering whether and how to switch from cytology-based to HPV test-based cervical screening, the latter is not in common use in developing countries; consequently, colposcopy remains the gold standard after suspicious cervical pathology.

We aimed to present the correlations of results of colposcopic biopsies, smear results, 1-year follow-up, and demographic factors in our gynecology department.

Materials and Methods

Our study included 232 females who underwent colposcopic biopsy after gynecologic evaluation between October 2011 and December 2012 at the Department of Gynecology, Duzce Public Hospital, Duzce, Turkey. The study protocol was approved by the Ethics Committee of Duzce University, and written informed consent was obtained from all subjects. Colposcopy indications were ASCUS and higher lesions, repeated cervicitis after treatment, macroscopically suspicious lesions, and postcoital bleeding with unsatisfactory smear. Colposcopic evaluations without biopsy have been excluded.

Patients with repeated inflammation were treated with antimicrobial and anti-inflammatory treatment according to CDC guidelines. They were given metronidazole (Flagyl, Eczacibasi, Turkey) orally for 7 days (500 mg, twice a day), and couples were advised to practice abstinence or barrier contraception during the treatment period. A repeat pap smear was taken after an interval of 12 weeks, and patients with a repeat report of inflammation

¹Department of Obstetrics and Gynecology, Duzce Public Hospital, ²Department of Biostatistics, ³Department of Obstetrics and Gynecology, School of Medicine, Duzce University, Duzce, Turkey *For correspondence: simendermesci@hotmail.com

were said to have persistent inflammatory smear; they were then subjected to colposcopy. A standardized colposcopic examination was performed by the same gynecologist. The presence of any acetowhite areas, leukoplakia, punctation, and atypical vessels was noted and classified according to colposcopic terminology by IFCPC. Patients with suspicious lesions on colposcopy were then subjected to cervical biopsy from these abnormal areas. The biopsy specimens were fixed in 10% formalin, sent for histopathological evaluation, and stained with hematoxylin and eosin (H and E). Patient data including age, parity, smoking habits, method of contraception, and menopausal status were recorded.

Cervical smears were classified according to the Bethesda System, and the cervical histologic results were categorized as normal, inflammation, cervical intraepithelial neoplasia grade 1, 2, or 3 (CIN1, CIN2, CIN3), adenocarcinoma in situ, or invasive squamous cell carcinoma.

Statistical analysis

Data are presented as means±standard deviations, numbers, or frequencies (percentages). One-way analysis of variance was used for numeric features and to compare pathology results according to age. Biopsy results, indications, and categorical variables were assessed using Pearson’s chi-square test. The possibility of error was accepted as 5%, and the PASW ver. 18 (SPSS, Inc., Chicago, IL, USA) software was used for the statistical analysis.

Results

Age, parity, and smoking

The mean age of 232 women who underwent colposcopic biopsy in our study was 40.3±9.95, and there were no significant relationships between age, parity, smoking, and biopsy results, as shown in 1 (p=0.888, 0.522, and 0.755, respectively). On the other hand, smoking had a significant relationship with indications for colposcopy (p=0.019). A small percentage of the smoking group had ASCUS; mostly, macroscopic/clinical features were observed.

Contraception

Regarding methods of contraception and biopsy, no significant differences were observed (p=0.137). A notable finding was the high percentage of women who did not use any method of contraception (47.4%).

Results of colposcopic evaluation

The colposcopic-directed cervical biopsies showed normal results in 11 (4.7%), chronic cervicitis in 139 (59.9%), CIN1 in 75 (32.3%), CIN2 in 3 (1.3%), CIN3 in 3 (1.3%), and squamous cancer in 1 (0.4%) women (Figure 1). When evaluated retrospectively, indications for colposcopic biopsies were ASCUS in 118 (50.9%), macroscopy/clinical in 90 (38.8%), LGSIL in 18 (7.8%), and HGSIL in 6 (2.6%) women (Figure 2).

As Table 1 shows, there was no significant relationship between colposcopic findings and biopsy results. P-values

Table 1. Colposcopic Findings and Results of Colposcopic Biopsy

Biopsy result	AW positivity No.	Leukoplakia No.	Punctation No.	AV No. %
Benign (11)	AW+10	L+0	P+1	AV+2
	AW-1	L-11	P-10	AV-9
Inflammation (139)	AW+134	L+8	P+8	AV+42
	AW-5	L-129	P-131	AV-97
CIN1 (75)	AW+72	L+7	P+6	AV+25
	AW-3	L-68	P-69	AV-50
CIN2 (3)	AW+3	L+0	P+0	AV+1
	AW-0	L-3	P-3	AV-2
CIN3 (3)	AW+3	L+1	P+1	AV+2
	AW-0	L-2	P-2	AV-1
CA (1)	AW+1	L+0	P+0	AV+0
	AW-0	L-1	P-1	AV-1

Table 2. Results of First and Second Control Smears (p<0.001)

Smear results	First control Smear (%)	Second control Smear (%)
No return	102 (43.9%)	180 (77.5%)
Normal	18 (7.8%)	15 (6.5%)
Inflammation	100 (43.1%)	35 (15.1%)
ASCUS	5 (2.2%)	2 (0.9%)
LGSIL	7 (3%)	0
HGSIL	0	0
CA	0	0

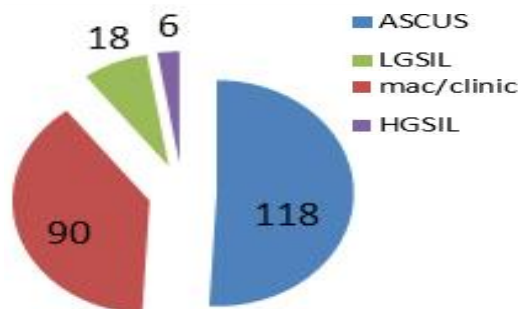


Figure 1. Indications for Colposcopy

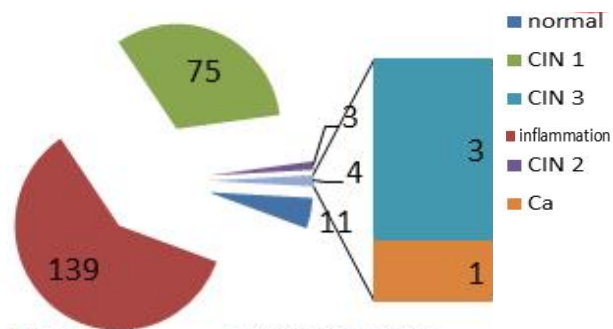


Figure 2. Results of Colposcopic Biopsy

were 0.869, 0.290, 0.589, and 0.411 for AW positivity, leukoplakia, punctation, and atypical vascularization, respectively.

One-year follow-up results

All participants were called for a control smear after 6 and 12 months. A total of 130 (56%) women returned for the first control, and 52 (22.4%) for the second. The results of control smears are shown in Table 2.

Discussion

ASCUS Pap smear results may be triaged using reported repeated cytology, colposcopy, or HPV testing. Although HPV DNA testing has been shown to be a promising tool in primary cervical cancer screening, as it is more sensitive in detecting CIN lesions than cytology, HPV DNA testing is more expensive than cytologic study (Poomtavorn et al., 2011; Pity et al., 2012). That is why cervical smear and colposcopic evaluation are currently more practical in developing countries. The most common indication for colposcopy was ASCUS, and inflammation was the most common (59.9%) histopathological finding. The inflammation percentage was higher than those reported in the literature. According to a recent study that included 266 patients with ASCUS, 134 of 266 patients (50.4%) had CIN; of these 134 patients, 97 (72.4%) had CIN1 and 37 (27.6%) had CIN2-3. (Poomtavorn et al., 2011). Our colposcopic biopsy results were 32.3% for CIN1 and 2.6% for CIN2-3. In another study, 186 of 437 patients (42.5%) had CIN1 and 169 patients (38%) had CIN2-3. (Tatiyachonwiphut et al., 2014).

Colposcopy-directed biopsies are recommended for women with LSIL cytology, primarily to exclude a high-grade lesions. (Ouitrakul et al., 2011). Although ~15-30% of those women have negative biopsy results, they are routinely subjected to follow-up because of uncertainty about the risk of precancerous lesions missed by a colposcopic biopsy. (Wentzensen et al., 2009; Matsumoto et al., 2012). In our study, according to smear results, the rate of precancerous cytology (LGSIL+HGSIL) was 10.4%, and the cervical intraepithelial neoplasia rate was 34.9%. In the first control smear, the percentage with LGSIL was 3%, and no HGSIL was observed. In the second control (after 1 year), we observed no precancerous lesions. However, the inflammation rate was high (approx. 50%), even at the second control. With these high inflammation rates the reliability of cervical smears for cancer screening is uncertain.

Smoking is a risk factor for CIN and invasive cancer development and has been reported to be associated with a decreased probability of regression of precancerous lesions (Matsumoto et al., 2010). However, we found no difference between the groups regarding smoking.

The inflammation rates in our pathology results were very high: 59.9%, 43.1%, and 15.1% for colposcopy, first smear, and second smear, respectively. This might be related to our inclusion criteria, which included repeated cervicitis, but that is not enough to explain the results. We included repeated cervicitis as a colposcopy indication because in a recent study, a 16.67% incidence of CIN in women with persistent inflammatory pap smear was reported (Bhutia et al, 2011). The incidences of CIN and invasive carcinoma in women with persistent inflammatory pap smears over just 2 weeks were found to be 20.6% and 0.7%, respectively, in another study (Dasari et al, 2010). One must not see a report of inflammation on pap smear in isolation and ignore it as being insignificant. If inflammation persists then we must consider evaluating the patient further by colposcopy.

There were two limitations to our study. First, the

atrophy of the cervix, retraction of the squamo-columnar junction (SCJ), and reduced cellular exfoliation in post-menopausal women may lead to an unsatisfactory colposcopic examination and decrease in the accuracy of colposcopy, with subsequent misdiagnosis of CIN (Baldauf et al, 1997; Cheng et al, 2013). A previous study revealed that pre-treatment of the cervix, such as physical manipulation of the cervix by a cotton-tipped applicator and use of estrogen or misoprostol prior to examination, may increase the rate of satisfactory colposcopy. We performed the same standard procedure without regard to menopausal status in all patients. The other limitation was the relatively short observational period (1 year), because precancerous lesions of the cervix tend to progress slowly. However, at the 1-year follow-up, only 20% of the patients returned for the control. Therefore, cervical smear screening (even for low-grade lesions) and the need for follow-up should be discussed meticulously with patients in developing countries.

In conclusion, colposcopy is not a “gold standard”, but neither is histology or cytology. The total picture informs management of the individual woman. The training in and quality of colposcopy must be improved (Nazeer et al., 2011). Current NHSCSP guidelines state that women with low-grade cytological abnormalities who have a satisfactory normal colposcopy (type 1 or type 2 transformation zone, which is normal, with or without a directed biopsy) are at low risk of developing cervical cancer, and recommend management of such women by repeat cytological assessment at 6 months (Kelly RS et al., 2012) However, lack of awareness in the population regarding cancer risks might lead to progression of cancer over a long period; therefore, we think that international guidelines should be modified regarding the features of the population of developing countries.

References

- Aksan-Desteli G, Gursu T, Baykal CM (2014). Is the loop electrosurgical excision procedure necessary for minor cervical cytological abnormalities? *Asian Pac J Cancer Prev*, **15**, 305-8.
- Ayensu-Coker L, Sanchez J, Zurawin R, Dietrich JE (2009). Use of misoprostol for management of unsatisfactory colposcopy in the adolescent : a case report of review of the literature. *J Pediatr Adolesc Gynecol*, **22**, 139-41.
- Baldauf JJ, Dreyfus M, Wertz JP, et al (1997). Consequences and treatment of cervical stenoses after laser conization or loop electrosurgical excision. *J Gynecol Obstet Biol Reprod (Paris)*, **26**, 64-70.
- Bhutia K, Puri M, Gami N, Aggarwal K, Trivedi SS (2011). Persistent inflammation on Pap smear: does it warrant evaluation? *Indian J Cancer*, **48**, 220-2.
- Cheng X, Feng Y, Wang X, et al (2013). The effectiveness of conization treatment for post-menopausal women with high-grade cervical intraepithelial neoplasia. *Exp Ther Med*, **5**, 185-8.
- Dasari P, Rajathi S, Kumar SV (2010). Colposcopic evaluation of persistent inflammatory Pap smear: A prospective analytical study. *Cytojournal*, **5**, 7-16.
- Ferlay J, Shin HR, Bray F, et al (2010). Estimates of worldwide burden of cancer in 2008: GLOBOCAN 2008. *Int J Cancer*, **127**, 2893-917.

- Kelly RS, Walker P, Kitchener H, Moss SM (2012). Incidence of cervical intraepithelial neoplasia grade 2 or worse in colposcopy-negative/human papillomavirus-positive women with low-grade cytological abnormalities. *BJOG*, **119**, 20-5.
- Matsumoto K, Hirai Y, Furuta R, et al (2012). Subsequent risk for cervical precancer and cancer in women with low-grade squamous intraepithelial lesions unconfirmed by colposcopy-directed biopsy: results from a multicenter, prospective, cohort study. *Int J Clin Oncol*, **17**, 233-9.
- Matsumoto K, Oki A, Furuta R, et al (2010). Tobacco smoking and regression of low-grade cervical abnormalities. *Cancer Sci*, **101**, 2065-73.
- Nazeer S, Shafi MI (2011). Objective perspective in colposcopy. *Best Pract Res Clin Obstet Gynecol*, **25**, 631-40.
- Quitrakul S, Udomthavornasuk B, Chum Worathayi B, Iuanratanakorn S, Supoken A (2011). accuracy of colposcopically directed biopsy in diagnosis of cervical pathology at srinagarind hospital. *Asian Pac J Cancer Prev*, **12**, 2451-3.
- Poomtavorn Y, Suwannaruk K, Thaweekul Y, Maireang K (2011). Risk factors for high-grade cervical intraepithelial neoplasia in patients with atypical squamous cells of undetermined significance(ASC-US) Papanicolaou Smears. *Asian Pac J Cancer Prev*, **12**, 235-8.
- Porras C, Wentzen N, Rodriguez A, et al (2012). Switch from cytology-based to human papillomavirus test-based cervical screening: implications for colposcopy. *Int J Cancer*. 130, 1879-87.
- Pity IS, Shamdeen MY, Wais SA (2012). Follow up of atypical squamous cell Pap Smears in Iraqi women. *Asian Pac J Cancer Prev*, **13**, 3455-60.
- Sankaranarayanan R, Gaffikin L, Jacob M, Sellors J, Robles S (2005). A critical assessment of screening methods for cervical neoplasia. *Int J Gynecol Obstet*, **89**, 4-12.
- Sexually transmitted diseases treatment guidelines (2002). Centers for disease control and prevention. *MMWR Recomm Rep*, **10**, 1-78.
- Tatiyachonwiphut M, Jaishuen A, Sangkarat S et al (2014). Agreement between colposcopic diagnosis and cervical pathology: Siriraj hospital experience. *Asian Pac J Cancer Prev*, **15**, 423-6.
- Wentzensen N, Schiffman M, Dunn ST et al (2009). Grading the severity of cervical neoplasia based on combined histopathology, cytopathology, and HPV genotype distribution among 1,700 women referred to colposcopy in Oklahoma. *Int J Cancer*, **124**, 964-9.
- Walker P, Dexeus S, De Palo G, et al (2003). International terminology of colposcopy: An updated report from the international federation for cervical pathology and colposcopy. *Obstet Gynecol*, **101**, 175-7.