

Case Reports

Embolised Stent Into the Circumflex Coronary Artery During Percutaneous Coronary Intervention

Cihangir UYAN,¹ MD, Hüseyin GÜNDÜZ,¹ MD, Hüseyin ARINC,¹ MD,
and Ramazan AKDEMİR,² MD

SUMMARY

Dislodgement and embolisation of the new generation of coronary stents before deployment are rare. If it is impossible to withdraw the embolised stent from the coronary artery, the stent may be crushed into the side wall of the coronary artery with a balloon over a wire passed alongside the embolised stent. (Int Heart J 2006; 47:125-129)

Key words: Embolised stent, Balloon angioplasty, Coronary artery disease

THE advent of stents and their increasingly widespread use has undoubtedly resulted in a huge improvement in intravascular intervention, but at the same time it has brought to the practice of angioplasty a plethora of various complications. It is worth considering these under a separate heading and in some detail since the use of stents seems set to increase. Stent dislodgement and embolisation are serious complications in coronary intervention. They were not rare when using first generation stents.¹⁻³⁾ Most new interventional cardiologists have not commonly encountered these complications because the new generation of stents are often not attached to a balloon.

CASE REPORT

A 53 year-old man was admitted for a postmyocardial infarction examination. Ten days earlier, he had suffered an inferolateral myocardial infarction. ST-elevation, T-wave inversion, and pathological Q waves in leads II, III, aVF, and V5-6 were present. He had no complaints and was a chronic cigarette smoker. The pulse rate was 85 beats/min and the arterial blood pressure was 110/85 mmHg. Examination of his organ systems revealed all were normal. An echocardiographic examination showed a hypokinetic inferior wall. The left anterior descending and right coronary arteries were normal on coronary angiography.

From the ¹ Department of Cardiology, Izzet Baysal Medical Faculty, Abant Izzet Baysal University, Golkoy, Bolu, and

² Department of Cardiology, Düzce Medical Faculty, Abant Izzet Baysal University, Düzce, Turkey.

Address for correspondence: Cihangir Uyan, MD, Department of Cardiology, Izzet Baysal Medical Faculty, Abant Izzet Baysal University, 14280, Golkoy, Bolu, Turkey.

Received for publication May 9, 2005.

Revised and accepted September 1, 2005.

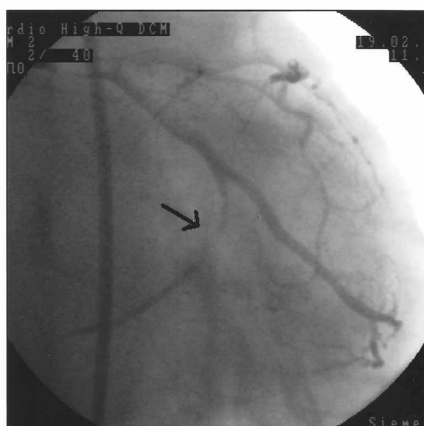


Figure 1. Total occlusion of left circumflex coronary artery at anterior caudal (45 degree caudal) position, (arrow shows culprit lesion).

There was total occlusion in the posterolateral branch of the left circumflex coronary artery (Figure 1). The distal part of the infarct related artery had collateral circulation retrogradely. We decided to perform percutaneous coronary intervention for the total occlusion. We crossed the total occlusion with a 0.014 floppy guidewire (Marine, USA) and then dilated the lesion with a 2.0×20 mm Classic NM balloon (Neich Medical, USA) at 12 atmospheres for 30 seconds. During the coronary stent implantation, the coronary stent system pushed the guiding catheter into the aorta, while passing to the left main coronary artery from the guiding catheter. The guidewire came back to the body of the circumflex artery from the posterolateral branch. While attempting to insert the coronary stent system into the guiding catheter, the stent (Duraflex, 2.5×18 mm, Avantec Vascular, UK) was dislodged and embolised into the proximal part of the obtuse margin branch of the circumflex artery. A new stent (NIR-Elite 2.5×18 mm, Boston Scientific, USA) was implanted at 10 atmospheres into the posterolateral branch of the left circumflex coronary artery. After implantation of a new stent to the culprit lesion, we retracted the guidewire and then pushed the guidewire into the stent which had been embolised to the obtuse margin branch of the circumflex artery. We passed the guidewire through the embolised stent, pushed the balloon through the guidewire; passed the balloon of the embolised stent through the inside of the stent, inflated the balloon to 6 atmospheres, and started to pull the stent over the balloon. While pulling the stent over the balloon, the stent was embolised again to the distal part of the obtuse margin branch of the circumflex artery. We attempted to pass with guidewire through, the stent, but it was not possible. We

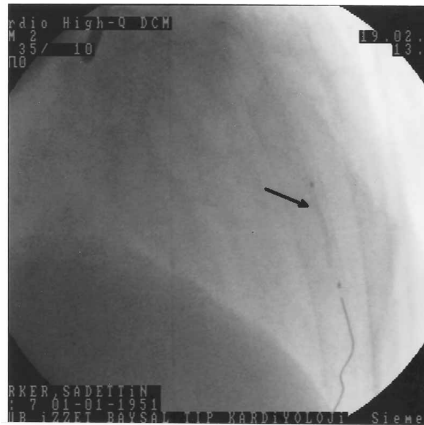

Figure 2. Just before crushing the stent into the side wall of the obtuse margin of the circumflex coronary artery with a balloon catheter at right anterior oblique cranial (45 degree cranial) position (arrow shows embolised stent in coronary artery).

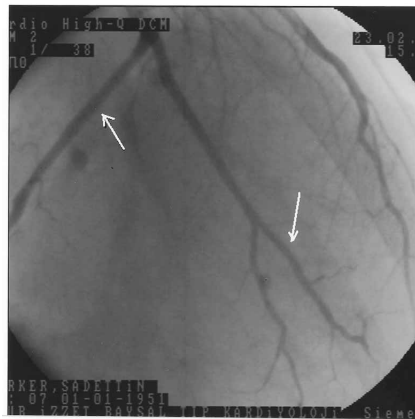


Figure 3. The infarct related and embolised stent coronary artery is patent at the right anterior oblique position (upper left arrow shows stented culprit lesion region, lower right arrow shows crushed embolised stent region).

inflated a new balloon (Eucatech AG, 2.0 × 20 mm, Germany) to 14 atmospheres near the stent in order to crush it into the side wall of the coronary artery (Figure 2) because we did not have a coronary stent withdrawal system. We finished the PCI procedure. Enoxaparine (60 mg, bid) and clopidogrel (75 mg) were given to the patient for anticoagulation. Four days later, the infarct related artery and embolised stent artery were patent in a control coronary angiography (Figure 3).

DISCUSSION

Stent embolisation is used to describe the loss of the stent from the delivery system. The dislodging may occur at the guide tip, when traversing the coronary artery proximal to the lesion, or in the lesion itself. If the guide choice and stability are not good the guide will be displaced from the coronary ostium as the stent exits the guide and meets resistance in the coronary artery. The stent can not be pushed on because there is no backup. Either the guide can be advanced over the stent or the stent can be withdrawn into the guide until a better guide position is found. Either maneuver may cause stent displacement and embolisation. This complication is avoided by choosing appropriate equipment: a low profile balloon-mounted stent that is well attached to the balloon, a guide catheter that will help fit snugly and provide back-up and possibly a stiffer wire that helps to straighten bends in the coronary artery and reduce resistance. However, whatever difficulties are encountered with equipment choice, the most important means of avoiding this complication is to take great care with the manipulations as the stent exits or re-enters the guide. Maneuvering of the guide catheter will often straighten the guide tip to allow the stent and its delivery catheter to become coaxial and permit uneventful passage in either direction. Unnoticed proximal coronary lesions or calcification can cause the stent to be held up or displaced as it traverses the artery towards the target lesion.⁴⁾

Dislodgement and embolisation of the new generation coronary stents before deployment are rare and challenging complications of intracoronary stenting. Reported incidence varies between 0.56% to 0.90%. Intracoronary embolisation may cause arterial occlusion with potentially adverse sequelae and may result in clinically relevant cardiac ischemia or peripheral embolisation during rescue attempts. However, systemic embolisation complicating intracoronary stenting before deployment is rare and was not associated with any clinical sequelae.⁵⁾

Embolisation of the stent within the coronary artery can be a lot more problematic than if it is lost in the wider circulation when in general they rarely cause problems. Nevertheless, strenuous efforts at stent retrieval should be made. If the stent is lost in the coronary artery but is still on the guidewire, retrieval can often be achieved with a very low profile balloon inflated enough to secure the stent which can then be withdrawn. The stent can either be secured by the balloon being inflated within it, a method that still may cause problems as the stent will not be very securely attached to the balloon, or brought to a position on the balloon catheter shaft proximal to the balloon so that when the balloon is slightly inflated the stent is secure and can not come off the balloon catheter. If withdrawal of an embolised stent is not possible, the stent may be deployed where it

is. If the stent is lost from the wire a second wire and balloon may be passed alongside and the stent crushed into the side wall of the coronary artery. Other means of retrieving stents include snares which may be fashioned from long wires doubled over and introduced into a 5 or 6 F catheter or specifically-designed devices which are available on the market.¹⁾

This case describes a patient who underwent stent implantation to the posterolateral branch of the circumflex artery, during which the stent was embolised to the body of the left circumflex artery. While attempting to withdraw the stent with a balloon catheter, it was embolised to the marginal branch of the circumflex artery again. When it is impossible to withdraw the embolised stent from the coronary artery, the stent may be crushed into the side wall of the coronary artery with a balloon over the wire passed alongside the embolised stent.

REFERENCES

1. Veldhuijzen FL, Bonnier HJ, Michels HR, el Gamal MI, van Gelder BM. Retrieval of undeployed stents from the right coronary artery: report of two cases. *Cathet Cardiovasc Diagn* 1993; 30: 245-8.
2. Kobayashi Y, Nonogi H, Miyazaki S, Daikoku, S, Yamamoto Y, Takamiya M. Successful retrieval of unexpanded Palmaz-Schatz stent from left main coronary artery. *Cathet Cardiovasc Diagn* 1996; 38: 402-4.
3. Wong PH. Retrieval of undeployed intracoronary Palmaz-Schatz stents. *Cathet Cardiovasc Diagn* 1995; 35: 218-23.
4. Norell MS, Perrins EJ. *Essential Interventional Cardiology*, 1st edition. China: W.B. Saunders Company, 2001: 86-7.
5. Yilmaz H, Belgi A, Demir I, Basarici I, Sancaktar O. Successful transcatheter retrieval of an embolised stent from the left ventricle. *J Invasive Cardiol* 2002; 14: 466-8.