

CASE IMAGE

Unruptured non-coronary sinus of Valsalva aneurysm presenting with nausea secondary to functional tricuspid stenosis

Fonksiyonel triküspit stenozuna sekonder bulantı ile başvuran rüptüre olmamış non-koroner sinüs Valsalva anevrizması

Mert İlker Hayiroğlu¹Muhammed Keskin¹Ahmet Yavuz Balcı²Servet Altay³Tolga Sinan Güvenç¹

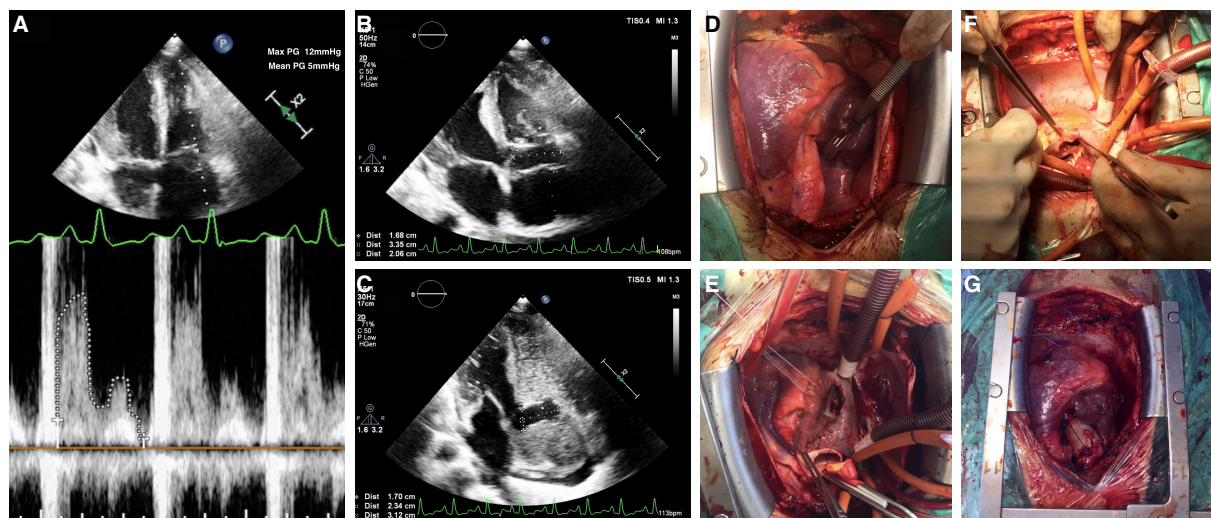
¹Department of Cardiology, Dr. Siyami Ersek Thoracic and Cardiovascular Surgery Center Training and Research Hospital, İstanbul, Turkey

²Department of Cardiovascular Surgery, Dr. Siyami Ersek Thoracic and Cardiovascular Surgery Center Training and Research Hospital, İstanbul, Turkey

³Department of Cardiology, Düzce University Faculty of Medicine, Düzce, Turkey

A 19-year-old male patient, who had been operated for coarctation of the aorta 7 years earlier, was admitted to the emergency department with nausea and vomiting. He complained of bilateral lower extremity edema beginning a month earlier. On physical examination, bilateral +3 pretibial edema concomitant with ascites was detected. Transthoracic echocardiography (TTE) was performed in order to determine the reason. TTE showed normal left ventricular ejection fraction of 60%, mild tricuspid regurgitation, and normal right ventricular systolic function with tricuspid annular plane systolic excursion of 22 mm (Video 1*). Bicuspid aortic valve with moderate aortic insufficiency was also detected. Interestingly, severe tricuspid stenosis with 12/5 mmHg maximal and mean gradient due to sinus of Valsalva aneurysm was observed. The aneurysm measured 2.3x3.1 cm after intravenous saline administration (Figure A-C; Video 2*) The patient's symptoms were considered to be secondary to tricuspid stenosis and he was hospitalized for further evaluation. Contrast enhanced thoracoabdominal computed tomography was performed to determine the structure of the aorta, and no other pathology was detected. Following symptomatic relief with medical therapy, the patient underwent sternotomy with a right atrial approach (Figure D). A large non-coronary sinus of Valsalva protruding into the right atrium was observed and resected (Figure E). The aortic root and bicuspid aortic valve were also resected (Figure F). The conduit was successfully anastomosed to the aortic valve position with a 23-mm Carbomedics mechanical valve (Sorin Group, Milan, Italy)

(Figure G). There was no need for tricuspid valve intervention. The patient was subsequently discharged in good health under anticoagulation therapy. A non-coronary sinus of Valsalva aneurysm, which is a very rare cause of right-sided heart failure, should be treated with surgery.



Figures– (A) The transvalvular 12/5 mmHg gradient of the tricuspid valve. **(B, C)** The non-coronary sinus of Valsalva aneurysm, measuring 3.3x2 cm and 2.3x3.1 cm, respectively, before and after intravenous saline administration. **(D)** Preoperative view after sternotomy. **(E)** The non-coronary sinus of Valsalva protruding into the right atrium, which was observed and resected. **(F)** Resection of the aortic root and bicuspid aortic valve. **(G)** The final status following Bentall procedure in addition to sinus of Valsalva resection.

*Supplementary video files associated with this presentation can be found in the online version of the journal.