

## LETTER TO THE EDITOR / *Vascular and interventional radiology*

### Use of Solitaire™ retrievable stent-assisted coiling technique for endovascular treatment of post-traumatic direct carotid cavernous fistula

**Keywords** Direct carotid cavernous fistula; Retrievable stent-assisted coiling technique; Solitaire™ stent

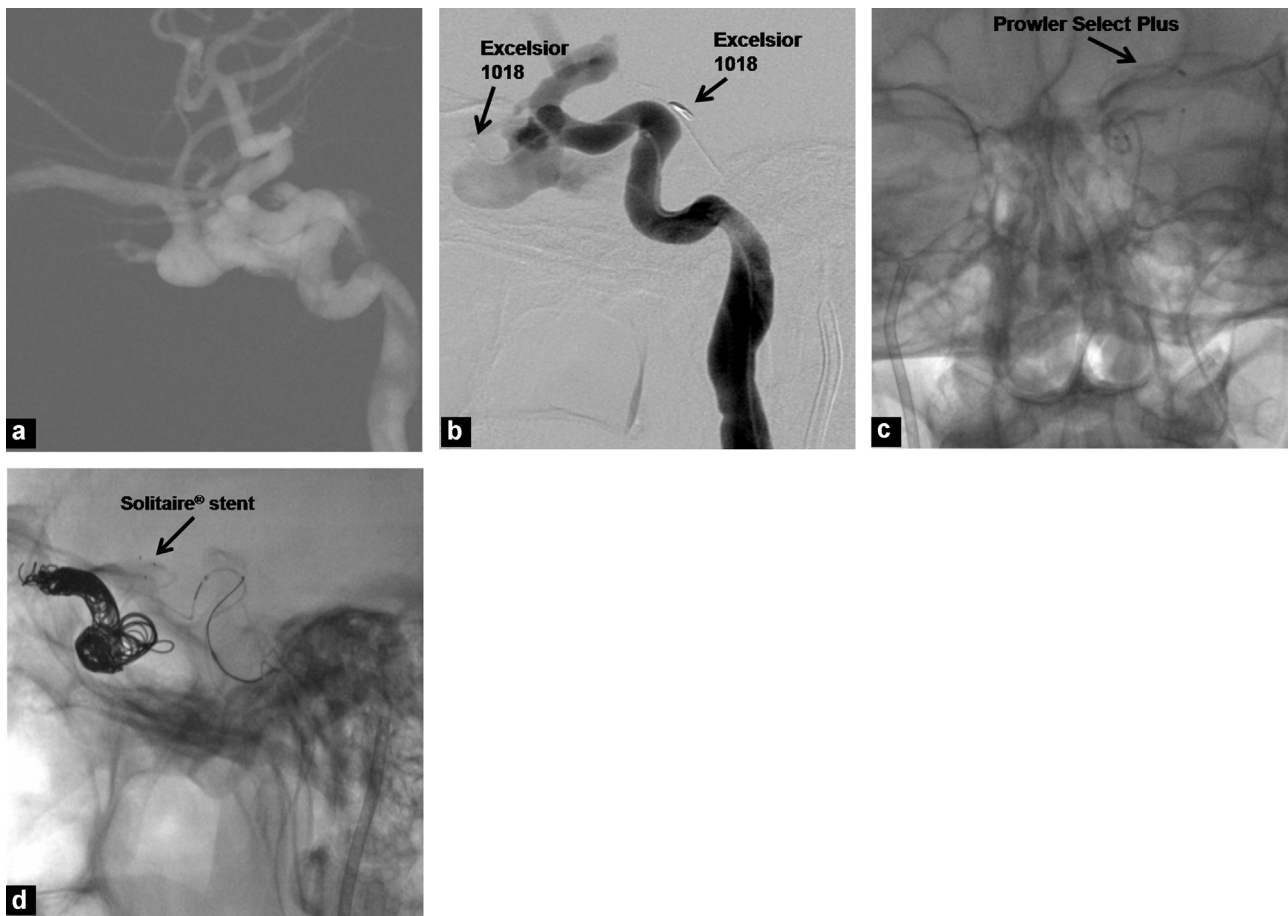
Dear editor,

Major endovascular techniques for direct carotid cavernous fistula (DCCF) treatment include transarterial and/or transvenous use of balloons, detachable coils, and liquid embolic agents and rarely, bare or coated stents [1]. Herein, retrievable stent-assisted coiling technique was applied to a patient with post-traumatic DCCF and a fistula tract in the left internal carotid artery (ICA). A completely retrievable Solitaire™ stent (Ev3, Irvine, CA, USA) was used to prevent coil migration and other potential complications of coil embolization.

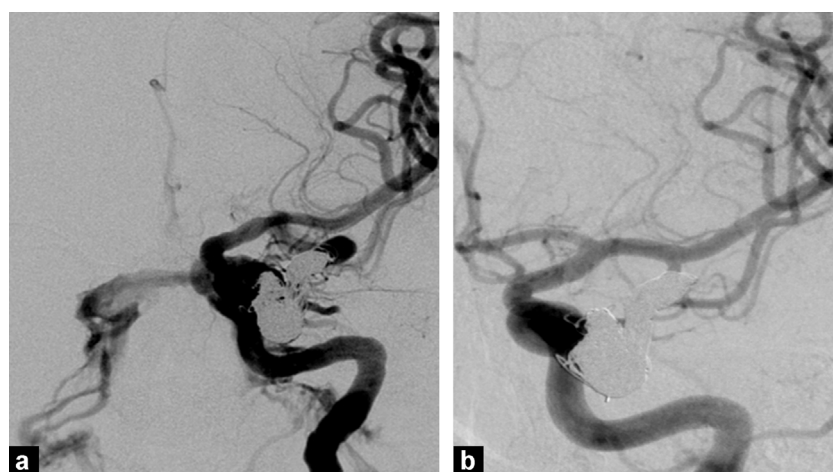
A 26-year-old man, involved in a car crash 2.5 months ago, was admitted to our hospital with proptosis and redness in his left eye. Selective cerebral digital subtraction angiography (DSA) showed a rupture in the clinoid segment of the left ICA communicating with the superior ophthalmic vein. Findings suggested a post-traumatic DCCF (Fig. 1a). Endovascular intervention was planned. Following the induction of general anesthesia, systemic heparinization was performed with an activated clotting time of 200–300 s. A 6F 80 cm guiding catheter (Neuron MAX) was placed in proximity to the left ICA through the right common femoral artery. A 6F introducer was inserted through the left common femoral vein, and a 6F guiding catheter (Envoy) was advanced towards the internal jugular vein. Using the right jugular path, a microcatheter (Excelsior 1018) was advanced from the inferior petrosal sinus to the cavernous sinus. The microcatheter could not be advanced to the fistula segment and appropriate coil embolization could not be obtained through the venous site because of strictures at the cavernous sinus. Using the arterial path, an Excelsior 1018

microcatheter was advanced from the carotid cavernous fistula location towards the cavernous sinus. A microcatheter (Prowler Select Plus) was placed into the left middle cerebral artery. A 4 mm × 20 mm Solitaire™ stent was placed into the carotid cavernous fistula region in the ICA. A 16 mm × 50 cm coil (Target XL 360° Standard) was used at the beginning of the embolization. Coils of various sizes (Target 360° and 3D Guglielmi Detachable) were used for the rest (Fig. 1b–d). The Solitaire™ stent was extracted from the fistula site after coil embolization. However, the cavernous sinus could not be embolized totally because of its occlusive segments (Fig. 2a). The patient was discharged from the hospital with wealth on postoperative day 1 and administered oral methylprednisolone (32 mg/day) for 15 days. Eye problems completely regressed one month later. DSA displayed total closure of the fistula (Fig. 2b).

Coils and embolic agents like n-butyl cyanoacrylate glue and ethylene vinyl alcohol copolymer (Onyx®) can be used for endovascular treatment of carotid cavernous fistulas [2,3]. These agents can be used separately or in combination by adopting transarterial and/or transvenous approaches [3]. Nadarajah et al. treated a DCCF with a flow-diverting stent [1]. We applied an endovascular technique using a Solitaire™ stent for endovascular treatment of a DCCF. Signorelli et al. [4] and Almekhlafi et al. [5] treated ruptured intracranial aneurysms by coil embolization using a Solitaire™ stent. In our patient, we used this technique for the endovascular treatment of DCCF. The Solitaire™ stent, which enables multiple retrievals, is a completely retrievable new intracranial stent. Its open slit, closed cell design and varying diameters from 4 to 6 mm, enables the use in tortuous and/or large vascular structures without risk of migration [6]. Balloons and bare stents can be used in endovascular treatment of DCCF to avoid the risk of coil migration. We applied the retrievable stent-assisted coiling technique by using combination of Solitaire™ stent and coil embolization. Intra-operative risk of coil migration and postoperative risk of thrombosis were avoided by this way. In addition, after removal of the stent anti-thrombotic drugs are not anymore needed. We believe that DCCF can be safely, effectively and successfully treated with this endovascular technique, with decreased complication rate.



**Figure 1.** a: carotid cavernous fistula associated with the superior ophthalmic vein communicating with the cavernous sinus in the clinoid segment of the left internal carotid artery (ICA); b: placement of Excelsior 1018 microcatheters into the cavernous sinus through arterial and venous sides; c: advancement of Prowler Select Plus microcatheter into the left middle cerebral artery; d: embolization of the cavernous sinus with coils of various sizes after introducing a Solitaire<sup>™</sup> stent into the carotid cavernous fistula in the left ICA with the help of Prowler Select Plus.



**Figure 2.** a: cavernous sinus and superior ophthalmic vein filling from the left internal carotid artery (ICA) through the carotid cavernous fistula is shown by digital subtraction angiography (DSA) performed after endovascular treatment; b: total closure of the carotid cavernous fistula in the clinoid segment of the left ICA is shown by the control DSA performed one month after endovascular treatment.

### Disclosure of interest

The authors declare that they have no competing interest.

### References

- [1] Nadarajah M, Power M, Barry B, Wenderoth J. Treatment of a traumatic carotid-cavernous fistula by the sole use of a flow diverting stent. *J Neurointerv Surg* 2012;4:e1.
- [2] Saeed Kilani M, Izaaryene J, Cohen F, Varoquaux A, Gaubert JY, Louis G, et al. Ethylene vinyl alcohol copolymer (Onyx®) in peripheral interventional radiology: indications, advantages and limitations. *Diagn Interv Imaging* 2015;96: 319–26.
- [3] Yu Y, Li Q, Huang Q, Zhang Y, Fang Y, Xu Y, et al. Embolization of direct carotid cavernous fistula with Onyx and coils under transarterial balloon protection. *Cardiovasc Intervent Radiol* 2014;37:679–85.
- [4] Signorelli F, Gory B, Turjman F. Temporary Solitaire stent-assisted coiling: a technique for the treatment of acutely ruptured wide-neck intracranial aneurysms. *AJNR Am J Neuroradiol* 2014;35:984–8.
- [5] Almekhlafi MA, Hockley A, Wong JH, Goyal M. Temporary Solitaire stent neck remodeling in the coiling of ruptured aneurysms. *J Neurointerv Surg* 2013;5:76–8.
- [6] Buyukkaya R, Hakyemez B, Erdogan C. Retrievable stent technique and coil embolization of high-flow iatrogenic cervical vertebral arteriovenous fistula: technical note. *Vasc Endovascular Surg* 2013;47:648–51.

O. Fatih Nas<sup>a,\*</sup>, R. Buyukkaya<sup>b</sup>, E. Kacar<sup>c</sup>,  
C. Erdogan<sup>a</sup>, B. Hakyemez<sup>a</sup>  
<sup>a</sup> *Uludag University, Faculty of Medicine,  
Department of Radiology, Bursa, Turkey*  
<sup>b</sup> *Duzce University, Faculty of Medicine,  
Department of Radiology, Duzce, Turkey*  
<sup>c</sup> *Afyon Kocatepe University, Faculty of Medicine,  
Department of Radiology, Afyonkarahisar, Turkey*

\* Corresponding author.

*E-mail addresses:* omerfatihnas@gmail.com  
(O. Fatih Nas), rbuyukkaya@gmail.com

(R. Buyukkaya), dremrekacar0258@hotmail.com  
(E. Kacar), cerdogan@uludag.edu.tr (C. Erdogan),  
bhakyemez@uludag.edu.tr (B. Hakyemez)

<http://dx.doi.org/10.1016/j.diii.2016.03.002>

2211-5684/© 2016 Éditions françaises de radiologie. Published by Elsevier Masson SAS. All rights reserved.