

Received: 2015.11.12
Accepted: 2015.12.14
Published: 2015.12.29

Radiobasilic Versus Brachiobasilic Transposition on the Upper Arm to Avoid Steal Syndrome

Authors' Contribution:
Study Design A
Data Collection B
Statistical Analysis C
Data Interpretation D
Manuscript Preparation E
Literature Search F
Funds Collection G

ABCDEF 1 **Okay Guven Karaca**
BCDEF 2 **Ahmet Nihat Basal**
BCDEF 2 **Ata Niyazi Ecevit**
BCDF 2 **Mehmet Kalender**
BDF 3 **Osman Tansel Darcin**
BCDE 4 **Mehmet Ali Sungur**

1 Department of Cardiovascular Surgery, Medical Faculty of Duzce University, Duzce, Turkey
2 Department of Cardiovascular Surgery, Konya Training and Research Hospital, Konya, Turkey
3 Department of Cardiovascular Surgery, Medical Faculty of Afyon Kocatepe University, Afyon, Turkey
4 Department of Biostatistics and Medical Informatics, Medical Faculty of Duzce University, Duzce, Turkey

Corresponding Author: Okay Guven Karaca, e-mail: drguven@gmail.com
Source of support: Departmental sources

Background: Although the proximal radial artery has been reported as an alternative inflow to prevent steal syndrome, brachiobasilic fistula has been reported to be associated with steal syndrome in 10–20% of cases. We aimed to compare proximal radiobasilic arteriovenous fistula (AVF) with brachiobasilic AVFs on the upper arm in terms of steal syndrome and outcomes.

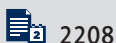
Material/Method: We used our institutional operative record database to identify 94 patients in whom brachiobasilic AVF (n=40) and radiobasilic AVF (n=54) were placed between January 2009 and December 2013. Postoperative complications such as steal syndrome, venous hypertension, and aneurysm were recorded.

Results: Steal syndrome was determined to occur less frequently in the radiobasilic AVF group (0% vs. 10%, P=0.03). The rates of other complications (bleeding, aneurysm, venous hypertension) between the 2 groups were similar, as were the patency rates.

Conclusions: Radiobasilic AVF was effective in reducing steal syndrome, with similar early and late outcomes.

MeSH Keywords: **Arteriovenous Fistula • Dialysis • Renal Insufficiency, Chronic**

Full-text PDF: <http://www.medscimonit.com/abstract/index/idArt/896642>



2208



2



6



15



Background

Forearm autogenous arteriovenous (AV) access has been recommended as the first choice for primary access for hemodialysis [1,2]. Patients who have exhausted all forearm veins on both sides, according to vein availability and surgical expertise, are suitable candidates for either forearm prosthetic access or upper-arm access of any type [1]. As with the other upper-arm arteriovenous fistulas (AVFs) that originate from the brachial artery, brachio-basilic AVFs (BBAVF) create more risks of steal syndrome than AVFs on the forearm [3–5]. The proximal radial artery has been used for inflow for upper-arm fistulas to prevent steal syndrome [6–8]. BBAVF has been performed by many surgeons and using various techniques, together with the increasing experience in its use. Although anastomosis of the basilic vein with proximal radial and ulnar arteries were performed, the most common site of preference for anastomosis has been the brachial artery [9]. However, guidelines recommend placing native AVFs as far distally in the upper extremity as possible.

In this study we aimed to compare proximal radio-basilic AVFs (RBAVF) with BBAVFs on the upper arm in terms of steal syndrome and outcomes.

Material and Methods

Patients

AVFs were placed in 950 patients in our clinic between January 2009 and December 2013. We used our institutional operative record/database to identify 94 patients who had undergone basilic vein transposition, consisting of BBAVF (n=40) and RBAVF AVF (n=54), among these 950 patients. In this retrospective study, in all patients who had exhausted all of their forearm veins on both sides, basilic vein transposition was performed before using prosthetic access. Patient data were obtained from inpatient charts, outpatient records, operating room notes, dialysis records, and phone calls. Patient characteristics collected for the purpose of this study were sex, age, and specific comorbidities (diabetes mellitus, hypertension, and hyperlipidemia).

Postoperative complications such as steal syndrome, venous hypertension, aneurysm, and bleeding were recorded. According to the results of the Doppler USG, we noted ≥ 2.5 mm basilic vein diameter, ≥ 3 mm diameter of the brachial artery, and ≥ 2 mm diameter of the radial artery. At 4–6 weeks after the operation, Doppler USG was performed on the AVF in order to check its maturation. Maturation was defined as blood flow of the fistula above 500 mL/min.

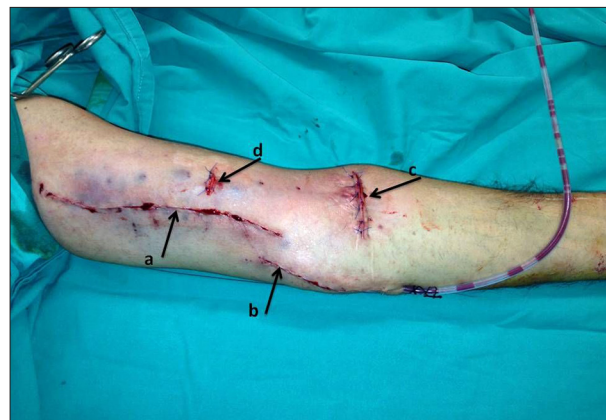

Figure 1. a: A single long longitudinal incision on the medial side of upper arm b: A second small longitudinal incision for expanded basilic vein c: A third short transverse incision made on the antecubital fossa d: A mini-incision made for subcutaneous tunnel on the upper arm.

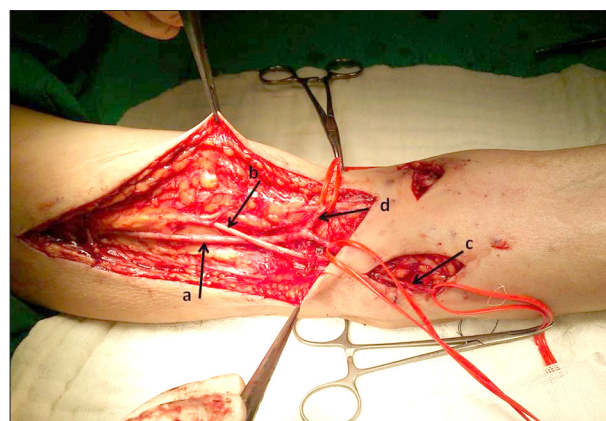


Figure 2. a: Exposure of the basilic vein on the upper arm b: The medial antebrachial cutaneous nerve c: Extended portion of the basilica vein on the forearm d: The median cubital vein.

Operations

All operations were performed under combined anesthesia (bupivacaine from AstraZeneca, Turkey and lidocaine from Adeka, Turkey). All BBAVFs were created as described by Dagher et al. [10] and all of them were 1-stage procedures. A single long longitudinal incision was made on the medial arm from the antecubital fossa to axilla to identify the basilic vein. Care was taken to avoid damage to the medial antebrachial cutaneous nerve of the upper arm. Tributaries of the vein were ligated. Once free, it was disconnected in the antecubital fossa. The basilic vein was isolated and marked to ensure appropriate orientation. A short segment of brachial artery was then isolated through the distal aspect of the incision or a single short transverse incision was made on the antecubital fossa.

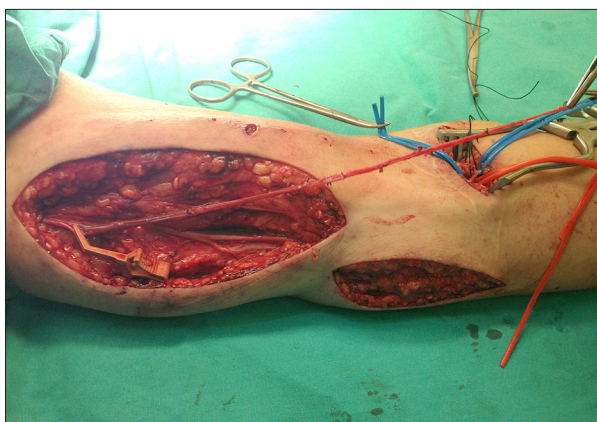


Figure 3. a: A long basilic vein.

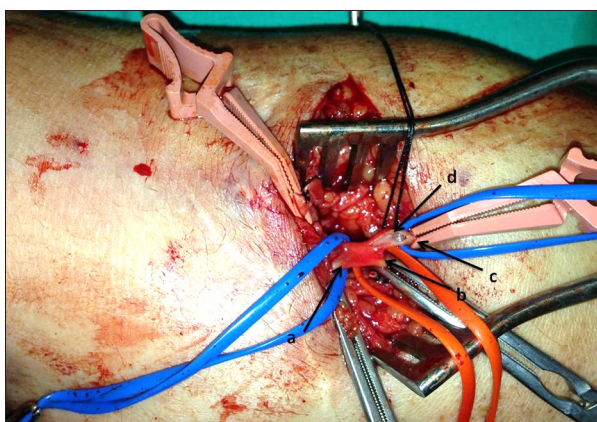


Figure 4. a: The brachial artery b: The ulnar artery c: The radial artery d: The arteriotomy.

The vein was transposed inside an anterolateral subcutaneous tunnel of the upper arm. The vein was carefully oriented and brought through the tunnel in a gentle curve, reaching the brachial artery without tension. The patients were systematically heparinized (5000 units of unfractionated heparin, intravenously) and the brachial artery was then mobilized for several centimeters. The basilic vein was anastomosed end-to-side to the brachial artery using 7/0 polypropylene.

All RBAVFs were performed as 1-stage procedures like BBAVFs. Two separate incisions were used to identify the basilic vein (a and b in Figure 1). Firstly, a long longitudinal incision was made superiorly on the medial epicondyle to extend to the axilla (a in Figure 1). The basilic vein was mobilized for more than 10 cm on the upper arm, starting from the axilla (a in Figure 2). Care was taken to avoid damage to the medial antebrachial cutaneous nerve of the upper arm (b in Figure 2). The second separate small longitudinal incision was started just below the medial epicondyle of the humerus and was extended laterally and inferiorly (b in Figure 1). The basilic vein was 5–7 cm further mobilized on the forearm (c in Figure 2). The median cubital vein was ligated (d in Figure 2). The basilic vein was dissected

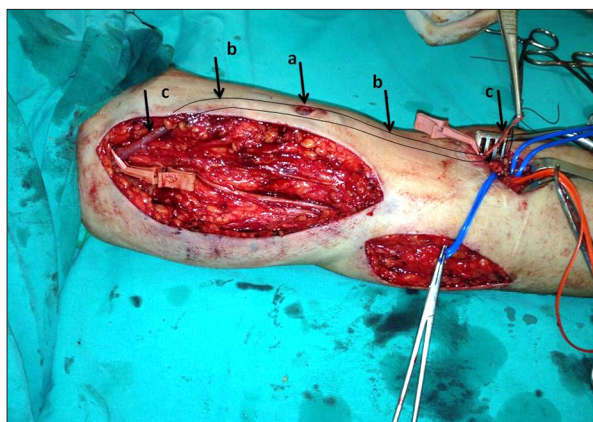


Figure 5. a: A mini-incision made for subcutaneous tunnel on the upper arm b: The subcutaneous tunnel between both the antecubital fossa and axillary ends of the incision c: The basilic vein passed through the subcutaneous tunnel.

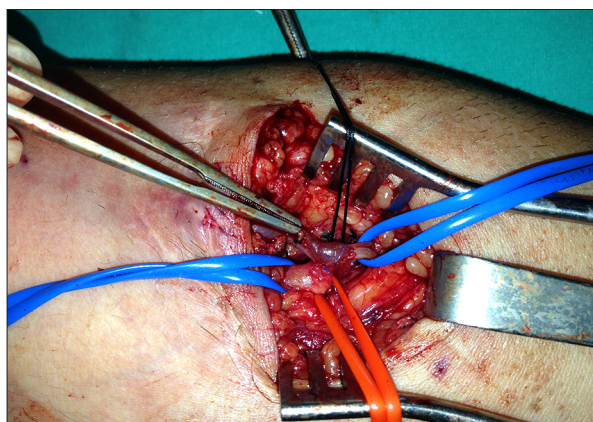


Figure 6. The anastomosis.

completely free and the branches were ligated using a simple tie or a suture ligature based on the size of the branches (Figure 3); thus, a long basilic vein was obtained (Figure 3). A third short transverse incision was made on the antecubital fossa (c in Figure 1). The brachial artery, radial artery, and ulnar artery were exposed and controlled with vessel loops (a, b and c in Figure 4). Attention was paid to avoid injury to the median nerve, which lay adjacent to the artery. A mini-incision was made for a subcutaneous tunnel on the upper arm (d in Figure 1, a in Figure 5). Then, the subcutaneous tunnel was prepared on the upper arm (b in Figure 5). The basilic vein was gently dilated with heparinized saline, marked to help maintain the proper orientation, and wrapped with a heparin-soaked sponge. The basilic vein was carefully tunneled by using a curved vascular clamp. The vein should be tunneled directly below the skin through the underlying fascia between both the antecubital and axillary ends of the incision (c in Figure 5). The patients were systematically heparinized (5000 units of unfractionated heparin, intravenously) and the brachial bifurcation

Table 1. Demographic and clinical characteristics of patients with BBAVF and RBAVF.

	RBAVF (n: 54)	BBAVF (n: 40)	P value
Age	53.78±14.61	62.48±13.77	0.004
Female	27 (50.0%)	20 (50.0%)	0.999
Non-dominant arm	44 (81.5%)	36 (90.0%)	0.251
Comorbidity	37 (68.5%)	29 (72.5%)	0.676
DM	25 (46.3%)	20 (50.0%)	0.722
HT	26 (48.1%)	23 (57.5%)	0.370
Cholesterol	8 (14.8%)	9 (22.5%)	0.338

Table 2. Complications in patients with BBAVF and RBAVF.

	RBAVF (n: 54)	BBAVF (n: 40)	P value
Successful hemodialysis	54 (100.0%)	39 (97.5%)	0.426
Patency of AVF	33 (61.1%)	15 (37.5%)	0.024
Complication (Steal syndrome, venous HT, or aneurysm)	5 (9.3%)	9 (22.5%)	0.075
Steal syndrome	0 (0.0%)	4 (10.0%)	0.030
Venous HT	1 (1.9%)	2 (5.0%)	0.573
Aneurysm	4 (7.4%)	3 (7.5%)	0.999
Exitus	8 (14.8%)	13 (32.5%)	0.042
Doppler USG (ml/min)	837.96±271.43	866.75±374.99	0.682

(brachial, radial, ulnar artery) was mobilized for several centimeters. Vascular clamps were placed (a, b, and c in Figure 4). Arteriotomy was made in such a way that approximately 1/3 of the incision was on the brachial artery and 2/3 of the incision was on the radial artery (d in Figure 4, Figure 5). The basilic vein was anastomosed end-to-side to the brachial bifurcation using 7/0 polypropylene (Figure 6). Following this procedure, the thrill was palpated. A closed-suction drain was placed in the dissected bed of the basilic vein and brought out through a separate stab incision. The subcutaneous tissues and skin were closed with an absorbable suture (Figure 1).

Follow-up

While postoperative thrill was palpated in all patients in RBAVF group, it was not able to be palpated in 1 patient in the BBAVF group. Four to six weeks following the operation, the patients were examined by Doppler ultrasonography to check for the maturation of AVF.

The patients who died, who underwent kidney transplantation, and in whom patency was not provided were excluded from

the follow-up. In the BBAVF group, a total of 25 patients were excluded from the follow-up; 1 patient due to kidney transplantation, 13 patients due to death, and 11 patients due to the inability to provide patency. In RBAVF groups, a total 22 patients were excluded from the follow-up; 8 patients due to death and 14 patients due to inability to provide patency.

Statistical analysis

Patients' demographic factors were compared by using the Fisher's exact test and the chi square test for categorical variables and *t* test for continuous variables. Fistula patency and fistula survival were analyzed by using life tables and Kaplan-Meier survival analysis. The patencies of the 2 groups were compared by using a log-rank test. Factors (age, sex, extremity, diabetes, hypertension, and hypercholesterolemia) potentially influencing the patencies of BBAVF and RBAVF were analyzed with Cox proportional hazards regression analysis. Statistical analysis was performed with the PASW v.18 software package. A *P* value of <.05 was considered statistically significant. Data are presented as mean ± standard deviation for continuous variables and frequencies and percentiles for categorical variables.

Results

During the study period, a total of 950 AVFs and 94 basilic vein transposition AVFs were placed. Demographic and clinical characteristics were compared between groups (Table 1).

The RBAVF group (53.78±14.61) was younger than the BBAVF group (62.48±13.77) (P=.004).

In 9 patients in the BBAVF group (22.5%) and in 5 patients in RBAVF group (9.3%), at least 1 complication (among complications such as steal syndrome, venous hypertension, and aneurysm) was observed (Table 2). However, when the patients were analyzed in terms of each complication separately, steal syndrome was observed to develop in the BBAVF group more frequently than in the RBAVF group (P=.030). Among hypertension, cholesterol, and diabetes mellitus, only diabetes mellitus was found have a significant effect on the development of steal syndrome. There were 4 patients (8.9%) having both steal syndrome and diabetes mellitus (P=.049). Three of the 4 patients who had steal syndrome had patent AVFs; in the other patient, a fistula was ligated because of the aggravation of the complaint and the patient's anxiety.

One of the patients was consulted because of arm pain during hemodialysis therapy. However, we found from the patient's history that the pain was in the form of resting pain, occurring especially at night, and it was not occurring only during the hemodialysis therapy. At the physical examination, digital brachial index was 0.49 and the thumb pulse oximetry reading revealed 79% oxygen saturation, with the other thumb pulse oximetry read 98% saturation. Although there was no wound in the hands of the patient, because there was a compliance with findings of class 3 steal syndrome, surgical intervention was proposed to the patient. However, due to fear of surgery, the patient insisted that the pain was occurring only during hemodialysis therapy, and did not accept the operation. In the other 2 patients the anastomoses were narrowed with the flow reduction method.

When the combined effects of the type of surgery and age on the steal syndrome was analyzed with logistic regression analysis, we observed that only the type of the surgery was effective in steal syndrome.

All patients tolerated the procedures. There was no intraoperative mortality. There was no significant difference between the groups (P=.426) in terms of maturation rates. AVFs of the 9 patients in the BBAVF group (22.5%) and 9 patients in the RBAVF group (16.7%) were found to be failed (P=.484). A mechanical thrombectomy operation was performed and the thrill was provided again. Warfarin and acetylsalicylic acid were administered to these patients postoperatively.

Mean follow-up periods in the BBAVF group and RBAVF group were 22.1±10.8 months (min: 0, max: 40) and 19.6±9.2 months (min: 2, max: 38), respectively. Primary patency rates at 1- and 2-year follow-up were 77% and 44% for the BBAVF group and 88% and 59% for the RBAVF group, respectively. Secondary patency rates in 1- and 2-year follow-up period were 83% and 50% for the BBAVF group, and 94% and 63% for the RBAVF group, respectively. There was no significant difference between the 2 groups in terms of the primary and secondary patency rates.

Discussion

Due to increasing experience, basilic vein transposition technique is increasingly preferred by surgeons in recent years. Following failure of antecubital AVF and Cimino-Brescia fistula, AVF with PTFE graft, originating from the brachial artery, may be preferred. However, autologous AVFs were suggested by more than 1 guideline [1,3]. At this stage, basilic vein transposition should be preferred. Following its first description in 1970, the basilic vein transposition AVF has been performed in several different techniques, such as 1-stage procedure, 2-stage procedure (elevation and transposition), keyhole technique, and video-assisted transposition [11–13]. However, in all these techniques, the basilic vein was freed down to the elbow and generally was anastomosed to the brachial artery. Regarding steal syndrome, in addition to risk factors such as female sex, peripheral arteriosclerosis, diabetes, and multiple operations on the same limb, it is well-known that AVFs using the brachial artery carry more risk of steal syndrome than fistulas using the radial artery [3–5,14]. Tordoir et al. reported that symptomatic ischemia may develop in 10–25% of brachiocephalic and basilic AVFs, 4.3–6% of forearm prosthetic AVFs, and 1–1.8% of radiocephalic AVFs [3]. In our study, all patients who had steal syndrome had their anastomosis located in the brachial artery. The proximal radial artery has been used by many authors in order to avoid steal syndrome [6,7,15].

We extended the basilic vein to the proximal radial artery and called it RBAVF. Steal syndrome was not seen in the RBAVF group. In the BBAVF group, steal syndrome was determined to occur more frequently, which is consistent with the literature. It is known that the major disadvantage of radiocephalic AVFs is a lower blood flow rate [2]. For this purpose, in the RBAVF group, a portion of the anastomosis (proximal 1/3) was extended to the brachial artery. We observed that there was no significant difference between the RBAVF and BBAVF groups in terms of patency and flow rate of the arteriovenous fistula.

Patients who undergo hemodialysis with the indication of end-stage renal failure need many additional interventions in the long-term, and the patients are prone to surgical complications

due to these interventions. In recent years, the use of basilic vein transposition technique has been steadily increasing.

Conclusions

We suggest that basilic transposition technique performed in the form of RBAVF is better in terms of steal syndrome, and the patency rate of this method is similar with that reported in the literature.

References:

1. Sidawy AN, Spergel LM, Besarab A et al: The Society for Vascular Surgery: Clinical practice guidelines for the surgical placement and maintenance of arteriovenous hemodialysis access. *J Vasc Surg*, 2008; 48 (5 Suppl.): 25–25S
2. Vascular Access 2006 Work Group: Clinical practice guidelines for vascular access. *Am J Kidney Dis*, 2006; 48(Suppl.1): S176–247
3. Tordoir JH, Dammers R, van der Sande FM: Upper extremity ischemia and hemodialysis vascular access. *Eur J Vasc Endovasc Surg*, 2004; 27(1): 1–5
4. Matolo N, Kastagir B, Stevens LE et al: Neurovascular complications of brachial arteriovenous fistula. *Am J Surg*, 1971; 121(6): 716–19
5. Lazarides MK, Stamos DN, Panagopoulos GN et al: Indications for surgical treatment of angioaccess-induced arterial “steal”. *J Am Coll Surg*, 1998; 187(4): 422–26
6. Wu CC, Jiang H, Cheng J et al: The outcome of the proximal radial artery arteriovenous fistula. *J Vasc Surg*, 2015; 61(3): 802–8
7. Ehsan O, Bhattacharya D, Darwish A, Al-khaffaf H: ‘Extension technique’: A modified technique for brachio-cephalic fistula to prevent dialysis access-associated steal syndrome. *Eur J Vasc Endovasc Surg*, 2005; 29(3): 324–27
8. Capurro F1, De Mauri A, Navino C: The middle arm arteriovenous fistula is an additional option to expand autogenous hemodialysis access. *J Vasc Access*, 2012; 13(2): 208–14
9. Kakkos SK, Haddad GK, Weaver MR et al: Basilic vein transposition: what is the optimal technique? *Eur J Vasc Endovasc Surg*, 2010; 39(5): 612–19
10. Dagher F, Gelber R, Ramos E, Sadler J: The use of basilic vein and brachial artery as an A-V fistula for long term hemodialysis. *J Surg Res*, 1976; 20(4): 373–76
11. Tordoir JH1, Dammers R, de Brauw M: Video-assisted basilic vein transposition for haemodialysis vascular access: preliminary experience with a new technique. *Nephrol Dial Transplant*, 2001; 16(2): 391–94
12. Tordoir JH, Keuter X, Planken N et al: Autogenous options in secondary and tertiary access for haemodialysis. *Eur J Vasc Endovasc Surg*, 2006; 31(6): 661–66
13. Hill BB, Chan AK, Faruqi RM et al: Keyhole technique for autologous brachiobasilic transposition arteriovenous fistula. *J Vasc Surg*, 2005; 42(5): 945–50
14. Schanzer H, Schwartz M, Harrington E, Haimov M: Treatment of ischemia due to “steal” by arteriovenous fistula with distal artery ligation and revascularization. *J Vasc Surg*, 1988; 7(6): 770–73
15. Weyde W, Kusztal M, Krajewska M et al: Radial artery-perforating vein fistula for hemodialysis. *Am J Kidney Dis*, 2007; 49(6): 824–30

Declaration of conflicting interests

The authors declared no conflicts of interest with respect to the authorship and/or publication of this article.

Funding

The authors received no financial support for the research and/or authorship of this article.