

Effect of *Ginkgo biloba* on brain volume after carotid artery occlusion in rats: a stereological and histopathological study

Zeynep AKTÜRK¹, Ersan ODACI^{1*}, Ayşe İKİNCİ¹, Orhan BAŞ², Sinan CANPOLAT³,
Serdar ÇOLAKOĞLU⁴, Osman Fikret SÖNMEZ⁵

¹Department of Histology and Embryology, Faculty of Medicine, Karadeniz Technical University, Trabzon, Turkey

²Department of Anatomy, Faculty of Medicine, Ordu University, Ordu, Turkey

³Department of Physiology, Faculty of Medicine, Karadeniz Technical University, Trabzon, Turkey

⁴Department of Anatomy, Faculty of Medicine, Düzce University, Düzce, Turkey

⁵Department of Neurosurgery, Education and Research Hospital, Samsun, Turkey

Received: 05.07.2013 • Accepted: 09.08.2013 • Published Online: 27.05.2014 • Printed: 26.06.2014

Background/aim: This study investigated the effect of *Ginkgo biloba* (GB) on brain volume in cerebral ischemia induced by stopping carotid artery blood flow.

Materials and methods: Twenty-four adult male rats were divided into 4 groups of 6 rats each. No procedure was performed on the control group. Ischemia was applied to the rats in the ischemia and ischemia + GB groups by clamping the arteria carotis communis for 30 min. The rats in the ischemia + GB group were given 100 mg/kg drops (Tebokan Fort Drop, Abdi İbrahim İlaç Sanayi A.Ş., Turkey) containing dry GB leaf extract orally, every day for 14 days from the day of ischemia. In the sham group, surgical stress alone was applied by performing a skin incision. On the 14th day, brain tissues were extracted and evaluated stereologically and histopathologically.

Results: The only statistically significant difference was observed between the sham and control groups.

Conclusion: This result may be interpreted as surgical stress, established by cutaneous incision, having an adverse effect on brain volume. Additionally, the absence of any difference in terms of brain volume following 30 min of ischemia between the ischemia and control groups suggests that a probable postischemic rise in brain volume disappears within 14 days.

Key words: *Ginkgo biloba*, brain, ischemia, rat, stereology

1. Introduction

Ischemia, defined as a decrease in or complete stoppage of blood flow to a tissue for a specific duration, leads to exceedingly serious clinical pathological events and the emergence of several irreversible findings (1). Ischemia can appear for various reasons in any tissue or organ with arterial blood flow. Ischemia may develop due to mechanical or physical effects such as cuts or pressure arising in the arterial system, and structural variations gradually developing in arteries via various agents can also lead to it. Ischemia resulting from coronary artery diseases may give rise to significant consequences in the brain. Brain damage and severe neurological function defects arising in association with this are among the most important consequences of cerebral ischemia (2).

Central nervous system (CNS) tissues such as the brain, cerebellum, and medulla are known to be more sensitive to ischemia than other tissues. For example,

the brain has a high metabolic rate and low-oxygen and high-energy phosphate or carbohydrate reserves, making it more sensitive to ischemia (3). The cerebellum and some parts of the hippocampus and thalamus are also CNS tissues with considerable sensitivity to ischemia. This sensitivity also leads to serious neurological, pathological, and psychological events that directly affect human life and can result in death or reduced quality of life.

The mechanism involved in ischemic injury has largely been explained. Understanding the mechanism of ischemic injury has led to an increase in studies aimed at eliminating or reducing the likely consequences of ischemia. Another important reason for this rise is that the results obtained by establishing experimental ischemic models in animals have been shown to be applicable in clinical practice (4).

Free oxygen radicals (FORs) form as the result of excessive adenosine triphosphate (ATP) depletion in tissues with inadequate oxygenation due to ischemia or for

* Correspondence: eodaci@gmail.com

some other reason. Due to their unshared electrons, FORs are very reactive and enter into reaction with important biological structures such as cell lipids, proteins, DNA, carbohydrates, and enzymes. There is therefore convincing evidence that FORs represent the main source of tissue damage (5). A significant part of the studies on the subject have focused on reducing or preventing the formation of FORs resulting from ischemia. Studies have investigated changes in the chemical structures of existing drugs used in treatment or the development of new drugs for that purpose, while there are also studies regarding various plant essences found in nature. One of the most important of these plants is *Ginkgo biloba* (GB) (6–8).

GB originates from Asia and has long been used in the treatment of numerous diseases in that region. Also known as the Japanese plum, GB is cultivated in various regions of China (9). GB leaves and seeds are known to have been used some 5000 years ago in traditional Chinese medicine in the treatment of asthma, coughs, bronchitis, and incontinence (10). GB has proven benefits in cerebral and peripheral blood flow disorders. Thanks to the flavonoids it contains, GB extract possesses powerful free radical-binding properties and is regarded as a temporary antioxidant that can be used in the correction of ischemia-related reduced blood flow and damage caused by resulting FORs (5). However, our scan of the literature revealed insufficient studies investigating the effect of GB on ischemia-associated brain damage. This study on cerebral ischemia induced by the occlusion of arteria carotis blood flow in rats investigated the effect of GB on brain volume using stereological techniques (11–13).

2. Materials and methods

2.1. Animals and ethics

Twenty-four 16-week-old male Sprague Dawley rats, each weighing 270–300 g, were used. Animals were obtained from Karadeniz Technical University (KTU) Surgery Research Center (SRC). Rats were divided into 4 groups: Group I (control group, n = 6), Group II (ischemia group, n = 6), Group III (ischemia + GB group, n = 6), and Group IV (sham group, n = 6). The rats for each group were selected at random and monitored in separate cages throughout the study. No procedure was performed on the rats in Group I, the control group. Thirty minutes of ischemia was applied to the rats in Groups II and III. No further procedure was performed on Group II rats except for ischemia induction, and these rats were monitored for 14 days.

Animal experiments and procedures were performed in accordance with the Guide for the Care and Use of Laboratory Animals published by the US National Institutes of Health (14). The KTU Medical Faculty's Local Ethics Committee approved all animal procedures and experiments (Date: 26.10.2010; Decision No.: 3). During

the experimental procedures, rats were housed in the KTU SRC in standard plastic cages on sawdust bedding in an air-conditioned room at 22 ± 1 °C under controlled lighting (cycles of 12 h light/12 h dark). Standard rat chow and tap water were given ad libitum. The groups were kept in different cages in the same room during the experiment.

2.2. *Ginkgo biloba* treatment

Drops containing dry GB leaf extract (EGb 761, 100 mg/kg; Tebokan Fort Drop, Abdi İbrahim İlaç Sanayi A.Ş., Turkey) were administered orally to the rats in Group III, once a day at the same time for 14 days, beginning on the day of ischemia induction. A gavage needle was used for this purpose. The rats were held by the skin at the back of the neck. Extension was established by retracting the head. The gavage needle was passed between the teeth. The needle was rotated slightly to facilitate entry to the esophagus and stomach and passed over the tongue. When the pharynx was reached, the gavage needle entered the esophagus due to the swallowing reflex and the drops containing GB were deposited in the stomach. Only skin incision and suturing were performed to the neck regions of the rats in Group IV.

2.3. Ischemia procedures

At the beginning of the ischemia procedures, rats were anesthetized with urethane at 1.25 g/kg, administered intraperitoneally. They were placed on a surgical table on their backs with their heads extended and feet fixed to the table. Anterior neck regions were shaved and cleaned with İsolol antiseptic solution (polyvinylpyrrolidone iodine 10%, Merkez Lab., Turkey). A 2-cm vertical incision was made down the center of the anterior neck region. The incision was opened laterally with the help of a retractor, in such a way as not to damage the skin tissues. The right and left carotid arteries were accessed, again without damaging the tissues and vessels in the incision region. In order to clamp the internal carotid arteries effectively, the neck skin fascia in the dorsal parts was isolated from the prevertebral neck muscles (15).

In Groups II and III, blood flow was halted by clamping both arteries simultaneously using Yaşargil aneurysm clamps (BA045). Cerebral ischemia was induced by interrupting blood flow to the brain for 30 min. During this time the incision and ischemia sites were prevented from drying out by moistening the exposed surgical sites with isotonic solution. Vital findings such as respiration and heartbeat were monitored constantly. Clamps were removed after 30 min. The incision region was then sutured, with care being taken over circulation and tissue positions. In Group IV, incision alone was performed, following anesthesia, as described above. No procedure was performed on the rats in Group I. Rats were monitored for 14 days following surgery. GB was administered orally to the rats in Group III at the same time every day, between 1100 and 1200 hours (15).

2.4. Histological procedures

One rat from Group II died for an undetermined reason on the second day following ischemia, and 1 rat from Group III died due to aspiration during administration of GB. The study was thus completed with 22 rats, 6 each in Groups I and IV and 5 each in Groups II and III. On the 14th day, all rats were perfused and their brains and cerebellum were removed and separated from each other. Brain tissues were coded and numbered. Tissues were kept in formaldehyde for 10 days and then embedded in paraffin. Sections were taken and subjected to routine histopathological techniques.

2.5. Section preparation and staining

The basic principles of stereology were followed at this stage of the study. Preliminary investigation was performed and the thickness of the sections to be subjected to stereological analysis and the section sampling fraction (SSF) were determined. Section thickness was determined as 30 µm and the SSF, identified using systematic random sampling, was calculated at 1/10 (Table 1). The preliminary study results were compared with those from the literature. Our scan of the literature revealed that a sampling fraction of 1/10 and sections of 26–40 µm in thickness had been used in similar studies (15–22). The main study was thus performed on a 1/10 section sample on the basis of 30-µm-thick sections. Sections were prepared with the help of a fully automatic microtome (Leica RM 2255, Leica Instruments, Nußloch, Germany), using disposable metal microtome blades (Leica 819, Leica Instruments). At the end of the preparation procedure, 40–49 sections were obtained from each animal. Staining was performed following section preparation using 0.1% cresyl fast violet. Brain volume for each rat was calculated from the sections obtained using a stereological analysis system housed in the KTU Faculty of Medicine’s Department of Histology and Embryology Stereology Laboratory.

2.6. Stereology analysis system

The stereological analysis system housed in the KTU Faculty of Medicine’s Department of Histology and

Embryology Stereology Laboratory contains stereology analysis software and equipment manufactured by Leica. The system consists of a computer (Pentium PC, DELL OptiPlex, USA) containing stereology analysis software designed by MicroBrightField (USA), a research microscope (Leica, DM4000B-M), a CCD camera (JVC, Japan), a measuring rod measuring in the Z axis (Heidenhain LIP401 R, Germany), a microcator (Heidenhain ND 221 B), a computer-controlled motorized table capable of directing controlled movement in the X and Y axes of the microscope table (Prior ProScan, USA), a joystick (Prior, USA), and a power source.

Stereological investigations can be performed with simple equipment and materials capable of being mounted on a light microscope in many laboratories. However, because of their speed and relatively high reliability, computer-assisted stereological analysis systems and software are becoming increasingly widespread in institutions in which research is conducted using stereological techniques. The margins and area of the structure being investigated, random area sampling, and consecutive scanning of sampled areas can be easily studied in stereological analysis systems (15,21–23).

2.7. Stereological analysis details

The stereological analysis system was recalibrated every day throughout the study and thus functioned with minimal error. In order to calculate volume with the area calculation method, 1 out of each of the 10 sections previously chosen using systematic random sampling (SSF = 1/10) was examined and area calculations were performed. In brief, the following procedures were performed: first, the Stereoinvestigator program in the stereological analysis system was turned on. The section whose brain area was to be calculated was inserted into the microscope. The area was located using the microscope’s 2.5× lens and the image was focused using micro- and macroscrews. To measure the area, the right-click button on the mouse was held down over the image and the ‘Continuous Talking’ option was selected from the menu.

Table 1. Sampling strategy used for stereological analysis.

Analysis parameters	Values
Section sampling fraction (SSF)	1/10
Sampled sections from each rat brain (min–max)	40–49
Paraffin section thickness (µm)	30
Sampled section thickness for volume estimation (µm; min–max)	20.4–23.67
Objective lens for area calculation	2.5
Objective lens for thickness calculation	100

The outline of the area to be measured was then traced. Once the outline was traced, the right-click button was pressed again and the ‘Close Contour’ option was selected to measure the area thus enclosed. Area was calculated in the same way for each section. The areas of all sections were then added to give a total figure for all the sections from one rat brain.

We then measured the thickness of the sections sampled. During thickness measurement, lens magnification in both the system and the microscope was raised to 100×. The image was focused by dropping immersion oil onto it. When the image was clear, this was taken as the upper surface of the section, and the value determined by the microcator was recorded. Progression then took place from the upper surface to the lower with the help of a microscrew. When clarity of image was lost, this was regarded as the lower margin of the section and the value shown by the microcator at this level was again recorded. The difference between the 2 values was taken as section thickness. Thicknesses of the sections sampled in this way were thus determined, means were taken, and a mean thickness for the sections belonging to that individual was thus established.

Following all these procedures conducted with the Stereoinvestigator program, the following formula was used to calculate total brain volume in one rat:

$$V_{total} = \sum A_i \cdot \bar{t} \cdot 1 / SSF$$

where V_{total} represents brain volume in one individual, $\sum A_i$ the total area in the sections sampled, \bar{t} the mean thickness of the sections sampled, and SSF the section sampling fraction. SSF was determined at 1/10 (Table 1). In summary, the total section areas were multiplied by the mean section thickness to give the volume of sections sampled (Figure 1). The total brain volume was calculated by multiplying the volume determined by the sampling fraction (11–13,24).

2.8. Statistical analysis

Pre- and poststudy rat weights were analyzed using ANOVA (t-test) and Tukey’s test. Study group brain volumes and weights were compared using the Kruskal–Wallis test. Statistical analyses were performed with SPSS 13.1 (SPSS Inc., Chicago, IL, USA). Results are expressed as mean ± SEM. A P-value of less than 0.05 was considered statistically significant.

3. Results

3.1. Morphological changes in brain neurons

Histopathological analysis of rat brain neurons revealed no significant differences between neurons in Groups

$$V_{total} = V_1 + V_2 + V_3 + V_4 + V_5 + V_6$$

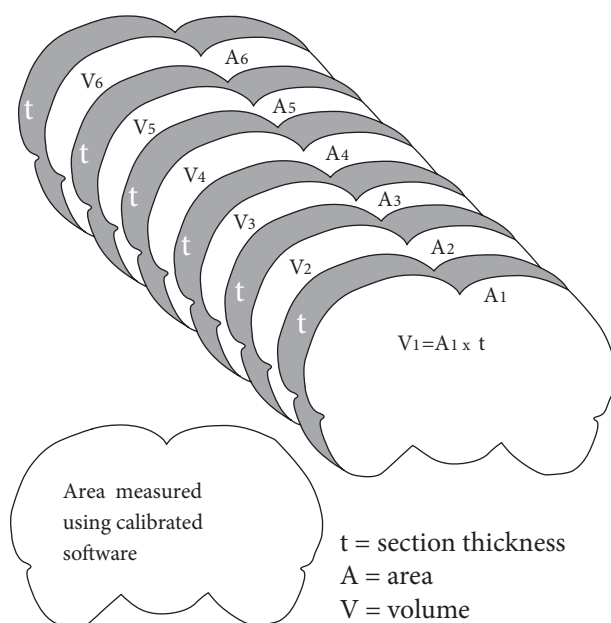


Figure 1. Volume calculation showing the application of the stereological principle. According to the stereological principle, the structure of interest is cut from end to end with a series of parallel plane sections at a constant distance. In this study, area was measured for each section using Stereoinvestigator program calibrated software. Following procedures conducted in the Stereoinvestigator program, volume was calculated using $V = A \times t$ for each section.

I (Figure 2A), II (Figure 2B), III (Figure 2C), and IV (Figure 2D). Neurons in Groups II, III, and IV were not morphologically different from those in Group I, and there were no damaged neurons (i.e. black or shrunken perikaryon) in Groups II, III, and IV in comparison with Group I.

3.2. Body and brain weight findings

Data for pre- and poststudy group weights are shown in Table 2. Prestudy ANOVA (t-test) revealed that rats used in all groups were similar, and the Tukey test revealed that there were no differences between the groups. Rats were evaluated in terms of weight at the end of the study, and no statistically significant difference was determined between the groups. Statistical analysis of rat brain weights obtained at the end of the study again revealed no significant difference among the groups ($P < 0.05$) (Table 2).

3.3. Brain volume results

Statistical analysis of rat brain volumes revealed no significant difference among Groups I, II, and III. However, a significant difference was determined between Groups I and IV ($P = 0.009$) (Table 3).

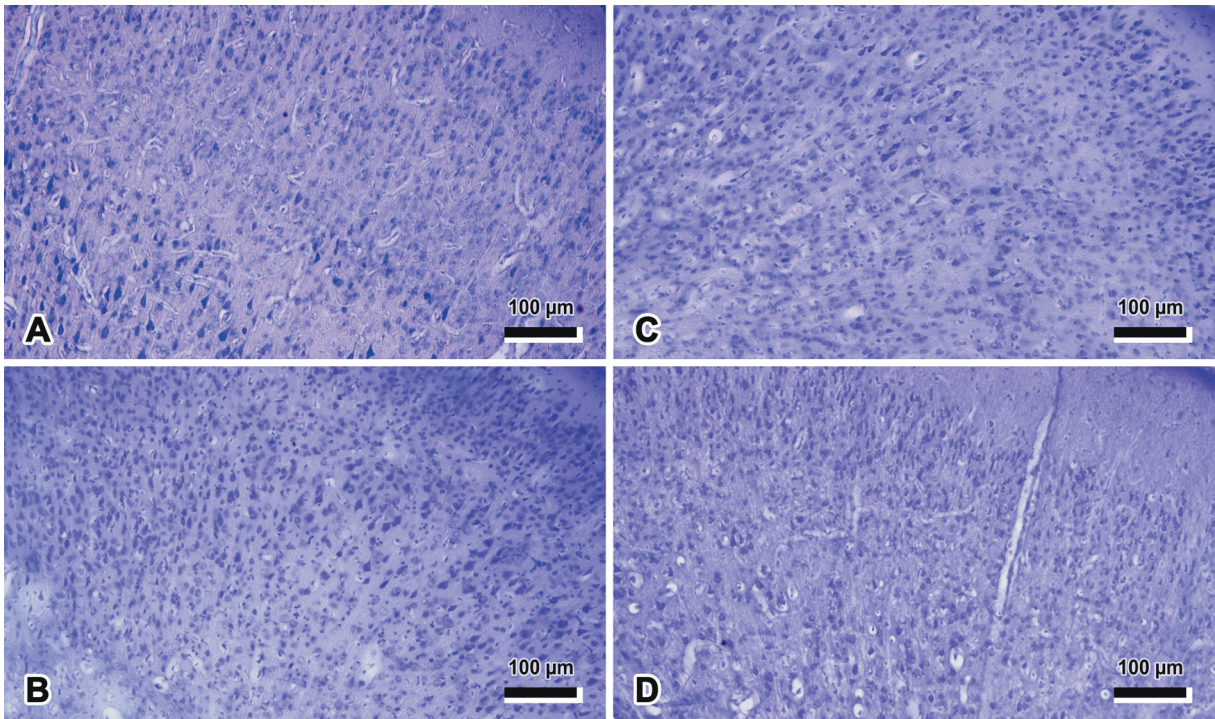


Figure 2. Representative light microscopic photomicrographs of rat brain belong to the control (A), ischemia (B), ischemia + GB (C), and sham (D) groups (stain: cresyl fast violet). There were no damaged neurons (i.e. black or shrunken perikaryon) in the ischemia and ischemia + GB groups' brain after the 30 min of bilateral carotid artery occlusion (B, C) in comparison with the control and sham groups (A, D). It should be noted that the absence of any difference between the groups at the cellular level is striking. GB: *Ginkgo biloba*.

Table 2. Comparison of groups' pre- and poststudy body and brain weights (values are given as mean ± SD).

Group	Prestudy		Poststudy		
	n	Body weight (g)	n	Body weight (g)	Brain weight (mg)
Control	6	227.00 ± 19.49	6	241.83 ± 20.10	1.43 ± 0.07
Ischemia	6	245.67 ± 36.33	5	240.33 ± 31.05	1.40 ± 0.05
Ischemia + <i>Ginkgo biloba</i>	6	236.40 ± 20.23	5	226.00 ± 21.65	1.37 ± 0.04
Sham	6	225.00 ± 38.34	6	235.67 ± 37.31	1.42 ± 0.07

4. Discussion

Cerebral ischemia is a significant cause of morbidity and mortality in both childhood and adulthood within a wide spectrum of neurological disorders. In cerebral ischemia, a series of events take place, beginning with a depletion of oxygen and energy sources such as ATP and glucose as a result of a decrease in or complete interruption of cerebral blood flow for various etiological reasons and ending in degeneration in the neurons (2). Various drugs, such as antiedema therapy, calcium channel blockers, free radical scavengers, and glutamate receptor antagonists are used in

order to prevent or eliminate injury arising after ischemia (3,25).

While the mechanisms responsible for cell loss during cerebral ischemia are not yet fully understood, much important work has been done on the subject in recent years (8,26). Histopathological studies performed with a cerebral ischemia model have determined pronounced contraction in neurons, irregularities in cell and nuclear margins, and perineural and pericapillary edema. Some of these studies reported a decrease in cerebral cortex and hippocampus neuron numbers and infarct in the area of ischemia (27,28).

Table 3. Section number used in the calculation of volume for each rat in the study groups, brain volume for each animal, and mean brain volume (MBV) value for each group.

Group	Animal no.	Section number	Volume (mm ³)	MBV (mean ± SD)
Control (n = 6)	1	41	4.57	4.60 ± 0.16
	2	47	4.49	
	3	40	4.76	
	4	41	4.36	
	5	44	4.61	
	6	46	4.80	
Ischemia (n = 5)	1	48	4.75	4.93 ± 0.30
	2	46	5.23	
	3	45	5.17	
	4	43	4.50	
	5	41	5.03	
Ischemia + <i>Ginkgo biloba</i> (n = 6)	1	44	5.14	4.94 ± 0.18
	2	44	5.01	
	3	43	4.98	
	4	45	5.03	
	5	41	4.61	
Sham (n = 6)	1	49	4.93	5.02 ± 0.20*
	2	44	5.28	
	3	46	5.11	
	4	45	4.85	
	5	41	5.20	
	6	44	4.76	

*: P = 0.009, sham group vs. control group.

A very few studies have shown that GB has a protective effect against ischemia-associated damage in neurons. Some studies on the subject have established that GB reduces cortical infarct volume in cerebral ischemia by increasing blood flow (6). Some studies have suggested that GB causes vascular dilatation by inhibiting nitric oxide and thus protecting against hypoxic injury by permitting an increase in blood flow (29,30), and that it improves brain metabolism (31). One study maintained that GB affected cerebral energy metabolism in rats exposed to low-pressure hypoxia and could prolong survival times (32). Some studies have identified an increase in brain glucose levels. Similar experimental studies have shown that GB produces a rise in blood glucose levels. The effect

of GB on the lactate/pyruvate ratio in the hypoxic rat brain has been shown to be more pronounced than its effect on lactate concentration. A significant fall in this ratio takes place thanks to a decrease in pyruvate, particularly in brains administered GB (33).

GB possesses powerful free radical-scavenging activity and antioxidant effects. One study has suggested that GB acts as a mediator on the Akt signaling pathway (34). Studies have also reported that the volume of cerebral infarct developing after focal cerebral ischemia decreased significantly with administration of GB, and that GB therapy mediated this effect by increasing antiapoptotic signals between the Akt and subsignal pathway (35–37).

Our study results showed that total sham group brain volumes increased compared to the control group, and that this increase was statistically significant. This may be interpreted as the surgical stress that we induced in the rats causing a rise in brain volume, and this increase still persisting on the 14th day. However, this result was also unexpected, and we encountered no findings in the literature to support it. Apart from this finding, no significant relationship was observed between the groups. Our examination of previous studies showed that the absence of a significant correlation between Group II and Group III or between Group III and Group IV was an expected outcome. This is because earlier studies have reported that GB has a neuroprotective effect against permanent and temporary focal cerebral ischemia (32), that it protects hippocampal neurons against cell death (38), and that it has beneficial effects on various neurodegenerative disorders and peripheral arterial obstruction diseases (34,39). This may be interpreted as GB protecting the brain against injuries that may develop in the brain as a result of ischemia or being effective in overcoming existing injury.

However, while the absence of any difference in brain volume between Group III and Group II may be interpreted as GB eliminating injury in the ischemia region by initiating neurogenesis, it may also suggest that ischemia may also have eliminated injury in the ischemia region by initiating neurogenesis. To put it another way, it may be deduced from this finding that GB may have no effect on ischemia, because ischemia is already known to trigger neurogenesis (40). We observed no significant difference between the groups in terms of rat body weights before and after the study. There was also no statistically significant difference when the groups were analyzed in terms of brain weight. This shows that neither ischemia nor GB have any effect on rats' weights.

In conclusion, it is possible that surgical stress can increase brain volume, and that GB may have a protective effect on brain volume in rats with occluded arteria carotis communis blood flow. However, this is a stereological volume study (41,42) and the results therefore need to be supported with other research at the cellular level in particular.

References

- Schmidt-Kastner R, Freund TF. Selective vulnerability of the hippocampus in brain ischemia. *Neuroscience* 1991; 40: 599–636.
- Kietzmann T, Knabe W, Schmidt-Kastner R. Hypoxia and hypoxia-inducible factor modulated gene expression in brain: involvement in neuroprotection and cell death. *Eur Arch Psychiatry Clin Neurosci* 2001; 251: 170–178.
- Lipton P. Ischemic cell death in brain neurons. *Physiol Rev* 1999; 79: 1431–1568.
- Herguido MJ, Carceller F, Roda JM, Avendaño C. Hippocampal cell loss in transient global cerebral ischemia in rats: a critical assessment. *Neuroscience* 1999; 3: 71–80.
- Uzun D. Determination of *Ginkgo biloba* effect on ovarian tissue in experimental hypoxia during pregnancy. MSc, Gazi University, Ankara, Turkey, 2010.
- MacLennan KM, Darlington CL, Smith PF. The CNS effects of *Ginkgo biloba* extracts and ginkgolide B. *Prog Neurobiol* 2002; 67: 235–257.
- Sung JH, Shah FA, Cho EH, Gim SA, Jeon SJ, Kim KM, Kim YM, Kim MO, Koh PO. *Ginkgo biloba* extract (EGB 761) prevents the ischemic brain injury-induced decrease in parvalbumin expression. *Lab Anim Res* 2012; 28: 77–82.
- Tulsulkar J, Shah ZA. *Ginkgo biloba* prevents transient global ischemia-induced delayed hippocampal neuronal death through antioxidant and anti-inflammatory mechanism. *Neurochem Int* 2013; 62: 189–197.
- Schweizer U, Bräuer AU, Köhrle J, Nitsch R, Savaskan NE. Selenium and brain function: a poorly recognized liaison. *Brain Res Brain Res Rev* 2004; 45: 164–178.
- Bensky D, Gamble A. *Chinese Herbal Medicine: Materia Medica*. Seattle, WA, USA: Eastland Press; 1993.
- von Bartheld C. Counting particles in tissue sections: choices of methods and importance of calibration to minimize biases. *Histol Histopathol* 2002; 17: 639–648.
- Gundersen HJ, Jensen EB, Kiêu K, Nielsen J. The efficiency of systematic sampling in stereology--reconsidered. *J Microsc* 1999; 193: 199–211.
- Mayhew TM, Gundersen HJ. 'If you assume, you can make an ass out of u and me': a decade of the disector for stereological counting of particles in 3D space. *J Anat* 1996; 188: 1–15.
- National Institutes of Health. *Guide for the Care and Use of Laboratory Animals*. NIH Publication No: 85–23. Washington, DC, USA: National Academies Press; 1996.
- İkinci A, Odacı E, Baş O. Effects of ethyl pyruvate administration on female rats' pyramidal cells of cornu ammonis after brain ischemia: a stereological and histopathological study. *Turk J Med Sci* 2013; 43: 354–361.
- Sonmez OF, Odacı E, Bas O, Kaplan S. Purkinje cell number decreases in the adult female rat cerebellum following exposure to 900 MHz electromagnetic field. *Brain Res* 2010; 1356: 95–101.
- Odacı E, Bas O, Kaplan S. Effects of prenatal exposure to a 900 MHz electromagnetic field on the dentate gyrus of rats: a stereological and histopathological study. *Brain Res* 2008; 1238: 224–229.
- Odacı E, Cihan OF, Aslan H, Ragbetli MC, Kaplan S. Prenatal diclofenac sodium administration increases the number of Purkinje cells in female rats: a stereological study. *Int J Dev Neurosci* 2010; 28: 145–151.

19. Bas O, Odacı E, Mollaoglu H, Uçok K, Kaplan S. Chronic prenatal exposure to the 900 megahertz electromagnetic field induces pyramidal cell loss in the hippocampus of newborn rats. *Toxicol Ind Health* 2009; 25: 377–384.
20. Bas O, Odacı E, Kaplan S, Acer N, Uçok K, Colakoglu S. 900 MHz electromagnetic field exposure affects qualitative and quantitative features of hippocampal pyramidal cells in the adult female rat. *Brain Res* 2009; 10: 178–185.
21. Kaplan S, Odacı E, Canan S, Önger ME, Aslan H, Ünal B. The disector counting technique. *NeuroQuantology* 2012; 10: 44–53.
22. Kaplan S, Canan S, Altunkaynak ME, Odacı E, Aslan H, Ünal B. An unbiased way to estimate total quantities: the fractionator technique. *NeuroQuantology* 2012; 10: 54–65.
23. Tozoğlu Ü, Keleş M, Ünal D, Uyanık A. Cytological analysis of the oral cells of chronic renal failure patients: a cytomorphometric study. *Turk J Med Sci* 2012; 42 (Sup. 2): 1443–1448.
24. Şentut T, Kırzioğlu Z, Gökçimen A, Aslan H, Erdoğan Y. Quantitative analysis of odontoblast cells in fluorotic and nonfluorotic primary tooth pulp. *Turk J Med Sci* 2012; 42: 351–357.
25. Aarts MM, Tymianski M. Molecular mechanisms underlying specificity of excitotoxic signaling in neurons. *Curr Mol Med* 2004; 4: 137–147.
26. Crack PJ, Taylor JM. Reactive oxygen species and the modulation of stroke. *Free Radic Biol Med* 2005; 38: 1433–1444.
27. Clark WM, Rinker LG, Lessov NS, Lowery SL, Cipolla MJ. Efficacy of antioxidant therapies in transient focal ischemia in mice. *Stroke* 2001; 32: 1000–1004.
28. Lee EJ, Chen HY, Wu TS, Chen TY, Ayoub IA, Maynard KI. Acute administration of *Ginkgo biloba* extract (EGb 761) affords neuroprotection against permanent and transient focal cerebral ischemia in Sprague-Dawley rats. *J Neurosci Res* 2002; 68: 636–645.
29. Chen X, Salwinski S, Lee TJ. Extracts of *Ginkgo biloba* and ginsenosides exert cerebral vasorelaxation via a nitric oxide pathway. *Clin Exp Pharmacol Physiol* 1997; 24: 958–959.
30. Kobuchi H, Droy-Lefaix MT, Christen Y, Packer L. *Ginkgo biloba* extract (EGb 761): inhibitory effect on nitric oxide production in the macrophage cell line RAW 264.7. *Biochem Pharmacol* 1997; 53: 897–903.
31. Oyama Y, Fuchs PA, Katayama N, Noda K. Myricetin and quercetin, the flavonoid constituents of *Ginkgo biloba* extract, greatly reduce oxidative metabolism in both resting and Ca(2+)-loaded brain neurons. *Brain Res* 1994; 635: 125–129.
32. Pierre S, Jamme I, Droy-Lefaix MT, Nouvelot A, Maixent JM. *Ginkgo biloba* extract (EGb 761) protects Na,K-ATPase activity during cerebral ischemia in mice. *Neuroreport* 1999; 10: 47–51.
33. Karcher L, Zagermann P, Kriegelstein J. Effect of an extract of *Ginkgo biloba* on rat brain energy metabolism in hypoxia. *Naunyn Schmiedebergs Arch Pharmacol* 1984; 327: 31–35.
34. Cho JH, Sung JH, Cho EH, Won CK, Lee HJ, Kim MO, Koh PO. *Ginkgo biloba* Extract (EGb 761) prevents ischemic brain injury by activation of the Akt signaling pathway. *Am J Chin Med* 2009; 37: 547–555.
35. Calapai G, Crupi A, Firenzuoli F, Marciano MC, Squadrito F, Inferrera G, Parisi A, Rizzo A, Crisafulli C, Fiore A et al. Neuroprotective effects of *Ginkgo biloba* extract in brain ischemia are mediated by inhibition of nitric oxide synthesis. *Life Sci* 2000; 67: 2673–2683.
36. Koltermann A, Hartkorn A, Koch E, Fürst R, Vollmar AM, Zahler S. *Ginkgo biloba* extract EGb 761 increases endothelial nitric oxide production in vitro and in vivo. *Cell Mol Life Sci* 2007; 64: 1715–1722.
37. Slemmer JE, Shacka JJ, Sweeney MI, Weber JT. Antioxidants and free radical scavengers for the treatment of stroke, traumatic brain injury and aging. *Curr Med Chem* 2008; 15: 404–414.
38. Bastianetto S, Ramassamy C, Doré S, Christen Y, Poirier J. The *Ginkgo biloba* extract (EGb 761) protects hippocampal neurons against cell death induced by beta-amyloid. *Eur J Neurosci* 2000; 12: 1882–1890.
39. DeFeudis FV, Drieu K. *Ginkgo biloba* extract (EGb 761) and CNS functions: basic studies and clinical applications. *Curr Drug Targets* 2000; 1: 25–58.
40. Altman J. Postnatal development of the cerebellar cortex in the rat. II. Phases in the maturation of Purkinje cells and of the molecular layer. *J Comp Neurol* 1972; 145: 399–463.
41. Atamanalp SS, Gündoğdu C, Ünal D, Halıcı Z, Kısaoğlu A, Özoğul B. Stereological evaluation of ganglion cells in the sigmoid colon in primary and recurrent sigmoid volvulus. *Turk J Med Sci* 2013; 43: 509–514.
42. Vurdem ÜE, Acer N, Ertekin T, Savranlar A, Topuz Ö, Keçeli M. Comparison of three volumetric techniques for estimating thyroid gland volume. *Turk J Med Sci* 2012; 42 (Sup. 1): 1299–1306.

Copyright of Turkish Journal of Medical Sciences is the property of Scientific and Technical Research Council of Turkey and its content may not be copied or emailed to multiple sites or posted to a listserv without the copyright holder's express written permission. However, users may print, download, or email articles for individual use.