

Evaluation of Estrogen, Progesterone, and GCDFP-15 Expression in Uterine Leiomyomas

Erdem Havva · Başar Feyza · Kadioğlu Nilüfer · Oktay Murat ·
Ankaralı Handan · Yavuzcan Ali · Bahadır Anzel · Dilbaz Serdar

Received: 4 July 2014 / Accepted: 16 September 2014

© Federation of Obstetric & Gynecological Societies of India 2014

About the Author



Dr. Erdem is an Associate Professor. She is currently working as a Laboratory Director at the Department of Pathology, School of Medicine, Ordu University (since August). She has also worked in the Department of Pathology, School of Medicine, Düzce University (2010–2014). She has almost 45 publications.

Abstract Approximately, one fourth of women have leiomyomas. Leiomyomas are benign tumors that originated from smooth muscle cells. Estrogen is claimed to relate as a cause but exact mechanism has not fully understood. In this study, 95 leiomyoma cases that have

been diagnosed by our department in years between 2010 and 2012 were examined. Age ranges of patients, sizes, locations, and numbers of leiomyomas were identified. Immunohistochemically ER (estrogen), PR (progesterone), and Gross cystic disease fluid protein-15 stains were performed to the paraffin blocks and their percentages of staining were noted. Statistically, submucosal and intramural locations were significantly related to ER and PR ($p < 0,001$). There were significant relationship between ER and PR in 30–50 years age group ($p < 0,001$). There were significant relationship between ER, PR and locations ($p < 0,001$), numbers ($p < 0,001$), sizes of leiomyomas (below 5 cm; $p < 0,001$), (between 5 and 10 cm; $p = 0,037$), larger than 10 cm; $p = 0,002$). Consequently, relationship between leiomyoma and ER, PR were revealed in this study. Also, relationship between leiomyoma locations and patient ages were identified statistically. There was no immunoreactivity with GCDFP-15 in leiomyomas.

Erdem H. (✉), Associate Professor · Başar F. ·
Kadioğlu N. · Oktay M.
Department of Pathology, Duzce University of Medical Faculty,
Duzce, Turkey
e-mail: drhavvaerdem@hotmail.com

Ankaralı H.
Department of Biostatistic, Duzce University of Medical Faculty,
Duzce, Turkey

Yavuzcan A. · Dilbaz S.
Department of Obstetrics and Gynecology, Düzce University of
Medical Faculty, Duzce, Turkey

Bahadır A.
Department of Biophysics, Duzce University of Medical Faculty,
Duzce, Turkey

Keywords Uterine leiomyoma · ER · PR · GCDFP-15

Introduction

Uterine leiomyomas are the most common pelvic tumors in women [1–3]. They are benign monoclonal tumors that originated from smooth muscle cells of myometrium. Incidence is 20–40 % in reproductive age group [4, 5]. In USA, the most common indication for hysterectomy is leiomyoma. There are 600,000 hysterectomy operations per year in the USA and half of them are because of leiomyoma [6]. It presents as abnormal uterine bleeding or pelvic pain in the reproductive age group. Myomas may lead to poor obstetric results such as infertility, abortus, and preterm birth. Symptoms of uterine leiomyomas can be evaluated in three categories: abnormal uterine bleeding, pelvic pressure and pelvic pain, and dysfunction of fertility. Generally they tend to be small and asymptomatic; however, they effect quality of life in majority of women and symptoms are needed to be taken care. Symptoms are related to their sizes, numbers, and localizations [6].

Majority of leiomyomas localizes in fundus and corpus. Uncommonly, they can be seen in cervix (3 %). Generally, they have receptors of PR and ER. In the first trimester of pregnancy as estrogen levels increase, myomas grow. Generally, they become symptomatic in 30–40 years age group. They can be identified clinically in 25 % of reproductive stage group. 80 % of women are diagnosed by pathologist after the surgery [7].

Gross cystic disease fluid protein-15 (GCDFP-15) is known as apocrine cell marker. However, nonapocrine tumors may be immunoreactive with GCDFP-15. 75 % of apocrine tumors and 23 % of nonapocrine tumors have immunoreactivity in breast carcinomas. Unlike ductal carcinomas, apocrine carcinomas are rarely stained by ER and PR [8, 9].

Question of whether leiomyomas show immunoreactivity or not with GCDFP-15 like ER and PR should be investigated. To our knowledge, there are not any studies about this subject in the literature.

In this study, we evaluated whether leiomyomas show immunoreactivity or not with ER, PR, and GCDFP-15, and we investigated its relationship with age of patients, sizes, and numbers of leiomyomas.

Materials and Methods

Leiomyoma cases that have been diagnosed by our pathology department were evaluated retrospectively. Leiomyoma cases that have been diagnosed from paraffin blocks of total abdominal hysterectomy specimens in years between 2010 and 2012 were reviewed, and one of the paraffin blocks were chosen and then cut in four. Blocks were stained immunohistochemically with estrogen,

progesterone, and GCDFP-15 (Fig. 1, 2, 3). Also age ranges of patients, sizes, locations, and numbers of leiomyomas were noted.

Below 20 years, age group was graded as 0, 20–30 years age group was graded as 1, 30–50 years age group was graded as 2, and older than 50 years age group was graded as 3. Submucosal location was graded as 0, intramural location was graded as 1, subserosal location was graded as 2, and parasitic location was graded as 3. Sizes below 5 cm were graded as 0, sizes between 5 and 10 cm were graded as 1, and sizes larger than 10 cm were graded as 2. Single leiomyoma was graded as 0, and multiple leiomyomas was graded as 1.

Ninety-Five cases were included in this study. There were not any cases younger than 20 years age. There were two cases in 20–30 years age group, 69 cases in 30–50 years age group, and 24 cases in older than 50 years age group. There were 22 cases in submucosal location group, 60 cases in intramural location group, 11 cases in subserosal location group, and two cases in parasitic location group. 46 cases have single leiomyoma, and 49 cases have multiple leiomyomas. Immunohistochemically staining percentages were noted. Results were evaluated statistically.

Statistical Analysis

Descriptive values that measured in the study are shown as mean, standard deviation, median, minimum, and maximum. Shapiro–Wilk test is used for evaluating if estrogen and progesterone levels are in a normal range or not. Mann–Whitney U test is used for comparing leiomyoma numbers and mean percentage of estrogen and progesterone stains. Kendall Tau coefficient is used for evaluating relationship between groups and staining percentages of



Fig. 1 ER positivity in myofibroblast nucleus (ER × 100)

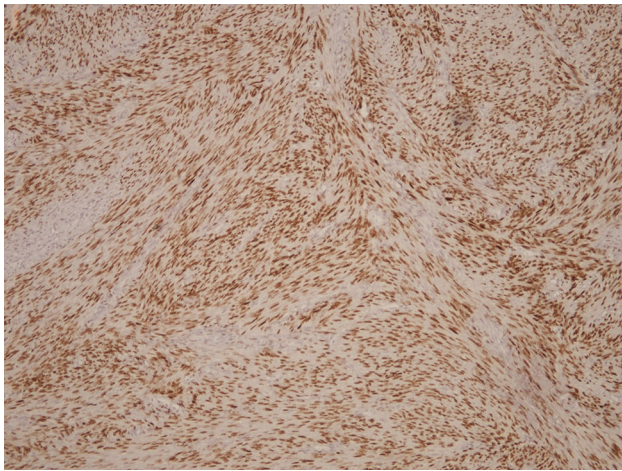


Fig. 2 PR positivity in myofibroblast nucleus (PR \times 100)

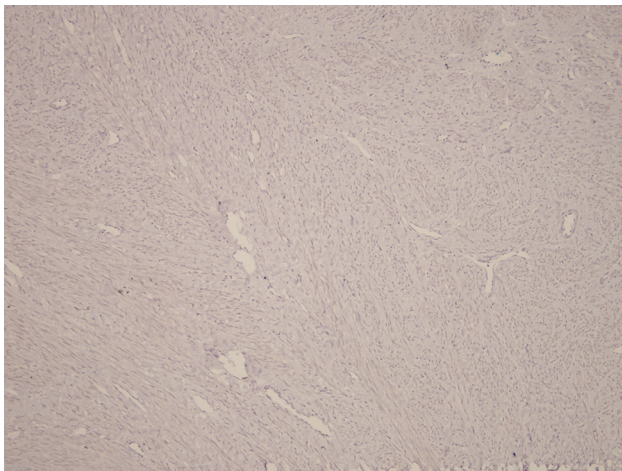


Fig. 3 Gross cystic disease protein 15 negativity in myofibroblast (GCDFP-15 \times 100)

estrogen and progesterone. $p < 0,05$ is accepted for statistical significance. PASW (ver.18) is used for calculating purposes.

Results

Table that is shown below (Table 1) demonstrates r values which were obtained by evaluating the relationship between staining percentage of estrogen, progesterone, and leiomyoma locations. p values which are used for testing significance of r value are also given.

According to Table 1, there is significant relationship between staining percentage of estrogen, progesterone and locations of leiomyoma (submucosal location) ($r = 0,652$, $p < 0,001$) and significant relationship submucosal location ($r = 0,391$, $p < 0,001$).

According to Table 2, there are significant relationship between staining percentage of estrogen, progesterone and

group 2 (30–50 years age group) ($r = 0,470$, $p < 0,001$). There are significant relationship between staining percentage of estrogen, progesterone and group 3 (older than 50 years age group) ($r = 0,370$, $p = 0,019$).

There are only two patients in group 1 (20–30 years age). Therefore, there are no significant relationship between staining percentage of estrogen, progesterone and age.

There are significant relationship between staining percentage of estrogen, progesterone, and leiomyoma number (single; $r = 0,450$; $p < 0,001$), (multiple; $r = 0,483$; $p < 0,001$).

There are significant relationship between staining percentage of estrogen, progesterone, and leiomyoma size (below 5 cm; $r = 0,517$; $p < 0,001$), (between 5 and 10 cm; $r = 0,276$; $p = 0,037$), (larger than 10 cm; $r = 0,642$; $p = 0,002$).

Discussion

Uterine leiomyomas exact cause is not fully understood yet. Several studies show its relationship with estrogen [9].

Leiomyomas may occur with long-term estrogen exposure or environmental factors [10].

In this study, mean age was 47 (29–74 years). Generally, leiomyoma is seen in 3rd or 4th decades in given literature, and this finding is similar with our study [11]. There were 69 cases (72%) who were 30–50 years old. Ashraf et al. reported that 80 % of leiomyoma cases were 31–50 years old and the youngest case was 20 years old [12]. In our study, the youngest case was 29.

Estrogen-related leiomyomas may be seen at menarche to menopause. Generally, they tend to grow slowly, and they begin to be symptomatic in the 3rd decades [11].

There was positive relationship between estrogen and progesterone ($p < 0,001$) in patient age grade 2 group (30–50 years old). There were similar results ($p = 0,019$) in patient age grade 3 group (older than 50).

Characteristically, in menopausal period, as estrogen levels decrease leiomyoma size will become smaller [13]. Hormone replacement therapy role is controversial. 74 % of women were treated with hormone replacement therapy by Palomba et al. but leiomyoma size became larger [14, 15].

Leiomyomas can be solitary either multiple in number. Multiple leiomyomas are more common. In this study, most of the leiomyomas were multiple too. Leiomyoma can be classified as submucosal, intramural, and subserosal according to localisation. In this study, 22 of them were submucosal, 69 of them were intramural, and rest of them were subserosal and parasitic. There were significant relationship between estrogen and progesterone in intramural localization group. Rarely, leiomyoma can transform to leiomyosarcoma [16].

Table 1 Progesterone

Leiomyoma localization 0	
Estrogen	
<i>r</i>	0,652
<i>p</i>	<0,0001
<i>N</i>	22
Leiomyoma localization 1	
Estrogen	
<i>r</i>	0,391
<i>p</i>	<0,0001
<i>N</i>	59
Leiomyoma localization 2	
Estrogen	
<i>r</i>	0,300
<i>p</i>	0,227
<i>N</i>	11

Table 2 Progesterone

Patient age-2	
Estrogen	
<i>r</i>	0,470
<i>p</i>	<0,0001
<i>N</i>	68
Patient age-3	
Estrogen	
<i>r</i>	0,370
<i>p</i>	0,019
<i>N</i>	24

In their study, Bükülmez and Doody showed that 27 % of women have problems with fertility and they expressed that this is related with leiomyoma localization [17]. In this study, sterility problems were not investigated.

Immunohistochemically, there were no reactivity with GCDFP-15 stain. For this reason, its relationship with ER, PR, patient age, size, and location of leiomyoma were not investigated.

Conclusion

Consequently, relationship between leiomyoma and ER, PR was revealed again in this study and relationship between localisation and patient age was measured statistically. It was pointed out that there was no immunoreactivity with GCDFP-15 in leiomyomas.

Compliance with ethical requirements and Conflict of interest All procedures followed were in accordance with the ethical

standards of the responsible committee. An ethical clearance has also been taken from the ethical committee (düzce university school of medicine, ethics committee of noninvasive clinical researchers approval for application (decision number:2013/381)).

The authors of the article Havva Erdem, Feyza Baþar, Nilüfer Kadýođlu, Murat Oktay, Handan Ankaralý, Ali Yavuzcan, Anzel Bahadýr, Serdar Dilbaz declare that they have no conflict of interest.

References

- Baird DD, Dunson DB, Hill MC, et al. High cumulative incidence of uterine leiomyoma in black and white women: ultrasound evidence. *Am J Obstet Gynecol.* 2003;188(1):100–7.
- Zheng LH, Cai FF, Ge I, et al. Stromal fibroblast activation and their potential association with uterine fibroids (Review). *Oncol Lett.* 2014;8(2):479–86.
- Serden SP, Brooks PG. Treatment of abnormal uterine bleeding with the gynecologic resectoscope. *J Reprod Med.* 1991;36(10):697–9.
- Khan AT, Shehmar M, Gupta JK. Uterine fibroids: current perspectives. *Int J Womens Health.* 2014;29(6):95–114.
- Marshall LM, Spiegelman D, Barbieri RL, et al. Variation in the incidence of uterine leiomyoma among premenopausal women by age and race. *Obstet Gynecol.* 1997;90(6):967–73.
- Kaban I, Cengiz H, Ekin M, et al. Uterin leiomyom ön tamısı ile opere edilen olgularda preoperatif tanının postoperatif histopatolojiyi kestirmedeki değeri. *Göztepe Tıp Derg.* 2013;28(1):19–24.
- Ibrar F, Riaz S, Dawood NS, et al. Frequency of fibroid uterus in multipara women in a tertiary care centre in Rawalpindi. *J Ayub Med Coll Abbottabad.* 2010;22(3):155–7.
- Tavassoli FA, Purcell CA, Bratthauer GL, et al. Androgen receptor expression along with loss of bcl-2, ER, and PR expression in benign and malignant apocrine lesions of the breast: implications for therapy. *Breast J.* 1996;2:261–9.
- Leal C, Henrique R, Monteiro P, et al. Page DL Apocrine ductal carcinoma in situ of the breast: histologic classification and expression of biologic markers. *Hum Pathol.* 2001;32(5):487–93.
- Maruo T, Ohara N, Wang J, et al. Sex steroidal regulation of uterine leiomyoma growth and apoptosis. *Hum Reprod Update.* 2004;10(3):207–20.
- Lefebure G, Vilos G, Allaire C, et al. The management of uterine leiomyoma. Clinical practice gynaecological committee. *Obstet Gynecol Can.* 2003;25:396–418.
- Ashraf T. Management of uterine leiomyomas. *J Coll Physicians Surg Pak.* 1997;7:160–2.
- Flake GP, Andersen J, Dixon D. Etiology and pathogenesis of uterine leiomyomas: a review. *Environ Health Perspect.* 2003;111(8):1037–54.
- Palomba S, Sammartino A, Di Carlo C, et al. Effects of raloxifene treatment on uterine leiomyomas in postmenopausal women. *Fertil Steril.* 2001;76(1):38–43.
- Polatti F, Viazzo F, Colleoni R, et al. Uterine myoma in postmenopause: a comparison between two therapeutic schedules of HRT. *Maturitas.* 2000;37(1):27–32.
- Bharambe BM, Deshpande KA, Surase SG, et al. Malignant transformation of leiomyoma of uterus to leiomyosarcoma with metastasis to ovary. *J Obstet Gynaecol India.* 2014;64(1):68–9.
- Bukulmez O, Doody KJ. Clinical features of myomas. *Obstet Gynecol Clin North Am.* 2006;33(1):69–84.